

---

# Does Laser Inactivate Botulinum Toxin?

NATALIE L. SEMCHYSHYN, MD, AND SUZANNE L. KILMER, MD

*Laser and Skin Surgery Center of Northern California, Sacramento, California*

---

**BACKGROUND.** Botulinum toxin is a popular and effective treatment for dynamic rhytids. It is a neurotoxic protein complex that exerts its effect by inhibiting acetylcholine release at the presynaptic neuromuscular junction. Nonablative resurfacing treatments have also become well liked by patients and physicians owing to the minimal downtime associated with treatment. Currently, same-day nonablative laser treatments are performed prior to botulinum toxin injection owing to the concern that the laser may inactivate it. On occasion, it may be desirable to perform nonablative laser after the botulinum toxin has been injected (ie, patient afterthought, scheduling concern).

**OBJECTIVE.** To determine whether the use of nonablative rejuvenation laser or intense pulsed light (IPL) immediately following botulinum toxin injections has any effect on the efficacy of the botulinum toxin treatment.

**METHODS.** Nineteen subjects received botulinum toxin injections to either the glabellar or crow's-feet areas. One side of the treated glabellar or periorbital area was treated with either VBeam laser (Candela, Wayland, MA, USA), SmoothBeam laser (Candela), CoolGlide laser (Cutera, Brisbane, CA, USA), or an IPL or radiofrequency (RF) device within 10 minutes of botulinum toxin injection. Pretreatment and 2-week post-treatment photographs were compared.

**RESULTS.** No decrease in the efficacy of botulinum toxin denervation was observed when glabellar or periorbital areas were treated with VBeam laser, SmoothBeam laser, CoolGlide laser, or an IPL or RF device within 10 minutes of botulinum toxin injection.

**CONCLUSION.** Patients may be treated with several nonablative lasers and IPL or RF devices immediately after botulinum toxin injection without loss of efficacy or other apparent untoward effect.

---

*ALLERGAN PROVIDED BOTULINUM TOXIN, AND THERMAGE PROVIDED RADIOFREQUENCY TIPS.*

---

BOTULINUM TOXIN type A is a popular and well-documented effective therapy for treating hyperdynamic facial rhytids.<sup>1,2</sup> Its minimal invasiveness, lack of downtime, and low risk of serious complications make it an attractive treatment option for both patients and physicians. Botulinum toxin is a neurotoxic protein complex that exerts its effect by inhibiting acetylcholine release at the presynaptic neuromuscular junction. The active molecule is composed of both heavy and light chains that are linked by heat-labile disulfide bonds and noncovalent forces.<sup>3</sup> Although the light chain itself is the active component of the toxin and is able to effect chemoparalysis,<sup>4</sup> the heavy chain is required for entry into the target cell.<sup>5,6</sup>

Nonablative resurfacing has also become very popular in the last few years owing to a lack of post-treatment downtime and minimal aftercare. Various nonablative treatments exist and have been shown to improve the appearance of wrinkles, acne scars, and skin texture. Pigmentary and vascular changes may also be treated, depending on the device used. The sources used for this purpose include lasers (data on file, Cutera Inc., Brisbane,

CA, USA),<sup>7,8</sup> intense pulsed light (IPL) sources,<sup>9</sup> and radiofrequency (RF) devices (data on file, Thermage, Hayward, CA, USA). These treatment modalities exert their nonablative rejuvenation effects via heat deposition in the dermis. The targeted chromophores include dermal vasculature (pulsed dye laser, IPL) and water (SmoothBeam, Candela, Wayland, MA, USA; CoolGlide, Cutera). The ThermoCool TC (Thermage) device uses RF to deliver heat to the dermis to promote tissue tightening. To target the heat-sensitive intramolecular bonds in collagen, this modality heats the dermis to approximately 60°C and can penetrate a depth of 4 to 5 mm.<sup>10</sup>

A recent prospective, randomized study showed a synergistic effect on facial rejuvenation when botulinum toxin injections were combined with broad-based light treatment.<sup>11</sup> It has always been our practice to perform botulinum toxin injections after nonablative laser treatment owing to concerns of altering the effect of the botulinum toxin. Although botulinum toxin is known to be inactivated in contaminated food by heating to 85°C for 5 minutes, the effect of heat on the toxin in tissue is unclear.

Because of the concern of denaturing and inactivating the botulinum toxin, the manufacturer has made numerous recommendations for handling and storage of the product (Botox product insert, Allergan, Irvine, CA, USA). Many of these are theoretical considerations, and several

---

Address correspondence and reprint requests to: Natalie L. Semchyshyn, MD, 3835 J Street, Sacramento, CA 95816, or e-mail: nsemchyshyn@skinlasers.com.

have been subsequently disproved.<sup>12-14</sup> We questioned whether botulinum toxin would “survive” after immediate treatment with nonablative rejuvenation devices.

## Methods

Nineteen female volunteers, ranging in age from 19 to 71 years, participated in the study. Informed consent and pre-procedure photographs were obtained in all cases. Areas treated include glabellar frown lines, periorbital crow's-feet, and horizontal forehead lines.

One side of the face was injected with botulinum toxin. Both sides were immediately (mean 4.8 minutes, range 1–10 minutes) treated with a nonablative rejuvenation device. Botulinum toxin was then injected into the opposite side to serve as a control. Five subjects were treated with VBeam (Candela), three with SmoothBeam, two with Quantum IPL (Lumenis, Palo Alto, CA, USA), two with CoolGlide, and seven with ThermoCool TC. The treatment parameters for each device were those typically used in our practice for nonablative rejuvenation (Table 1). The subjects were evaluated at 2 to 3 weeks post-treatment, photographs were taken, and asymmetry was assessed.

## Materials and Laser Parameters

### Botulinum Toxin

The botulinum toxin was diluted with 2.0 mL preserved normal saline for each 100 U vial. The patients were treated in a sitting position. The areas to be treated were

cleansed with alcohol. Botulinum toxin was injected intramuscularly using 30-gauge, 1/2-inch needles on a 1 cc syringe. The number of units and number and location of injections were determined on an individual basis and were performed symmetrically on both sides of the face; 25 to 50 units were used for each patient. An ice pack was used to provide anesthesia prior to injection.

### Laser Parameters

CoolGlide treatment was performed with a 3 mm spot size set at 15 J, 100 microseconds, 5 Hz. The handpiece was moved back and forth over the treatment area in a “painting” fashion, repeated to the point of patient intolerance.

Quantum IPL settings were based on subject skin type: both subjects had Fitzpatrick skin type II and were, therefore, treated with a cutoff filter of 560 nm, double-pulsed with 2.4 milliseconds and 4.0 milliseconds with a 15-millisecond delay between pulses; contact gel was used.

SmoothBeam treatment was performed with one pass using a 6 mm spot size, 13 J, and cooling set at 40 milliseconds.

ThermoCool TC settings were based on subject pain ratings during treatment; two or three passes were performed in each treatment area. One subject was treated with the regular tip; the maximum setting was 14.5. Six subjects were treated with the fast tip, reaching maximum settings of 75.5, 73.5, 73.0, 74.0, 73.5, and 74.0, as noted in Table 1.

VBeam 595 nm laser treatment included one pass across the treatment area with a 10 mm spot size, 7.5 J,

**Table 1.** Results

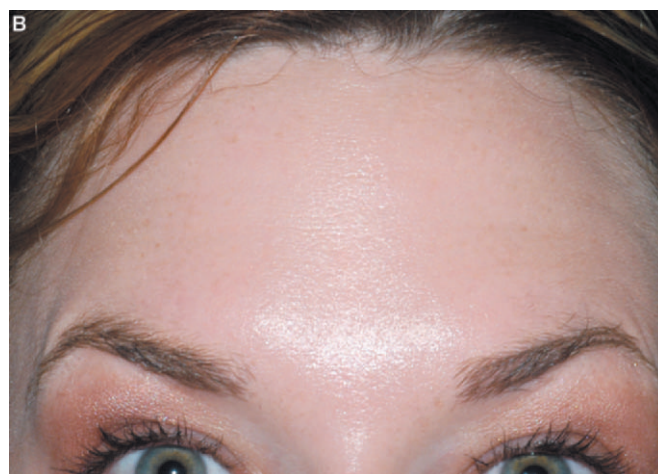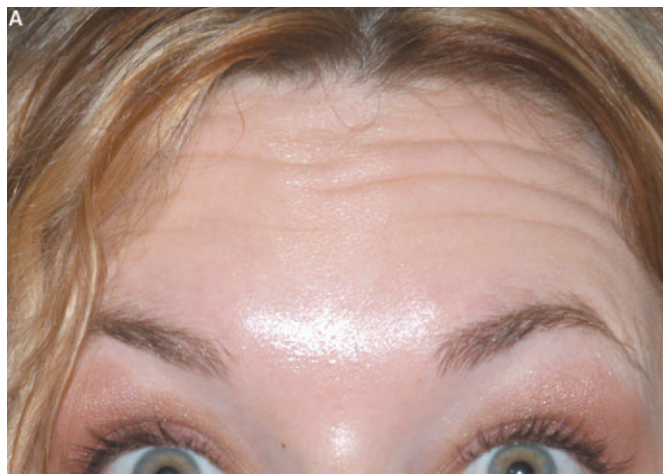Laser	Treatment Area	Time Lapse, min	Laser Setting	Side Lasered after Treatment	Result
CG	Periorbital	3	3 mm/100 μs/15 J	Left	No asymmetry
CG	Glabella	8	3 mm/100 μs/15 J	Left	No asymmetry
IPL	Glabella	4	Prog 1/25 J	Right	No asymmetry
IPL	Glabella, periorbital	9	Prog 1/25 J	Right	No asymmetry
SB	Periorbital	2	6 mm/13 J/40 DCD	Right	No asymmetry
SB	Periorbital	4	6 mm/13 J/40 DCD	Left	No asymmetry
SB	Forehead	6	6 mm/13 J/40 DCD	Left	No asymmetry
TC	Glabella	7	74.0 maximum	Left	No asymmetry
TC	Glabella	5	14.5 maximum	Left	No asymmetry
TC	Forehead	5	75.5 maximum	Right	No asymmetry
TC	Forehead	10	73.5 maximum	Left	No asymmetry
TC	Glabella, periorbital	5	73.0 maximum	Right	No asymmetry
TC	Glabella, forehead	5	74.0 maximum	Right	No asymmetry
TC	Glabella	7	73.5 maximum	Right	No asymmetry
VB	Glabella, periorbital	4	10 mm/7.5 J/6 ms/30 DCD	Left	No asymmetry
VB	Periorbital	1	10 mm/7.5 J/6 ms/30 DCD	Right	No asymmetry
VB	Periorbital	1	10 mm/7.5 J/6 ms/30 DCD	Left	No asymmetry
VB	Glabella, periorbital	1	10 mm/7.5 J/6 ms/30 DCD	Right	No asymmetry
VB	Glabella	5	10 mm/7.5 J/6 ms/30 DCD	Right	No asymmetry

CG = CoolGlide 1,064 nm; DCD = dynamic cooling device; IPL = Quantum intense pulsed light; SB = SmoothBeam 1,450 nm; TC = ThermoCool; VB = VBeam 595 nm.

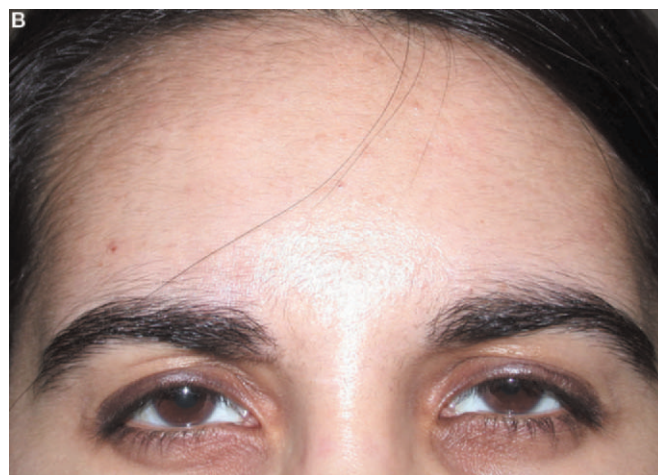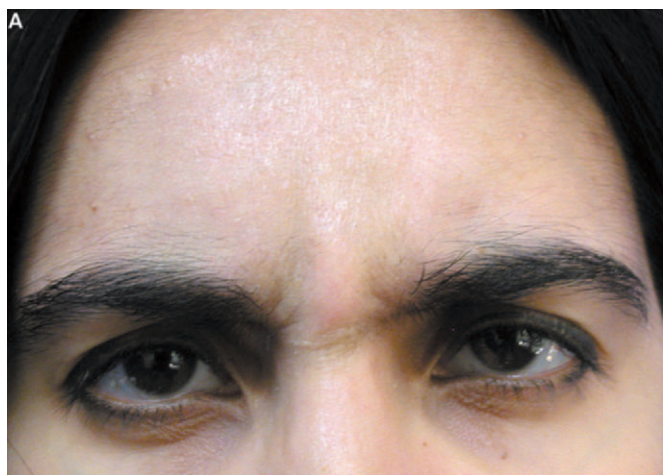6 milliseconds, 30-millisecond cooling with a 30-millisecond delay for the dynamic cooling device.

## Results

All 19 subjects exhibited symmetric chemodenervation in the treatment areas (see Table 1 and Figures 1 to 8).



**Figure 1.** (A) Forehead lines, pretreatment; (B) forehead right, side treated with ThermoCool (fast tip) 5 minutes after botulinum toxin injection.



**Figure 2.** (A) Glabellar lines, pretreatment; (B) glabellar lines, left side treated with CoolGlide 8 minutes after botulinum toxin injection.

## Conclusions

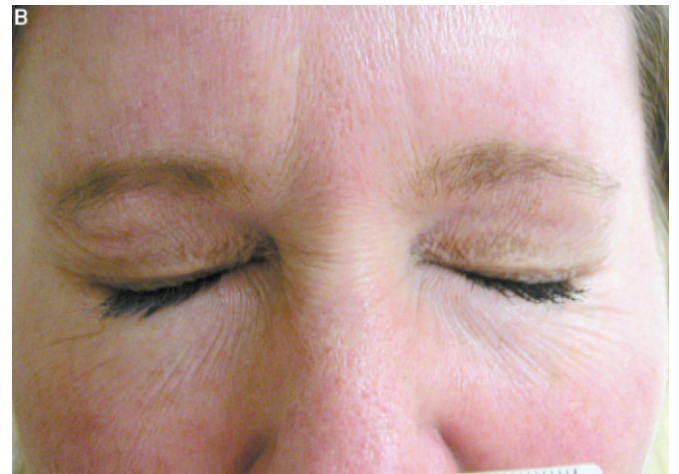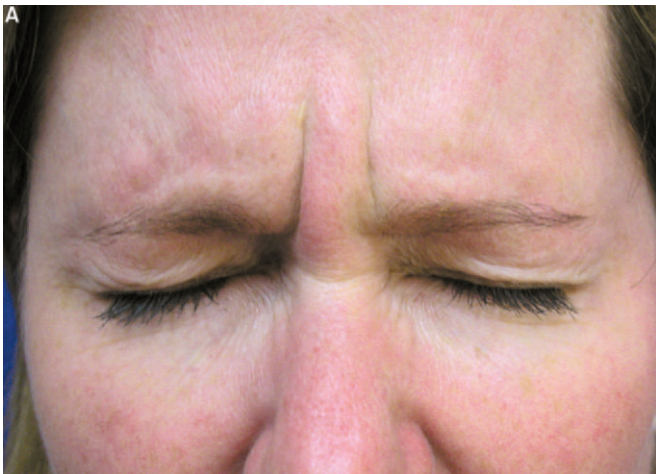No loss of botulinum toxin efficacy after immediate treatment with nonablative rejuvenation devices was noted in this study. This is somewhat surprising because one may expect the dermal deposition of heat involved in nonablative treatment to thermally or mechanically disrupt and, consequently, inactivate the botulinum toxin molecule. The thermal denaturation of protein is dependent on the summation of energy as a function of time. Current recommendations for inactivating botulinum toxin in food include heating at 85°C for 5 minutes. We were especially

concerned about ThermoCool (TC) treatment because the treatment goal involves denaturation of intramolecular collagen bonds to effect tissue tightening; this tissue heating can be quite deep, penetrating 4 to 5 mm in skin. Collagen denaturation is known to occur at approximately 52 to 60°C. Although in vivo temperature measurements have not yet been performed, it is estimated that the Thermo-

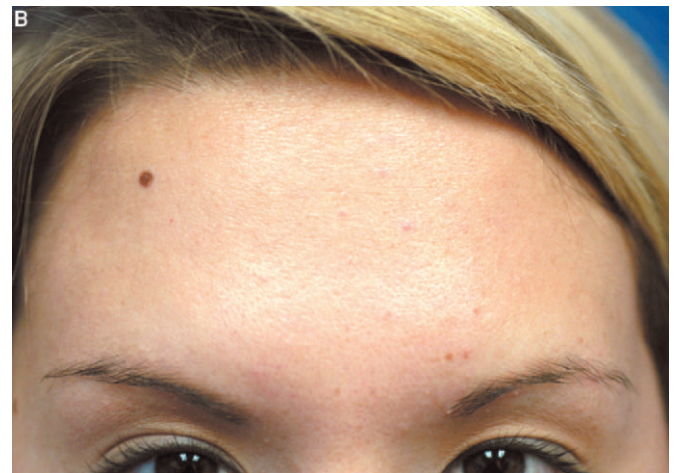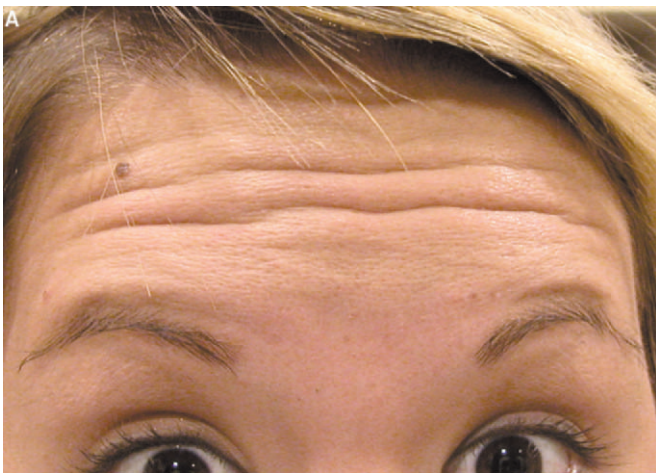Cool 1 cm<sup>2</sup> tip heats tissue to between 50 and 65°C (K. Pope, personal communication, 2004). From our results, it appears that botulinum toxin is thermally stable at the temperatures attained (in the skin) with the various nonablative devices used in this study.

Another concern was that laser, IPL, or RF might cause unwanted movement or diffusion of the botulinum toxin. However, none of the subjects reported adverse effects, such as paralysis or weakening of unintended muscles.

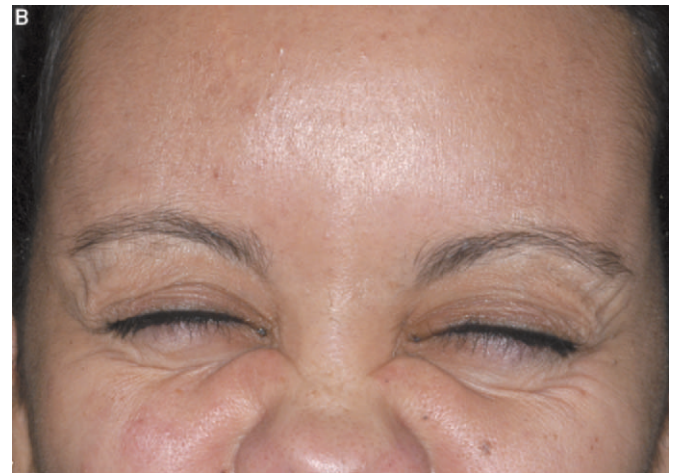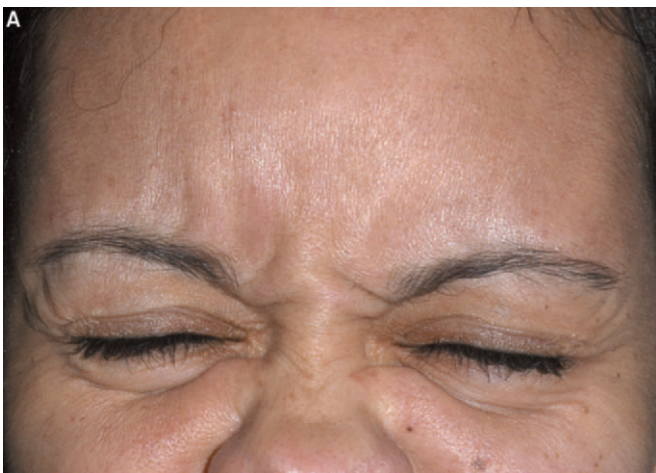Interestingly, several subjects commented that they thought the onset of paralysis in the “lasered botulinum toxin” side became apparent a few days earlier than in the



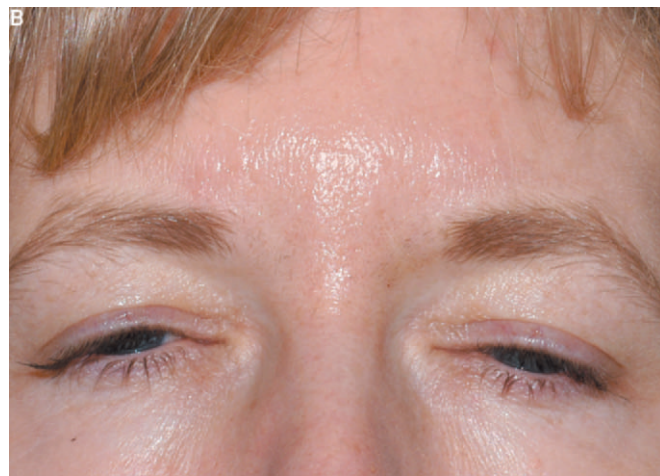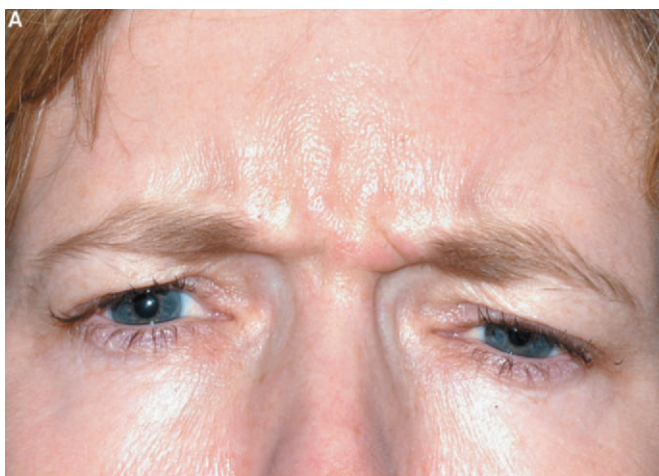**Figure 3.** (A) Glabellar line, pretreatment; (B) glabellar lines, right side treated with intense pulsed light 4 minutes after botulinum toxin injection.



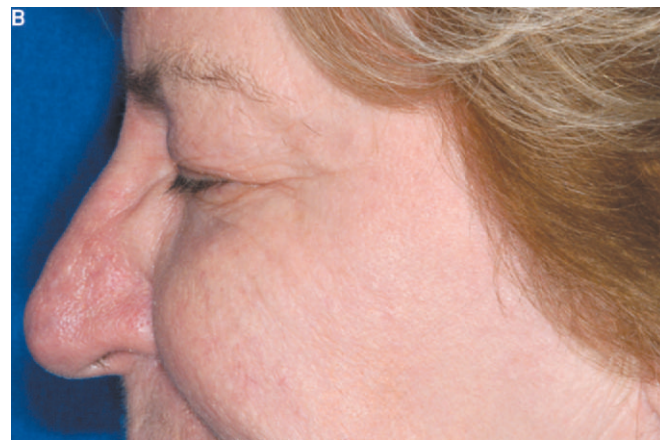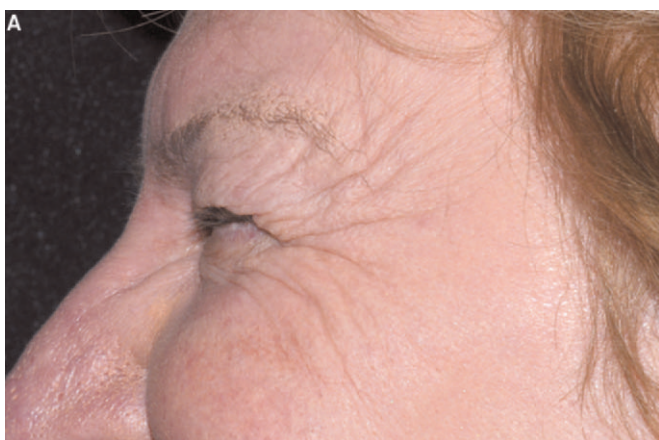**Figure 4.** (A) Forehead lines, pretreatment; (B) forehead lines, right side treated with ThermaCool (fast tip) 5 minutes after botulinum toxin injection.



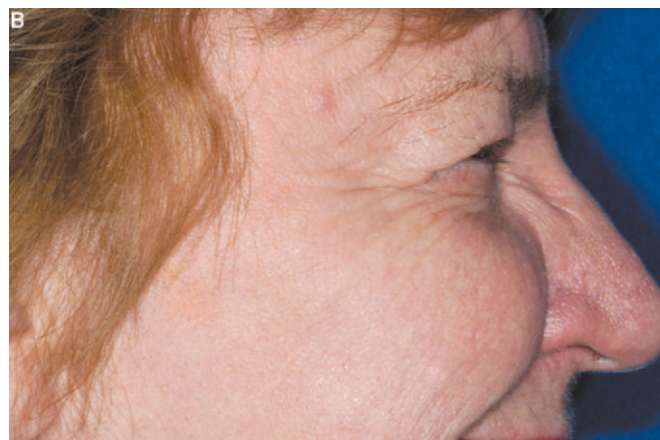
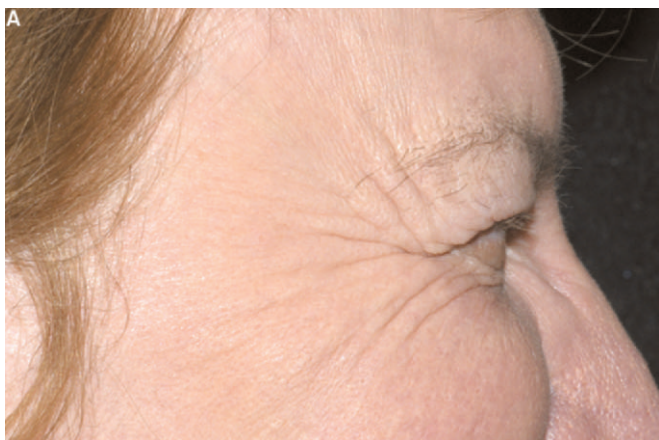
**Figure 5.** (A) Glabellar lines, pretreatment; (B) glabellar lines, right side treated with ThermaCool (fast tip) 7 minutes after botulinum toxin injection.



**Figure 6.** (A) Glabellar lines, pretreatment; (B) glabellar lines, left side treated with ThermaCool 5 minutes after botulinum toxin injection.



**Figure 7.** (A) Periorbital lines, left side, pretreatment; (B) periorbital lines, left side treated with V-Beam 4 minutes after botulinum injection.



**Figure 8.** (A) Periorbital lines, right side, pretreatment; (B) periorbital lines, right side after treatment with V-Beam (controlled).

control side. It is unclear as to why this should happen. Owing to the comments about the lasered botulinum toxin side kicking in sooner, we became concerned about the duration of the botulinum toxin effect. Although a formal evaluation was not performed, all subjects were contacted at 2 months postprocedure and all responded that the sym-

metry and effect of paralysis were maintained at this time. Eighteen of 19 subjects maintained the effect for over 3 months. Most subjects had been treated with botulinum toxin injections in the past and noted that the duration of chemodenervation during this study was comparable to that experienced with prior injections. One subject noted

symmetric return of muscle contraction at 2 months, 2 weeks; this subject was botulinum toxin naive and, we suspect, had been underdosed. No subjects reported noticing that one side wore off faster than the other.

This small study has demonstrated that nonablative rejuvenation treatment with various laser, IPL, or RF devices immediately following botulinum toxin injection does not adversely impact efficacy at 2 to 3 weeks post-procedure. It is also unlikely to affect the duration of botulinum toxin response, although this aspect needs to be addressed in further studies.

## References

1. Carruthers A, Carruthers J. Botulinum toxin type A: history and current cosmetic use in the upper face. *Semin Cutan Med Surg* 2001;20:71–84.
2. Carruthers J, Carruthers A. Botox use in the mid and lower face and neck. *Semin Cutan Med Surg* 2001;20:85–92.
3. Huang W, Foster JA, Rogachefsky AS. Pharmacology of botulinum toxin. *J Am Acad Dermatol* 2000;43:249–59.
4. Ahmed SA, Smith LA. Light chain of botulinum A neurotoxin expressed as an inclusion body from a synthetic gene is catalytically and functionally active. *J Protein Chem* 2000;19:475–87.
5. Bandyopadhyay S, Clark AW, DesGupta BR, Sathyamoorthy V. Role of the heavy and light chains of botulinum neurotoxin in neuromuscular paralysis. *J Biol Chem* 1987;262:2660–3.
6. Simpson LL, Maksymowych AB, Park JB, Bora RS. The role of the interchain disulfide bond in governing the pharmacological actions of botulinum toxin. *J Pharmacol Exp Ther* 2004;308:857–64.
7. Rostan E, Bowes LE, Iyer S, Fitzpatrick RE. A double-blind, side-by-side comparison study of low fluence long pulse dye laser to coolant treatment for wrinkling of the cheeks. *J Cosmet Laser Ther* 2001;3:129–36.
8. Goldberg DJ, Rogachefsky AS, Silapunt S. Non-ablative laser treatment of facial rhytides: a comparison of 1450-nm diode laser treatment with dynamic cooling as opposed to treatment with dynamic cooling alone. *Lasers Surg Med* 2002;30:79–81.
9. Goldberg DJ, Cutler KB. Nonablative treatment of rhytids with intense pulsed light. *Lasers Surg Med* 2000;26:196–200.
10. Zelickson BD, Kist D, Bernstein E, et al. Histological and ultrastructural evaluation of the effects of a radiofrequency-based nonablative dermal remodeling device: a pilot study. *Arch Dermatol* 2004;140:204–9.
11. Carruthers J, Carruthers A. The effect of full-face broadband light treatments alone and in combination with bilateral crow's feet botulinum toxin type A chemodenervation. *Dermatol Surg* 2004;30:355–66.
12. Sloop RR, Cole BA, Escutin RO. Reconstituted botulinum toxin type A does not lose potency in humans if it is refrozen or refrigerated for 2 weeks before use. *Neurology* 1997;48:249–53.
13. Trindade De Almeida AR, Kadunc BV, et al. Foam during reconstitution does not affect the potency of botulinum toxin type A. *Dermatol Surg* 2003;29:530–1; discussion 532.
14. Alam M, Dover JS, Arndt KA. Pain associated with injection of botulinum A exotoxin reconstituted using isotonic sodium chloride with and without preservative: a double-blind, randomized controlled trial. *Arch Dermatol* 2002;138:510–4.