Case Report

A 3D navigation-guided surgical resection of a rare case of sacral spine mesenchymal chondrosarcoma: a case report

Abdulaziz Saber[1,2,3], Mohammed Khashab[1,2,3], Abdulhadi Turkistani[1,2,3], Moyassar Karami[1,2,3], Saleh Almaymoni[1,2,3], Mohamed Elkhalifa[1,2,3], Abdulhadi Algahtani[2,3,4], Abdullah Alhazmi[1,2,3]

[1]Department of Surgery, Orthopaedic Division, Ministry of National Guard-Health Affairs, Jeddah, Saudi Arabia; [2]King Abdullah International Medical Research Center, Jeddah, Saudi Arabia; [3]College of Medicine, King Saud Bin Abdulaziz University for Health Sciences, Jeddah, Saudi Arabia; [4]Department of Surgery, Neurosurgery Division, Ministry of National Guard-Health Affairs, Jeddah, Saudi Arabia

Contributions: (I) Conception and design: M Khashab, M Karami; (II) Administrative support: All authors; (III) Provision of study materials or patients: M Khashab, A Alhazmi, A Algahtani, M Elkhalifa; (IV) Collection and assembly of data: A Saber, A Turkistani, S Almaymoni, M Karami; (V) Data analysis and interpretation: M Karami, A Saber, A Turkistani; (VI) Manuscript writing: All authors; (VII) Final approval of manuscript: All authors.

Correspondence to: Abdulaziz Saber, BSc, MBBS. Department of Surgery, Orthopaedic Division, Ministry of National Guard-Health Affairs, King Abdulaziz Medical City, Makkah – Jeddah highway, Jeddah 22384, Saudi Arabia; King Abdullah International Medical Research Center, Jeddah, Saudi Arabia; College of Medicine, King Saud Bin Abdulaziz University for Health Sciences, Jeddah, Saudi Arabia. Email: abdulazizsaber9@gmail.com.

Background: Chondrosarcomas are a group of heterogeneous malignant cartilaginous neoplasms that arise from preexisting benign precursors. They can be divided into conventional (primary) chondrosarcomas, which account for 90% of cases, and nonconventional chondrosarcomas, which account for the remaining 10%. Mesenchymal chondrosarcoma (MCS) is a rare high-grade soft tissue tumor variant of nonconventional chondrosarcoma that is histologically characterized by a biphasic pattern of atypical cartilage with small round cells.

Case Description: A 23-year-old female known case of ovarian cyst presented with a two-year history of low back pain and constitutional symptoms. Pelvic magnetic resonance imaging (MRI) with contrast showed a well-defined lesion with intermediate to high signals located at the right wing of the upper sacrum, at the level of S1–S2. The patient underwent a combined ultrasound and computed tomography-guided biopsy under local anesthesia and the immunochemical profile was positive for CD99 and S100 biomarkers. The patient underwent a two-stage procedure for a wide marginal tumor resection. Stage 1 was performed with an anterior approach; identification of the tumor margins was done followed by designing the cuts of the sacrum to achieve wide margins around the tumor. Stage 2 was performed with a posterior approach exposing L3 vertebrae down to the sacrum. Utilizing O-Arm Navigation for posterior margin allocation in addition to instrumentation. After 12 months post-operation, follow up revealed no evidence of recurrence.

Conclusions: Limitation in accessibility to the axial skeleton and the neurovascular component, poses a challenge to treatment. Therefore, using neuro-navigation system and optimal adjuvant therapy should be studied further to improve the prognosis.

Keywords: Mesenchymal chondrosarcoma (MCS); 3D neuro-navigation; spine; surgical resection; case report

Submitted Aug 16, 2024. Accepted for publication Dec 09, 2024. Published online Mar 11, 2025.
doi: 10.21037/jss-24-104
View this article at: https://dx.doi.org/10.21037/jss-24-104

Introduction

Chondrosarcomas are a group of heterogeneous malignant cartilaginous neoplasms that arise from preexisting benign precursors (1). They can be divided into conventional (primary) chondrosarcomas, which account for 90% of cases, and nonconventional chondrosarcomas, which account for the remaining 10%. The conventional chondrosarcomas include central, peripheral, and periosteal

© AME Publishing Company.

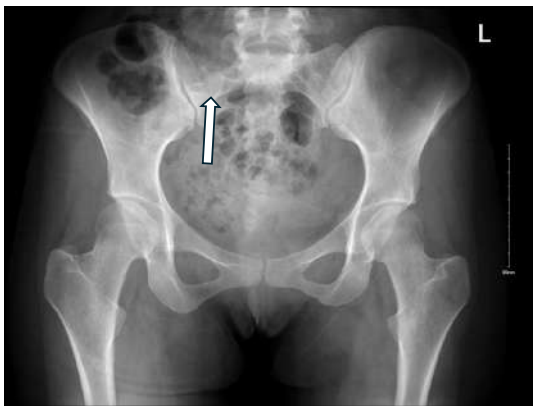

Figure 1 A plain pelvic X-ray anteroposterior view showing heterogeneity of the right sacral ala bone (arrow) with lytic and destructive changes.

subtypes, while the nonconventional types include clear cell chondrosarcomas, mesenchymal chondrosarcomas (MCSs), and dedifferentiated chondrosarcomas (1).

MCS is a rare high-grade soft tissue tumor variant of nonconventional chondrosarcoma that is histologically characterized by a biphasic pattern of atypical cartilage with small round cells (2). MCS typically presents more frequently in females than in males (2). However, fewer than 500 cases have been reported in the literature (2). By contrast, conventional chondrosarcomas commonly involve the craniofacial, vertebral, rib, and ilium bones, with roughly 20% of cases presenting with metastasis during diagnosis (2). One study found a 5-year mortality rate of 54% for intracranial MCS, whereas intracranial conventional chondrosarcoma had a 5-year mortality rate of only 6% (3). Hence, based on the location and type, chondrosarcoma treatment and prognosis may differ.

The small number of reported MCS patients also means this disease remains poorly understood (2). The mainstay treatment is tumor resection with wide safety margins (2). However, anatomical constraints, particularly in the axial regions, may create challenges that make surgical resection unfeasible (2). Moreover, effective systemic therapies for MCS, such as chemotherapy and radiation adjuvants, remain scarce (4). We present this article in accordance with the CARE reporting checklist (available at https://jss.amegroups.com/article/view/10.21037/jss-24-104/rc).

Highlight box

Key findings

- In our case, a 23-year-old female was diagnosed with mesenchymal chondrosarcoma (MCS) of the sacral spine. A two-stage procedure was performed to achieve a wide marginal tumor resection. A 3-dimensional (3D) navigation system was utilized for both identifying tumor margins and application of instrumentation. We achieved tumor-free margins successfully. The patient is neurologically intact, and the new images showed no evidence of local or distal recurrence after 1 year follow-up.

What is known and what is new?

- The gold standard treatment for MCS cases is tumor resection with wide safety margins. However, the anatomical constrains in the axial skeleton make negative margins tumor resection a challenging procedure.
- The use of a 3D neuro-navigation system has displayed a great advantage in reducing instrumentation misplacement and preservation of anatomical structures.

What is the implication and what should change now?

- Our case report illustrates the effectiveness of implementing a neuro-navigation system in the management of patients with such a type of complex spine tumors. Therefore, further studies on neuro-navigational guidance and optimal adjuvant therapy should be initiated to improve the management of MCS cases.

Case presentation

A 23-year-old female with a known case of ovarian cyst presented with a 2-year history of low back pain and constitutional symptoms. A computed tomography (CT) pelvis scan conducted in a primary healthcare center showed an incidental finding of a right sacral ala bone lesion; therefore, the patient was referred to our institution for evaluation and management. At National Guard Hospital in King Abdulaziz Medical City, the patient underwent a series of radiological evaluations, commencing with a pelvic X-ray, which showed a bony lesion of the right sacral ala, with lytic and destructive changes (*Figure 1*). Pelvic magnetic resonance imaging (MRI) with contrast showed a well-defined lesion with intermediate to high signals with intra-lesion hypointense foci located at the right wing of the upper sacrum, at the level of S1–2 and measuring 6 cm wide × 4.5 cm high × 4.5 cm deep (*Figure 2*). Chest, abdomen, and pelvis CT scans revealed no evidence of metastasis (*Figure 3*). A bone scan confirmed a solitary primary bone lesion with no active bone metastasis (*Figure 4*). The patient underwent a combined ultrasound and CT-guided biopsy under local anesthesia. Microscopic analysis of the samples showed solid sheets of undifferentiated small blue cells with a hemangiopericytoma-like vascular pattern mixed with islands of mature appearing, well-differentiated hyaline cartilage.

© AME Publishing Company.

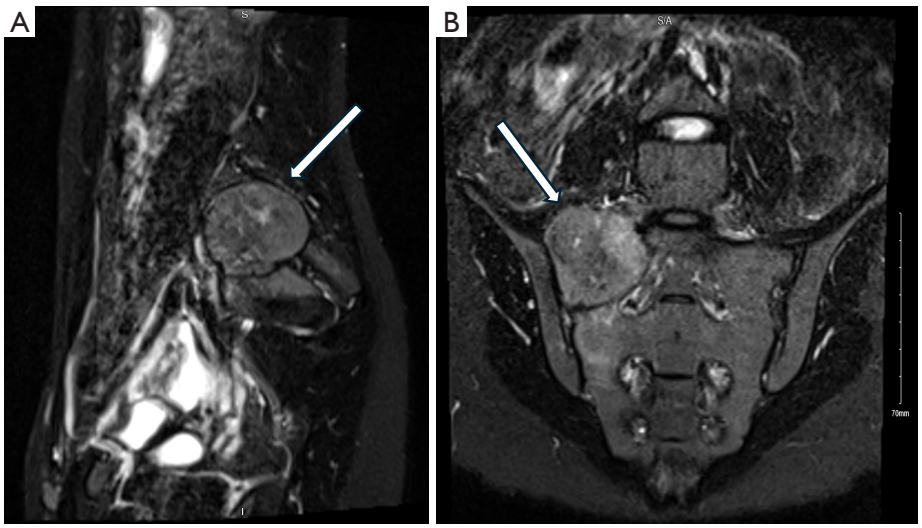

Figure 2 A T2-weighed pelvic MRI showing an intermediate to high signal following IV gadolinium administration: (A) sagittal plane; (B) coronal plane. A few intra-lesional hypointense signal foci are present, in keeping with calcification/chondroid matrix. The mass measures 5.1 cm proximal-distal × 5.0 cm medial-lateral × 4.4 cm anterior-posterior. The mass is abutting the right iliac side of the sacroiliac joint, however the joint remains intact (arrows). There is loss of the anterior cortex. MRI, magnetic resonance imaging.

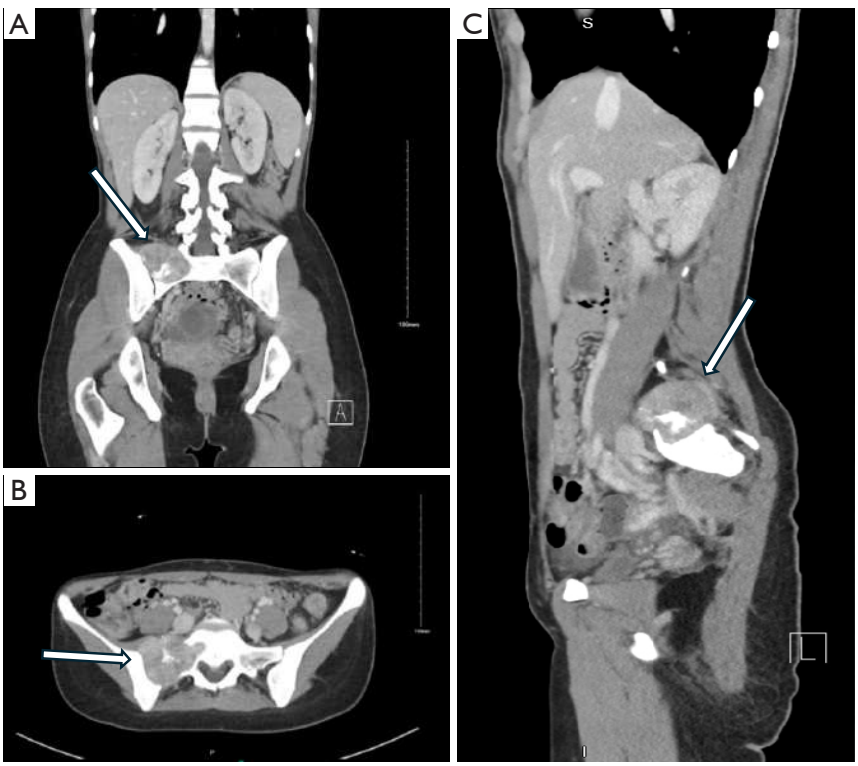

Figure 3 Abdominal and pelvis CT scan: (A) coronal plane, (B) axial plane, (C) sagittal plane, showing a well-circumscribed soft tissue lytic lesion within the superior right sacral ala which measures 5.5 cm × 4.2 cm (arrows). It shows enhancing soft tissue with some calcification centrally. It has caused some remodeling of the contour of the medial right iliac wing with no invasion into it. CT, computed tomography.

© AME Publishing Company.

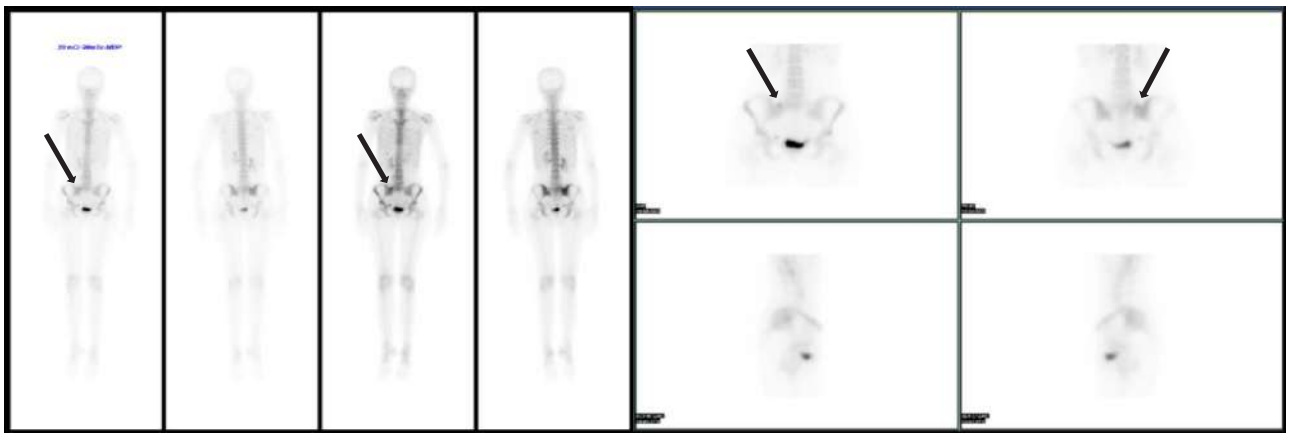

Figure 4 A bone scan. This is a baseline study showing uniform activity throughout the skeleton. A small rounded focus of activity seen anterior to the right sacroiliac joint (arrows). 20 mCi radiotracer technetium-99m was injected. mCi, millicuries.



Figure 5 Intra-operative anterior view after the osteotomies were made showing vessel loops used to identify and protect the L5 nerve roots and the major vessels. The arrow shows superior cut at level lower wedge of L5.

Immunohistochemically, the tumor cells were positive for CD99, S100 (positive in chondroid area), BCL2 and NKX2.2 and were negative for CK-PAN, CD34, CD31, ERG, STAT6, DESMIN, DOG1, TLE1. The morphology and immunochemical profile strongly supported the diagnosis of MCS.

The decision was made for a wide marginal resection. CT and MRI were used for preoperative planning and identification of the tumor margins.

The proposed operative plan was a wide marginal tumor resection utilizing anterior and posterior approaches. The patient was taken to the operative room and underwent a two-stage procedure. Stage 1 was performed with an anterior approach using a midline laparotomy incision, with the patient in the supine position. Bowel mobilization to the retroperitoneal space, in addition to small vessel ligation, was performed to properly expose the tumor site. Once the tumor margins were identified and ventral releases were performed, incomplete anterior sacral cuts were made with wide marginal considerations based on the preoperative images.

The right L5 and S1 nerve roots were identified, released, and protected, in addition to identifying and protecting the major vessels (*Figure 5*). A mesh was applied ventral to the sacrum to prevent possible herniation of the pelvic organs after the complete resection.

Stage 2 was performed with the patient in the prone position on Jackson table, using a midline posterior approach with exposure from the L3 vertebra down to the sacrum. The instrumentation was Guided using O-arm Navigation System (*Figure 6A*). L3, L4, and L5 screws were inserted bilaterally. S1 pedicle screws (7.5 mm × 40 mm) were also inserted on the left side. S2-alar-iliac screws (7.5 mm × 80 mm) were inserted on both sides. A working rod was applied on the left side.

A wide laminectomy was performed at the L5 level, and a partial laminectomy was performed at the S1 level to avoid wide-margin violation of the tumor. The dural sac, L5, and the S1 nerve root were protected and released on both sides. Using a navigation probe, the posterior wide resection margins were identified with the help of premade incomplete ventral cuts.

© AME Publishing Company.

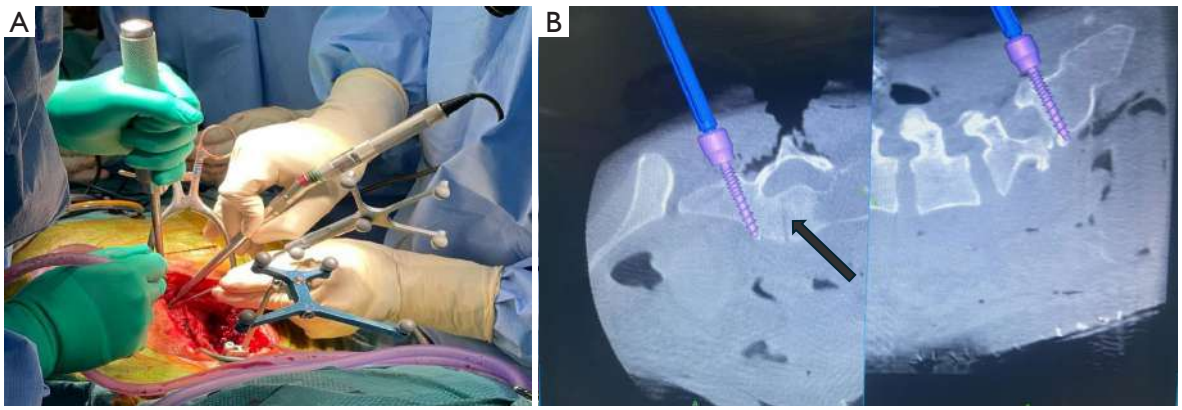

Figure 6 Intra-operative images showing the use of the O-arm 3D neuronavigation system during the posterior approach. (A) Illustrates the surgeon using the navigation probe to identify the level of vertebra to assist with the posterior cut and pedicel screw placement. (B) Showing on demand imaging from the monitor demonstrating the anterior cut that was made during the anterior approach of the procedure at the level of S1 (arrow), alongside using navigated instrumentation to assist in pedicle screws placement with sufficient medial margin. 3D, 3-dimensional.

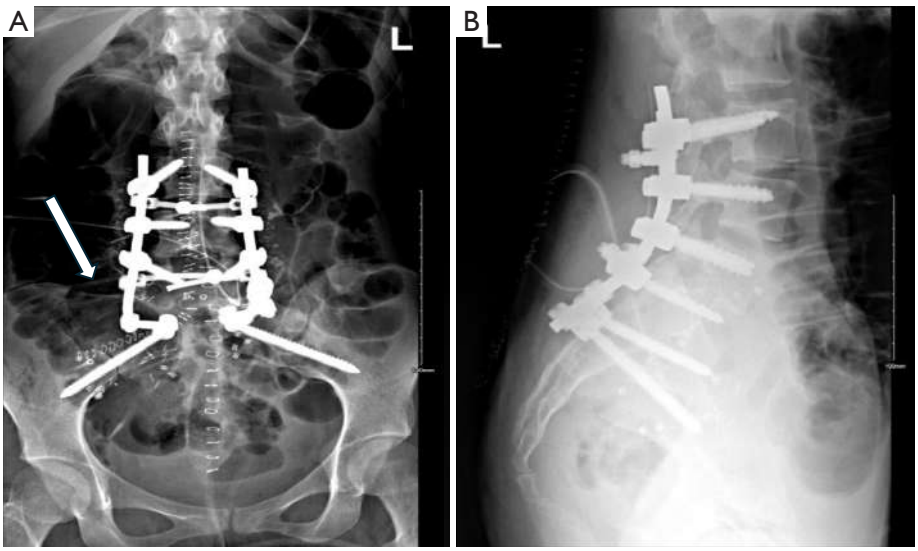

Figure 7 Post-operative lumbar spine X-ray. (A) Anteroposterior view and (B) lateral view, which presents interval insertion of pedicle screws involving L3, L4, L5, S1, and bilateral sacroiliac fixation. The resected tumor location is indicated in the right sacral ala bone (arrow).

The right hemi-sacrectomy was carried out using the O-Arm Navigation guide to perform the posterior cuts in the right sacrum and connect them with the anterior cuts to remove the tumor as *en bloc* (*Figure 6B*). The dural sac, L5, and S1 nerve roots on both sides were identified and manipulated prior to mass removal. Following the completion of all cuts, the tumor was removed as *en bloc* in a rotational fashion.

The second rod was applied on the right side, and the final tightening was completed. A Magni-fuse bone graft was also applied postero-laterally on both sides. Blood transfusion was given throughout the procedure, she received a total of 8 units of packed red blood cells. Final X-ray images is shown (*Figure 7*). The patient tolerated the procedure uneventfully and was transferred to the intensive care unit for monitoring. The resected tumor was sent for histopathology to confirm the negative margins of 15 mm in all directions (*Figure 8*).

© AME Publishing Company.

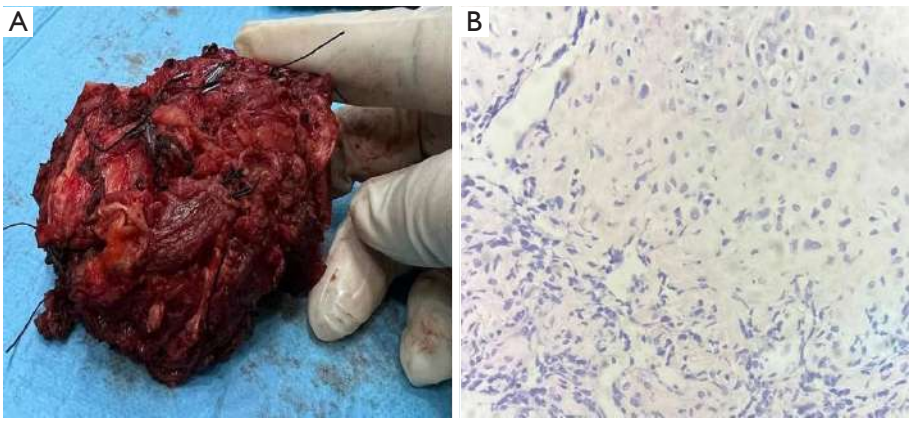

Figure 8 Histopathology assessment for the tumor specimen. (A) Macroscopic examination of an *en bloc* gross specimen measuring 10 cm from proximal to distal, 9 cm from anterior to posterior and 4 cm from medial to lateral. A well-circumscribed mass, soft-to-firm, tan-white, homogenous. The proximal, distal, lateral and medial margins of the specimen were all negative for the tumor. (B) Microscopic examination using H&E stain under ×400 magnification of the CT-guided biopsy showed undifferentiated small blue cells with hemangiopericytoma like vascular pattern mixed with islands of mature appearing, well differentiated hyalin cartilage (WHO grade 3). H&E, hematoxylin and eosin; CT, computed tomography; WHO, World Health Organization.

During her post-operative course, the patient stayed in the intensive care unit for 24 hours for observation. Neurologically, she developed right-sided motor deficits of 0/5 according to Medical Research Council Grading at L4, L5, and S1, in addition to right-sided radicular numbness. During her stay, we started lower limb exercises and applied an ankle-foot orthosis to support her footdrop. She was discharged from the hospital on the ninth day. We continued to follow her in the outpatient setting, and her wound healed uneventfully. We also observed progressive improvement in her footdrop and radicular pain. The footdrop was completely resolved at the six-month visit, and the patient was able to ambulate normally.

At the two-month visit, she was referred to a radiation oncologist and was started on high-dose adjuvant radiotherapy of 74 Gray (Gy) in 37 fractions for a total duration of three months. She experienced transient radiation-related complications, including dermatitis, headache, otalgia, and nausea. At 12 months post-operation fluorodeoxyglucose-positron emission tomography (FDG-PET) scan was performed, it revealed no evidence of local recurrence or distant lesions. At her 12-month postoperative visit, she was mobilizing independently and had completely recovered from her surgical and radiation interventions.

All procedures performed in this case were in accordance with the ethical standards of the institutional and/or national research committees and with the Helsinki Declaration (as revised in 2013). Written informed consent was obtained from the patient for the publication of this case report and accompanying images. A copy of the written consent is available for review by the editorial office of this journal.

Discussion

MCS is considered a rare but aggressive malignant subtype of secondary chondrosarcoma that has a distinct appearance of small blue cells found histopathologically. Due to the paucity of available data in the literature, guidelines regarding the significance of adjuvant treatments following surgical excision are scarce. A retrospective analysis of 205 MCS cases from 1973–2011 revealed a mean age of diagnosis of 37 years, a male proportion of 56%, and the occurrence of extra-skeletal tumors in 60% of cases (5). A single-center study of 35 patients reported a mean age of diagnosis of 26 years (6), with pain as the main presenting symptom in approximately 77% of the cases (6). Nevertheless, a variance was noted in the duration of pain prior to diagnosis from one month to 5 or more years (6). In our case, our patient's age at presentation was 23 years, and she had a 2-year history of back pain.

MCS typically presents in imaging studies as being more aggressive than primary chondrosarcoma. Plane X-ray radiographs typically show a lytic and destructive appearance, with a poorly defined periosteal reaction (7). These findings were similar to those noted in our initial radiographs (*Figure 1*). However, these changes are not

© AME Publishing Company.

specific to MCS and can mimic other pathologies, such as osteosarcoma, Ewing sarcoma, benign aggressive giant-cell tumor, eosinophil granuloma, and infectious causes (8).

In our case, MRI showed well-defined intermediate-to-high signals with a few intra-lesion hypointense signal foci related to calcification (*Figure 2*), which is a similar finding seen in MCS cases in the literature (9). Furthermore, CT findings typically consist of nonspecific destructive changes with subtle matrix mineralizing, as seen in our patient's CT images (*Figure 3*). We also used a skeletal scintigraphy scan with a technetium-99m (Tc99m) radiotracer complexed to methylene diphosphonate (MDP) to detect any distant osseous metastatic disease, but none was found (*Figure 4*). Clearly, a full radiological investigation is paramount in these patients. Using different radiological modalities will help narrow the differential diagnosis and staging.

Bone biopsy is critical and mandatory when investigating patients with bone lesions. In our case, the bone biopsy was obtained under CT guidance and in proximity to the future surgical site to decrease the risk of local tumor seeding. The microscopic appearance showed small undifferentiated blue cells with a hemangiopericytoma-like vascular pattern mixed with islands of mature-appearing and well-differentiated hyaline cartilage (*Figure 6*). These features are consistent with the reported MCS histopathological findings described by the literature (10).

The small blue cells can be described as spindle-shaped cells arranged around blood vessels in structures known as hemangiopericytomas. Immunohistochemical biomarkers can further aid in distinguishing MCS. The small blue cell component may stain positive for CD57, CD99, NK2 homeobox 2 (NKX2.2), and SRY-box transcription factor 9 (SOX-9) (10). Our patient's sample showed positivity for CD99, BCL-2, and NKX2, and her chondroid cartilage area component showed positivity for the S100 protein. The CD99, BCL-2, and NKX2 markers are useful for identifying the small cell component; however, they show positive staining in other pathologies, such as Ewing sarcoma. By contrast, positivity for the S-100 protein is a distinctive feature of MCS and can eliminate the possibility of Ewing sarcoma (10).

The treatment options for MCS depend on factors such as the tumor primary location, metastasis, and the medical status of the patient. Current medical practice for resectable tumors is surgical excision with wide margins, but hurdles include the anatomical constraints that hinder the achievement of wide margins and the high local recurrence rates (10). The anatomical challenges dictate careful preoperative planning to avoid positive margins. The complexity of bone geometry, soft tissues, and neural anatomy further complicates the resection technique. Removing more than 50% of the S1–2 vertebrae for localized sacral tumors will lead to lumbopelvic instability and will require reconstruction, while variations in tumor location and extension will make resection more challenging (11). High sacral lesions that involve the S1–2 levels mandate a dual-approach technique to achieve *en bloc* resection with negative margins.

Thorough planning is needed prior to performing the operative resection. This includes margin determinations based on 3D images and the detection of nearby neurovascular structures. In addition, retroperitoneal structures, including ureters, major vessels, and the lumbosacral plexus, should all be considered during preoperative planning. Involving a urologist, plastic and general surgeons is advisable for comprehensive multidisciplinary planning. In our case, we did not require any soft tissue coverage; however, consultation with a plastic surgeon is warranted, and the coverage need depends on different variables, including tumor size and patient body habitus.

Pedicle screws and spinopelvic fixation are the mainstays for mitigating biomechanical instability following sacral resection. In contrast to conventional instrumentation placement, real-time three-dimensional navigational placement has evolved and is now widely utilized. Nevertheless, conventional image guidance can lead to pedicle screw misplacement and prolonged surgical time, which can hinder surgical outcomes (12). In our case, all image guidance-related instrumentation was performed using O-arm navigation for better accuracy and less instrumentation time. During our preoperative planning, we determined that anterior column reconstruction was not justified based on the estimated resection size and location.

A study conducted in 2015 demonstrated that obtaining negative margins was highly associated with a decrease in tumor recurrence (2). Achieving negative margins requires planning of the intended bone cuts with wide margins; however, accurate execution is the cornerstone for achieving negative margins. Utilizing a dual approach can noticeably improve navigation around the tumor. The anterior approach permits wider exposure and thorough releases. The initial bone cuts can also be made as wide as necessary, due to the larger surgical field. In our case, we performed incomplete bone cuts from the anterior approach based on our preoperative planning. During the second stage of the procedure, O-arm navigation was used to accurately

© AME Publishing Company.

locate the incomplete cuts from the posterior approach. This allowed less posterior dissection and a more accurate identification of the margins. In addition, prediction of the posterior cut location will help release the tumor from the neural elements. Based on our experience, para-sacral lesions extending beyond the midline pose challenges in releasing the dural sac from the tumor margins and removing the tumor as *en bloc*. Thus, neural tissue retraction is needed, which increases the risk of postoperative neurological symptoms.

Postoperative radiation has been postulated to reduce local recurrence in patients with MCS with positive margins (10). However, MCS is considered a slow-growing tumor, and radiotherapy acts on dividing cells; therefore, chondrogenic tumors are considered relatively resistant to radiotherapy (13). Indications for radiotherapy include optimal local control after tumor resection or situations in which resection is not achievable (13). For the latter condition, the required radiotherapy doses must be at least 60 Gy to achieve local control. In our case, the patient underwent surgical excision with wide local margins and postoperative radiotherapy of 74 Gy in 37 fractions. In our experience, the postoperative and post-radiation complications that developed were transient, and our patient was able to recover completely.

Nevertheless, some reports in the literature indicate that MCS has a poor prognosis, although data are scarce (5). A 10-year survival rate ranging from 20–67% has been previously reported, and a 10-year overall survival of 43% has been shown based on the SEER database (5). We have followed our patient for more than 12 months and have not seen any recurrence.

Conclusions

MCS is an aggressive form of nonconventional chondrosarcoma that can be treated with surgical excision with wide margins. Nevertheless, due to the limitations imposed in accessing the axial skeleton and the neurovascular component, MCS remains a challenging condition to treat. Therefore, further studies on neuro-navigational guidance and optimal adjuvant therapy should be initiated to improve the management of MCS cases.

Acknowledgments

None.

Footnote

Reporting Checklist: The authors have completed the CARE reporting checklist. Available at https://jss.amegroups.com/article/view/10.21037/jss-24-104/rc

Peer Review File: Available at https://jss.amegroups.com/article/view/10.21037/jss-24-104/prf

Funding: None.

Conflicts of Interest: All authors have completed the ICMJE uniform disclosure form (available at https://jss.amegroups.com/article/view/10.21037/jss-24-104/coif). The authors have no conflicts of interest to declare.

Ethical Statement: The authors are accountable for all aspects of the work in ensuring that questions related to the accuracy or integrity of any part of the work are appropriately investigated and resolved. All procedures performed in this case were in accordance with the ethical standards of the institutional and/or national research committees and with the Helsinki Declaration (as revised in 2013). Written informed consent was obtained from the patient for the publication of this case report and accompanying images. A copy of the written consent is available for review by the editorial office of this journal.

Open Access Statement: This is an Open Access article distributed in accordance with the Creative Commons Attribution-NonCommercial-NoDerivs 4.0 International License (CC BY-NC-ND 4.0), which permits the non-commercial replication and distribution of the article with the strict proviso that no changes or edits are made and the original work is properly cited (including links to both the formal publication through the relevant DOI and the license). See: https://creativecommons.org/licenses/by-nc-nd/4.0/.

References

1. Nazeri E, Gouran Savadkoohi M, Majidzadeh-A K, et al. Chondrosarcoma: An overview of clinical behavior, molecular mechanisms mediated drug resistance and potential therapeutic targets. Crit Rev Oncol Hematol 2018;131:102-9.
2. Xu J, Li D, Xie L, et al. Mesenchymal chondrosarcoma of bone and soft tissue: a systematic review of 107 patients in the past 20 years. PLoS One 2015;10:e0122216.

© AME Publishing Company.

3. Bloch OG, Jian BJ, Yang I, et al. A systematic review of intracranial chondrosarcoma and survival. J Clin Neurosci 2009;16:1547-51.
4. Dantonello TM, Int-Veen C, Leuschner I, et al. Mesenchymal chondrosarcoma of soft tissues and bone in children, adolescents, and young adults: experiences of the CWS and COSS study groups. Cancer 2008;112:2424-31.
5. Schneiderman BA, Kliethermes SA, Nystrom LM. Survival in Mesenchymal Chondrosarcoma Varies Based on Age and Tumor Location: A Survival Analysis of the SEER Database. Clin Orthop Relat Res 2017;475:799-805.
6. Huvos AG, Rosen G, Dabska M, et al. Mesenchymal chondrosarcoma. A clinicopathologic analysis of 35 patients with emphasis on treatment. Cancer 1983;51:1230-7.
7. Frezza AM, Cesari M, Baumhoer D, et al. Mesenchymal chondrosarcoma: prognostic factors and outcome in 113 patients. A European Musculoskeletal Oncology Society study. Eur J Cancer 2015;51:374-81.
8. Subramanian S, Viswanathan VK. Lytic Bone Lesions. Treasure Island (FL): StatPearls Publishing; 2025.
9. Mendenhall WM, Reith JD, Scarborough MT, et al. Mesenchymal Chondrosarcoma. Int J Part Ther 2016;3:300-4.
10. Dudzisz-Śledź M, Kondracka M, Rudzińska M, et al. Mesenchymal Chondrosarcoma from Diagnosis to Clinical Trials. Cancers (Basel) 2023;15:4581.
11. Ozturk AM, Ozer MA, Suer O, et al. Patient-Specific Three-Dimensional Model for a Safe Surgical Pathway in Sacral Chondrosarcoma. Indian J Surg Oncol 2019;10:107-14.
12. Knafo S, Mireau E, Bennis S, et al. Operative and Perioperative Durations in O-Arm vs C-Arm Fluoroscopy for Lumbar Instrumentation. Oper Neurosurg (Hagerstown) 2018;14:273-8.
13. Gilbert A, Tudor M, Montanari J, et al. Chondrosarcoma Resistance to Radiation Therapy: Origins and Potential Therapeutic Solutions. Cancers (Basel) 2023;15:1962.

Cite this article as: Saber A, Khashab M, Turkistani A, Karami M, Almaymoni S, Elkhalifa M, Algahtani A, Alhazmi A. A 3D navigation-guided surgical resection of a rare case of sacral spine mesenchymal chondrosarcoma: a case report. J Spine Surg 2025;11(1):197-205. doi: 10.21037/jss-24-104

© AME Publishing Company.