Related Papers
Utilization of Mechanical Circulatory Support in Patients Undergoing Percutaneous Coronary Interv...
MECHANICAL CIRCULATORY SUPPORT IN PATIENTS UNDERGOING PERCUTANEOUS CORONARY INT...
The Role of Hemodynamic Support in High-risk Percutaneous Coronary Intervention
Mechanical circulatory support in high-risk PCI and acute coronary syndrome
View more

Catheterization and Cardiovascular Interventions 73:859–865 (2009)

Original Studies

A First-in-Man Study of the Reitan Catheter Pump for Circulatory Support in Patients Undergoing High-Risk Percutaneous Coronary Intervention

Elliot J. Smith,[1] MD, MRCP, Oyvind Reitan,[2] MD, PhD, Thomas Keeble,[3] MRCP, Kerry Dixon,[4] RGN, and Martin T. Rothman[5*] FRCP, FACC, FEJC

Objectives: To investigate the safety of a novel percutaneous circulatory support device during high-risk percutaneous coronary intervention (PCI). Background: The Reitan catheter pump (RCP) consists of a catheter-mounted pump-head with a foldable propeller and surrounding cage. Positioned in the descending aorta the pump creates a pressure gradient, reducing afterload and enhancing organ perfusion. Methods: Ten consecutive patients requiring circulatory support underwent PCI; mean age 71 ± 9; LVEF 34% ± 11%; jeopardy score 8 ± 2.3. The RCP was inserted via the femoral artery. Hemostasis was achieved using Perclose™ sutures. PCI was performed via the radial artery. Outcomes included in-hospital death, MI, stroke, and vascular injury. Hemoglobin (Hb), free plasma Hb (fHb), platelets, and creatinine (cre) were measured pre PCI and post RCP removal. Results: The pump was inserted and operated successfully in 9/10 cases (median 79 min). Propeller rotation at 10,444 ± 1,424 rpm maintained an aortic gradient of 9.8 ± 2 mm Hg. Although fHb increased, there was no significant hemolysis (4.7 ± 2.4 mg/dl pre vs. 11.9 ± 10.5 post, $P = 0.04$, reference 20 mg/dl). Platelets were unchanged (pre 257 ± 74 × 10^9 vs. 245 ± 63, P = NS). Renal function improved (cre pre 110 ± 27 μmol/l vs. 99 ± 28, $P = 0.004$). The RCP was not used in one patient following femoral introducer sheath related aortic dissection. All PCI procedures were successful with no deaths or strokes, one MI, and no vascular complications following pump removal. Conclusions: The RCP can be used safely in high-risk PCI patients. This device may be an alternative to other percutaneous systems when substantial cardiac support is needed. © 2009 Wiley-Liss, Inc.

Key words: hemodynamic support device; coronary angioplasty; balloon pump

INTRODUCTION

The intra aortic balloon pump (IABP) is widely utilized as the standard mode of cardiac support among patients with cardiogenic shock undergoing reperfusion and revascularization, with treatment refractory coronary ischemia as a bridge to revascularization, and in high-risk patients undergoing percutaneous coronary intervention (PCI) [1,2]. In the latter setting, registry data suggest that the IABP may prevent intraprocedural major adverse cardiac and cerebral events [3], and randomized studies are ongoing [4]. However, the IABP has limited efficacy in the setting of tachyarrhythmia, and is contraindicated in the setting of aortic valve incompetence.

The Reitan catheter pump (RCP) (CardioBridge GmbH, Hechingen, Germany) is a novel fully percutaneous circulatory support system consisting of a catheter-mounted distal pump-head with a foldable propeller and surrounding cage (Fig. 1a), an interface unit, and

[1]Consultant Cardiologist, Department of Cardiology, London Chest Hospital, United Kingdom
[2]Specialist in Cardiology, Heart Failure Unit, Department of Cardiology, University Hospital Lund, Sweden
[3]Research Registrar in Cardiology, Department of Cardiology, London Chest Hospital, United Kingdom
[4]Senior Research Coordinator, Department of Cardiology, London Chest Hospital, United Kingdom
[5]Professor of Interventional Cardiology, Department of Cardiology, London Chest Hospital, United Kingdom

Conflict of interest: Dr. Oyvind Reitan is a Clinical Director and shareholder in CardioBridge GmbH (Hechingen, Germany).

*Correspondence to: Martin T. Rothman, Cardiac Research and Development, Barts and the London NHS Trust, The London Chest Hospital, Bonner Road, London E2 9JX.
E-mail: martin.rothman@bartsandthelondon.nhs.uk

Received 22 September 2008; Revision accepted 4 October 2008

DOI 10.1002/ccd.21865
Published online 18 May 2009 in Wiley InterScience (www.interscience.wiley.com).

© 2009 Wiley-Liss, Inc.

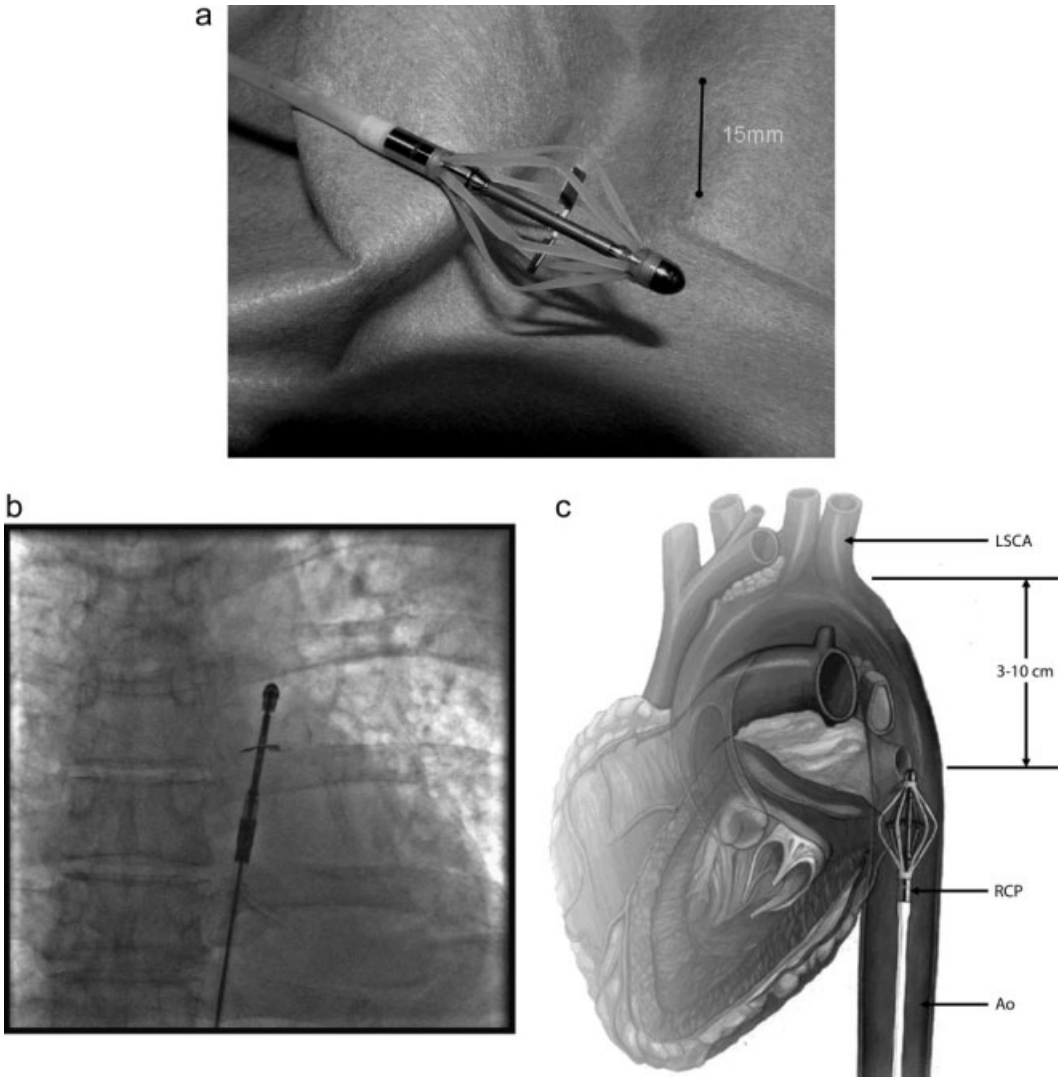

Fig. 1. (a) The Reitan catheter pump head deployed. The propeller is deployed ex vivo surrounded by longitudinal polymer filaments forming a cage protecting the aortic wall from the rotating propeller. (b) Fluoroscopic image of the deployed pump head in vivo. The pump head has been deployed fluoroscopically in the descending aorta. The polymer filaments are not visible. (c) Diagram demonstrating the correct positioning of the Reitan catheter pump in the descending aorta. The deployed pump head (RCP) sits in the descending aorta (Ao) 3 to 10 cm distal to the origin of the left subclavian artery (LSCA).

an external drive unit with user console. Via the femoral artery the collapsed pump-head is delivered through a 14 French sheath and positioned in the proximal descending aorta, distal to the left subclavian artery (Fig. 1b and c). Once in situ the cage is deployed and the propeller arms are extended and rotated. The pump creates a pressure gradient within the aorta that has been demonstrated to reduce afterload and increase organ perfusion in animal studies [5,6]. The RCP does not require ECG synchronization, and can be utilized in the presence of aortic regurgitation. In contrast to the Impella® 2.5 LP device (Abiomed, Danvers, US), another percutaneous axial flow pump that has also been utilized in the setting of high-risk PCI [7], the RCP is not sited within the left ventricular (LV) cavity and therefore is not contraindicated in the presence of LV thrombus.

We describe the first-in-man safety and feasibility study utilizing the RCP for cardiac support during high-risk PCI.

METHODS

Patients

Between March and August 2007, 10 patients underwent high-risk PCI at a single center with planned cardiac support utilizing the RCP. High-risk patients were defined as those with either significantly impaired left

TABLE I. Baseline Characteristics of Patients Undergoing Percutaneous Coronary Intervention with Planned Cardiac Support Using the Reitan Catheter Pump

	All patients $n = 10$
Patient characteristics	
Age (mean ± sd)	71 ± 9
Male sex	9
Diabetes	6
Previous PCI	4
Previous CABG	7
Previous MI	7
Acute coronary presentation (with troponin elevation)	7 (5)
CCS class (angina) 3/4	8
NYHA class III/IV	4
Mean LVEF (%)	34 ± 11
Atrial fibrillation	3
Lesion characteristics	
Left main stem intervention	5
Protected	2
Unprotected	3
Vein graft intervention	3
Multivessel intervention	3
Jeopardy score (mean ± sd)	8 ± 2.3

ventricular function (angiographic or echocardiographic), a large myocardial territory at risk (measured using the Duke myocardial jeopardy score [8]), or a combination of these. Two operators (MTR, EJS) identified patients that would have routinely undergone PCI with IABP support at the center. The study was approved by the Cambridge Research Ethics Committee (reference: 06/Q0108/346) and the Medicines and Healthcare Products Regulatory Agency (reference: CI/2006/0037).

Baseline patient and lesion characteristics are demonstrated in Table I. The majority of patients recruited had a history of prior myocardial infarction, previous coronary bypass surgery, and underwent PCI in the setting of an acute coronary presentation. Half underwent left main coronary intervention, and three of the remaining patients underwent PCI to a saphenous or arterial bypass graft.

Procedure

The RCP was inserted before PCI and removed 1–6 hr postprocedure. A radial artery sheath was inserted to allow pressure measurement and access for PCI. Femoral arterial access was obtained initially using a 6 French sheath, and angiography of the proximal descending aorta performed to confirm a diameter $\geq$22 mm to ensure safe deployment of the pump head. Peripheral angiography was performed to exclude obstructive femoro-iliac disease or severe tortuosity. Two Perclose™ device sutures were inserted (Abbott Vascular, IL,) at right angles before the introduction of a 30-cm 14-French introducer sheath (Ultimum EV, St. Jude Medical, USA, external diameter 5.5 mm). The sheath was advanced with a tapered dilator over a 0.38-inch guide wire into the distal descending aorta. The dilator and wire were removed and the collapsed pump head delivered directly into the aorta. The device was positioned fluoroscopically 3–10 cm distal to the origin of the left subclavian artery, and the pump head deployed (Fig. 1b and c). The propeller was rotated at 8,000–13,000 rpm to maintain a target radial to femoral transaortic pressure gradient of 10 mm Hg in all cases. Activated clotting time was maintained at 250–300 sec using a weight adjusted heparin bolus (70 U/kg) followed by an infusion through the femoral arterial sheath side arm. Following pump removal, femoral hemostasis was achieved using the two Perclose™ sutures as has been described utilizing the Impella® 2.5 LP device [9].

PCI was performed via the radial artery in all cases with 6 or 7 French catheters, to avoid compromise of the RCP. Radial hemostasis was achieved using a TR band™ (Terumo Interventional Systems, Belgium) in all cases.

Outcomes

Clinical events (death, nonfatal myocardial infarction, stroke, arterial complications) were assessed intraprocedurally and to hospital discharge. Major bleeding was defined as any of the following: a fall in hemoglobin (Hb) >4 g/dl; overt bleeding with a fall in Hb >3 g/dl; the requirement for a blood transfusion of two or more units; retroperitoneal or intracranial hemorrhage. Minor bleeding was defined as overt bleeding not meeting the criteria for a major bleed.

Blood samples were obtained pre PCI and post RCP removal for full blood count, free plasma hemoglobin as a measure of hemolysis, and platelet count. Serum creatinine was measured at a mean of 14 hr postprocedure.

Following pump removal, the pump heads were rinsed in saline and the components inspected for thrombus formation and fibrin deposition.

Statistics

Analysis of blood results pre and post RCP removal was performed using paired *t*-tests. A P-value < 0.05 was considered statistically significant.

RESULTS

Pump Insertion and Function

The pump was inserted and operated successfully in nine of 10 cases. The propeller was rotated at a mean of 10,444 ± 1,424 rpm maintaining a mean radial to

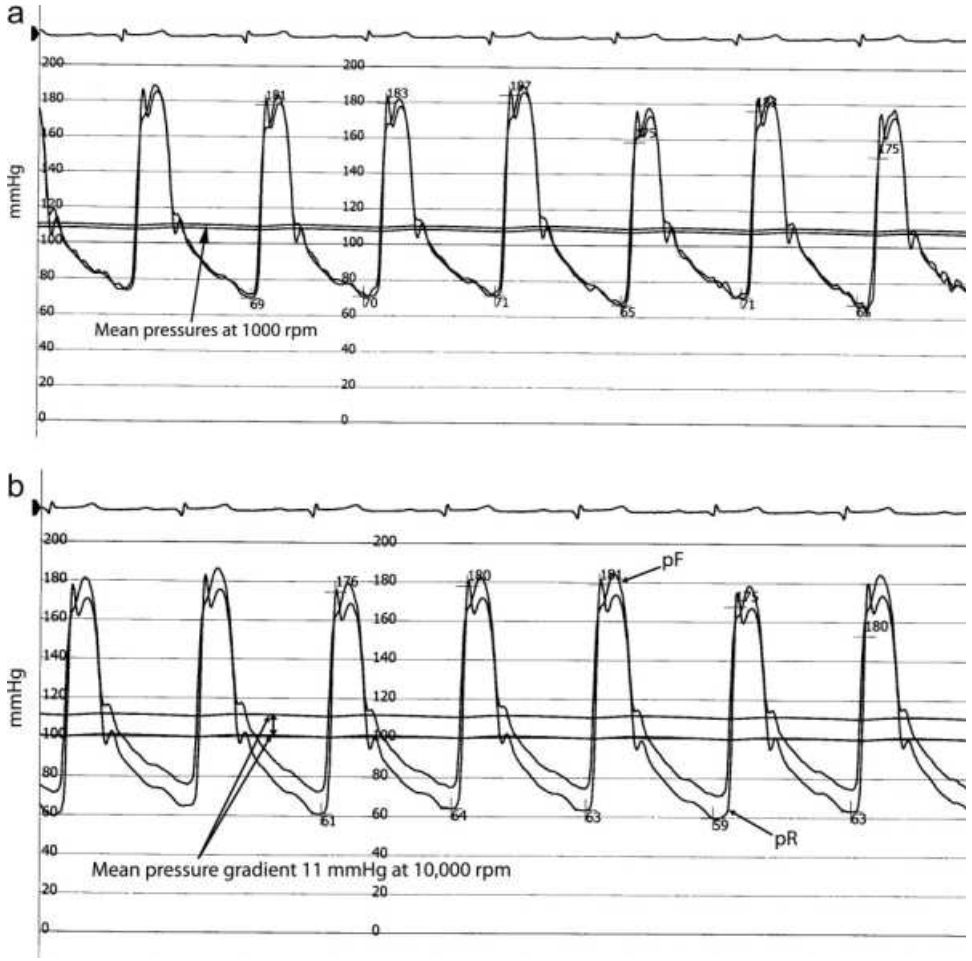

Fig. 2. Simultaneous radial and femoral pressure traces pre and post Reitan catheter pump activation. (a) Simultaneous radial and femoral pressure traces are demonstrated for patient no. 10 pre and post pump activation. Following pump insertion the pump is routinely started at 1,000 rpm to ensure appropriate pump function and reduce thrombotic risk. Radial and femoral pressure traces are superimposed, with no significant pressure gradient generated. (b) The pump is activated when propeller rotation exceeds 8,000 rpm. In this case propeller rotation at 10,000 rpm results in an increase in femoral pressure (pF) and a decrease in radial pressure (pR), resulting in a mean transaortic pressure gradient of 11 mm Hg.

femoral aortic pressure gradient of 9.8 ± 2.0 mm Hg. Heart rate was unchanged, 70 ± 19 pre vs. 69 ± 16 during pump operation ($P = 0.55$). The RCP remained in situ for median (IQR) duration of 79 min (54–114) with a maximum duration of 334 min. All patients were awake with no discomfort during pump insertion, operation, and removal. Figure 2 demonstrates the effect of pump activation on femoral and radial pressures.

In one patient, the introducer sheath entered a dissection flap arising in the descending aorta. The RCP was advanced, but the cage could not be deployed. Angiography demonstrated the device had been advanced into an aortic dissection flap. The patient was an elderly female with a small atheromatous distal aorta (diameter 12.2 mm). It is likely that the position of the 14 F sheath tip following wire and dilator removal was not entirely coaxial with the aortic lumen, and adjacent to a diseased area of aortic wall. Subsequent passage of the RCP on this occasion allowed the device to pick up and enter a dissection flap. The resulting dissection was treated conservatively, with no further complication. The patient remained hemodynamically stable and PCI was performed without hemodynamic support as the patient had coexistent aortic incompetence preventing the use of an IABP. There was no evidence of major or minor bleeding, and no clinical event subsequent to this.

Intraprocedural and In-Hospital Clinical Events

All PCI procedures were performed successfully. There were no deaths or strokes. Of the nine patients undergoing PCI with RCP support, one patient suffered a non ST elevation myocardial infarction. In this

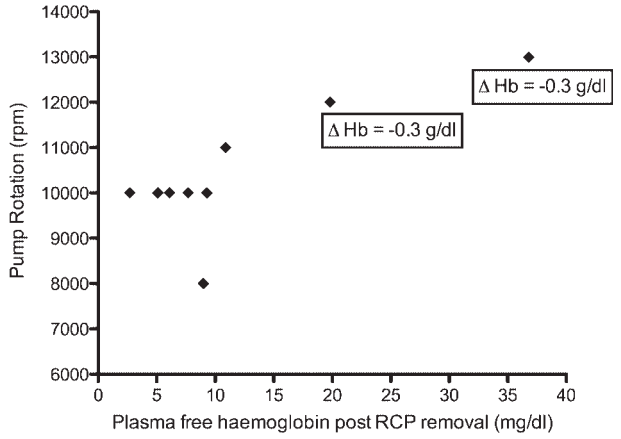

Fig. 3. Relation between speed of rotation of the Reitan catheter pump (RCP) propeller and plasma free hemoglobin level following pump removal (n = 9 patients). No clinically relevant change in total hemoglobin (ΔHb) was observed even at propeller rotation ≥12,000 rpm.

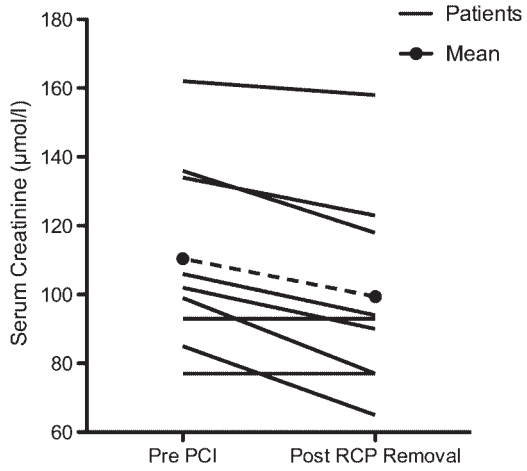

Fig. 4. Serum creatinine level before intervention and following removal of the Reitan catheter pump (RCP) (n = 9 patients). Serum creatinine fell at a mean of 14 hr in 7/9 patients following pump removal, with a significant reduction in mean creatinine.

patient PCI to a right coronary venous bypass graft was planned in the setting of reduced left ventricular function (LVEF 25%), with preserved inferior wall motion (in the territory of the vein graft) and a pre-existing anteroapical myocardial infarction. PCI could not be performed using a distal protection device due to severe luminal stenosis. Initial stent implantation resulted in no reflow (TIMI grade 1), which resolved after the administration of intracoronary vasodilators and the implantation of three further stents. The total duration of ischemia before restoration of TIMI grade 3 flow was 17 min. Despite resulting in infarction (peak creatine kinase 1,015 IU, upper reference limit 172 IU), this event was not associated with hemodynamic compromise or reduction in cardiac transaortic gradient. The patient made an uncomplicated recovery and was well at hospital discharge.

One other patient suffered an intraprocedural ischemic complication that might otherwise have been associated with hemodynamic instability in the absence of a cardiac support device. In this patient (LVEF 38%) initial balloon inflation in a native left anterior descending artery lesion was complicated by abrupt vessel closure. Blood pressure remained unchanged and the patient remained pain free before definitive revascularization with a stent after an ischemic period of 3 min. This event did not result in a myocardial infarction.

Complete femoral hemostasis was achieved with the Perclose™ sutures alone in 8/10 patients, and partial hemostasis in 2/10 supported by a Femostop® device (Radi Medical Systems, Sweden). There were no radial or femoral minor or major bleeding complications. There were no clinical signs of limb ischemia pre or post procedure.

Hematological and Renal Outcomes

The RCP did not result in clinically significant hemolysis. The mean plasma free hemoglobin rose from 4.7 ± 2.4 mg/dl pre procedure to 11.9 ± 10.5 mg/dl post pump removal (P = 0.04), below the upper reference limit of 20 mg/dl. There was no association between the duration of RCP support and fHb level. Pump rotation ≥12,000 rpm did result in greater fHb levels post RCP removal (Fig. 3), though not leading to a clinically relevant fall in total hemoglobin. There was a small but significant decrease in total hemoglobin (12.8 ± 1.6 g/dl pre, 12.3 ± 1.7 d/dl post, P = 0.03) consistent with intraprocedural blood loss. Hematocrit remained unchanged (mean 0.4 ± 0 pre and post procedure). Platelet count was also unaffected by RCP operation (mean pre PCI 257 ± 74 × 10^9 vs. 245 ± 63 × 10^9 post device removal, P = NS).

Baseline serum creatinine fell in 7/9 patients post pump removal. The mean reduction was 11 ± 8 μmol/l (P = 0.004) (Fig. 4), which translated to a calculated increase in mean glomerular filtration rate (GFR) from 66.7 ± 18.1 ml/min to 74.9 ± 23.6 ml/min.

Pump Inspection

Following pump removal, there was no evidence of thrombus or fibrin deposition on the pump head components.

DISCUSSION

This first-in-man study has demonstrated the safety and feasibility of percutaneous hemodynamic support using the RCP during high-risk PCI. In this series one

adverse event occurred as a complication of introducer sheath insertion which prevented use of the device. There were no pump-related complications or device failures. Damage to blood elements and specifically hemolysis is an issue of concern related to all ventricular assist devices. In this study there was no platelet consumption, and minimal hemolysis. The data (fHb 11.9 mg/dl post procedure) compare favorably with the documented hemolysis related to the Impella® LP 2.5 in a similar setting (fHb ~60 mg/dl at 1 hr [10]).

Two patients developed intraprocedural ischemic complications during PCI, one of which resulted in a non ST elevation myocardial infarction. Neither of these events resulted in hemodynamic compromise during the procedure, even though both patients had significant pre-existing left ventricular impairment. Despite the high-risk nature of the cohort, there were no other adverse events during PCI using the RCP. Femoral arterial hemostasis at the site of the 14 French introducer sheath was achieved successfully in all cases without complication. These early data are encouraging, and may suggest this device could have a future role in reducing ischemic complications in high-risk patients undergoing PCI, and preventing compromise in those that do develop ischemia.

Comparison With Existing Circulatory Support Devices

The RCP may have the potential to offer more effective cardiac support than intra aortic balloon counterpulsation while being less invasive when compared to the Impella® 2.5LP which requires positioning within the left ventricle, and the Tandem Heart® Percutaneous Ventricular Assist Device (pVAD)™ system (Cardiac Assist, Pittsburgh, PA) which necessitates trans septal puncture with a 21 F sheath and up to two arteriotomies with 12–19 F sheaths [11,12]. However, a direct comparison between the available percutaneous circulatory support devices is difficult as the nature of the support systems differs.

Both the RCP and the IABP work in series with the heart, which means that the left ventricle ejects the total cardiac output through the aortic valve. The IABP modifies intra-aortic pressure to reduce afterload, but requires ECG synchronization and has limited pump function itself.

Because the RCP is a continuous nonphasic pump, it may be more effective than the IABP in the setting of atrial fibrillation or recurrent tachyarrhythmias. As a consequence of its folding propeller design, the pump can generate high flow rates; up to 20 liters per minute at 12,000 rpm in vitro. In vivo this high flow creates a pressure gradient inside the aorta thereby reducing the pressure proximal to the propeller resulting in afterload reduction, and increases pressure distal to the propeller resulting in increased perfusion to the lower part of the body.

The finding in this study that the serum creatinine fell significantly postprocedure supports the concept of increased lower body perfusion, although intraprocedural hydration may have exerted an influence. 3/9 RCP supported patients had a GFR below 50 ml/min before PCI reflecting the high-risk nature of the cohort. These three patients received *N*-acetyl cysteine orally pre and post procedure, and a maximum of 500 ml of intravenous saline over the 12-hr period before intervention. No patients subsequently developed contrast nephropathy. Further studies to evaluate the effect on the RCP on renal function are now being considered, with serial measures of creatinine over a 72-hr period, and a control group to compare results with the hydration alone.

In contrast to both the RCP and IABP, the Impella 2.5 LP works in parallel with the left ventricle taking over a part of the cardiac output (up to a maximum of 2.5 l per min) and reducing stroke volume. The device is sited within the left ventricle crossing the aortic valve, and is therefore contraindicated in patients with LV thrombus or significant aortic regurgitation. The Tandem Heart® has a similar effect as this system bypasses the left ventricle. Comparison between support systems can therefore only be studied through investigation of the hemodynamic response of the patient including total cardiac output, left ventricular filling pressures (pulmonary capillary wedge), and the clinical outcome. A limitation of this initial safety study was that quantification of hemodynamic effect of the RCP was confined to the radial-femoral pressure gradient. Although this has been shown to result in substantial afterload reduction in an animal model of left ventricular failure [5], invasive hemodynamic monitoring was not routinely performed. Assessment of hemodynamic endpoints including pulmonary capillary wedge pressure, cardiac output, and vascular resistance are the focus of an ongoing efficacy study of the RCP in patients with decompensated chronic left heart failure.

Limitations

The present study has other limitations. None of the patients studied were in established cardiogenic shock, and despite the high-risk nature of the cohort, only two patients undergoing PCI with RCP support developed intraprocedural ischemic complications. While we speculate that the device prevented hemodynamic compromise in the remaining patients, it is possible that these patients may not have required cardiac support. Furthermore, the absence of hemodynamic compromise

during ischemic complications in the setting of significantly impaired left ventricular function may infer a benefit from RCP cardiac support but does not prove it. Also coronary blood flow was not recorded in this study. Generation of an aortic pressure gradient with lower pressure in the ascending aorta and higher pressure distal to the pump head in the proximal descending aorta raises the possibility that the pump may reduce rather than enhance coronary perfusion. A prior study in a calf model of acute left ventricular failure did suggest a reduction in diastolic coronary flow using the RCP when compared with the IABP [13], although interestingly systolic coronary flow was enhanced with no reduction in net coronary flow. Furthermore, there was no coronary flow reduction in a subsequent study using another calf model [6]. Invasive coronary blood flow will be assessed in future studies. Importantly the role of hemodynamic support for high-risk PCI with existing percutaneous support technologies (specifically the IABP or Impella® 2.5 LP device) is not yet fully established, although planned and ongoing randomized studies will address this question [4,14].

In its present form, the pump itself has limitations related to the PCI procedure. Firstly the design of the pump head cage (Fig. 1) does not yet permit simultaneous cardiac catheterization from the femoral route, necessitating a radial PCI approach in all cases. Secondly the pump head size currently necessitates a 14 French sheath, which cannot be inserted in small, diseased or tortuous femoral or iliac vessels. Since the completion of this study a 10 French compatible pump has already been developed, and a mechanism to provide transverse protection of the propeller to allow simultaneous femoral catheterization is being considered. In addition, conversion of the RCP [to an over-the-wire] technology is being developed, which may further reduce the risk of vascular complications.

Finally in this series the Reitan pump remained in situ for a maximum of 334 min without complication. It is now necessary to demonstrate the safety of the device over a prolonged support period, as has been described using other percutaneous support technologies. Prolonged cardiac support utilizing the RCP is currently being investigated in the ongoing hemodynamic efficacy study of the device in patients with decompensated chronic left heart failure.

CONCLUSIONS

The RCP is a novel percutaneous hemodynamic support device that is rhythm independent and can safely be used in high-risk patients undergoing percutaneous intervention. Further planned studies will elucidate whether this device may be a viable alternative to other available percutaneous support systems when substantial circulatory support is needed.

REFERENCES

1. Ferguson JJ III, Cohen M, Freedman RJ Jr, Stone GW, Miller MF, Joseph DL, Ohman EM. The current practice of intra-aortic balloon counterpulsation: Results from the Benchmark Registry. J Am Coll Cardiol 2001;38:1456–1462.
2. Stone GW, Ohman EM, Miller MF, Joseph DL, Christenson JT, Cohen M, Urban PM, Reddy RC, Freedman RJ, Staman KL, Ferguson JJ III. Contemporary utilization and outcomes of intra-aortic balloon counterpulsation in acute myocardial infarction: The benchmark registry. J Am Coll Cardiol 2003;41:1940–1945.
3. Briguori C, Sarais C, Pagnotta P, Airoldi F, Liistro F, Sgura F, Spanos V, Carlino M, Montorfano M, Di Mario C, Colombo A. Elective versus provisional intra-aortic balloon pumping in high-risk percutaneous transluminal coronary angioplasty. Am Heart J 2003;145:700–707.
4. Redwood SR, Perera D, Stables R, Thomas M. The Baloon-Pump Assisted Coronary Intervention Study (BCIS-I). Advanced Cardiovascular Intervention. Jan 2009 (Conference Proceeding).
5. Reitan O, Ohlin H, Peterzen B, Granfeldt H, Steen S, Emanuelsson H. Initial tests with a new cardiac assist device. ASAIO J 1999;45:317–321.
6. Reitan O, Steen S, Ohlin H. Hemodynamic effects of a new percutaneous circulatory support device in a left ventricular failure model. ASAIO J 2003;49:731–736.
7. Henriques JP, Remmelink M, Baan J Jr, van der Schaaf RJ, Vis MM, Koch KT, Scholten EW, de Mol BA, Tijssen JG, Piek JJ, de Winter RJ. Safety and feasibility of elective high-risk percutaneous coronary intervention procedures with left ventricular support of the Impella Recover LP 2.5. Am J Cardiol 2006; 97:990–992.
8. Califf RM, Phillips HR III, Hindman MC, Mark DB, Lee KL, Behar VS, Johnson RA, Pryor DB, Rosati RA, Wagner GS. Prognostic value of a coronary artery jeopardy score. J Am Coll Cardiol 1985;5:1055–1063.
9. Garatti A, Colombo T, Russo C, Lanfranconi M, Milazzo F, Catena E, Bruschi G, Frigerio M, Vitali E. Left ventricular mechanical support with the Impella Recover left direct microaxial blood pump: A single-center experience. Artif Organs 2006;30: 523–528.
10. Valgimigli M, Steendijk P, Sianos G, Onderwater E, Serruys PW. Left ventricular unloading and concomitant total cardiac output increase by the use of percutaneous Impella Recover LP 2.5 assist device during high-risk coronary intervention. Catheter Cardiovasc Interv 2005;65:263–267.
11. Thiele H, Lauer B, Hambrecht R, Boudriot E, Cohen HA, Schuler G. Reversal of cardiogenic shock by percutaneous left atrial-to-femoral arterial bypass assistance. Circulation 2001;104: 2917–2922.
12. Thiele H, Sick P, Boudriot E, Diederich KW, Hambrecht R, Niebauer J, Schuler G. Randomized comparison of intra-aortic balloon support with a percutaneous left ventricular assist device in patients with revascularized acute myocardial infarction complicated by cardiogenic shock. Eur Heart J 2005;26:1276–1283.
13. Dekker A, Reesink K, van der Veen V, Van Ommen V, Geskes G, Soemers C, Maessen J. Efficacy of a new intraaortic propeller pump vs the intraaortic balloon pump: an animal study. Chest 2003;123:2089–2095.
14. Abiomed ReceivesConditional FDA Approval for Impella 2.5 Pivotal Study at up to 150 Hospitals. Available at: www.abiomed.com.2007.