Online November 8, 2024
Journal of Neuroendovascular Therapy 2025; 19: 2024-0063 DOI: 10.5797/jnet.tn.2024-0063

Technical Note

Bailout Technique for Protrusion and Migration of Detached Woven EndoBridge Devices with Amplatz Goose Neck Microsnare

Takeya Suzuki, Ichiro Nakahara, Shoji Matsumoto, Jun Morioka, Tetsuya Hashimoto, Akiko Hasebe, Jun Tanabe, Junpei Koge, Sadayoshi Watanabe, and Kenichiro Suyama

Objective: The Woven EndoBridge (WEB; MicroVention TERUMO, Tustin, CA, USA) is an intrasaccular flow disruptor developed for the treatment of wide-neck bifurcation aneurysms (WNBA). While its safety and satisfactory mid- to long-term treatment outcomes have been documented, there have also been reports of complications such as WEB protrusion and migration. We encountered 3 cases in which the WEB protruded or migrated to the parent vessel after deployment, necessitating retrieval. In this report, we address the technical tips for retrieval techniques and factors associated with these complications, including a literature review.

Case Presentation: Of the 120 cases of our experience with WEB treatment for cerebral aneurysms for the period since January 2021, 3 required WEB retrievals. In 2 cases, significant WEB migration toward the parent vessel occurred while maneuvering the delivery microcatheter because of sticky detachment. In the remaining case, after detachment of the WEB, tilting occurred, leading to a strong protrusion into one of the branches, which prevented guiding the microcatheter for bailout stenting. In all cases, the proximal marker of the WEB was captured using an Amplatz Goose Neck Microsnare (Medtronic, Minneapolis, MN, USA) pulled back into the VIA catheter (the delivery catheter for the WEB; MicroVention TERUMO), and further into an intermediate catheter positioned as close to the aneurysm as possible, enabling uneventful retrieval.

Conclusion: None of the cases damaged the aneurysm or proximal parent vessel wall, and additional aneurysm occlusion treatment was performed. However, WEB protrusions and migration are rare. When retrieval is required, it is crucial to act swiftly owing to the risk of distal thrombosis from the lumen inside of the WEB. Therefore, recognizing Goose Neck Microsnare as a retrieval technique is valuable.

Keywords amplatz goose neck microsnare, Woven EndoBridge, migration, protrusion, retrieval

Introduction

Wide-neck bifurcation aneurysms (WNBA), which account for 26% to 36% of all intracranial cerebral aneurysms,[1] are treated with endovascular therapy owing to the development of adjunctive techniques, such as stent-assisted and balloon-assisted coils. However, achieving a sufficient occlusion rate remains challenging, and the recanalization rate is relatively high.[2] The Woven EndoBridge (WEB; MicroVention TERUMO, Tustin, CA, USA) is an intrasaccular flow disruptor developed for the treatment of WNBA. The structure is a basket-shaped woven nitinol/titanium wire with a mesh pattern. The metal coverage rate at the bottom of the WEB is approximately 60% to 65% on average (depending on the device size).[1] When placed inside the aneurysm, it blocks blood flow into the aneurysm at the neck, promoting thrombosis and organization within the aneurysm. In addition, it serves as a scaffold for neointimal formation in the neck, leading to aneurysm healing. To date, several retrospective and prospective

Department of Comprehensive Strokology, Fujita Health University School of Medicine, Toyoake, Aichi, Japan

Received: June 28, 2024; Accepted: October 3, 2024
Corresponding author: Takeya Suzuki. Department of Neurosurgery, SASSA General Hospital, 4-24-15 Tanashi-cho, Nishitokyo, Tokyo 188-0011, Japan
Email: takeya.suzuki@gmail.com

This work is licensed under a Creative Commons Attribution-NonCommercial-NoDerivatives International License.
©2025 The Japanese Society for Neuroendovascular Therapy

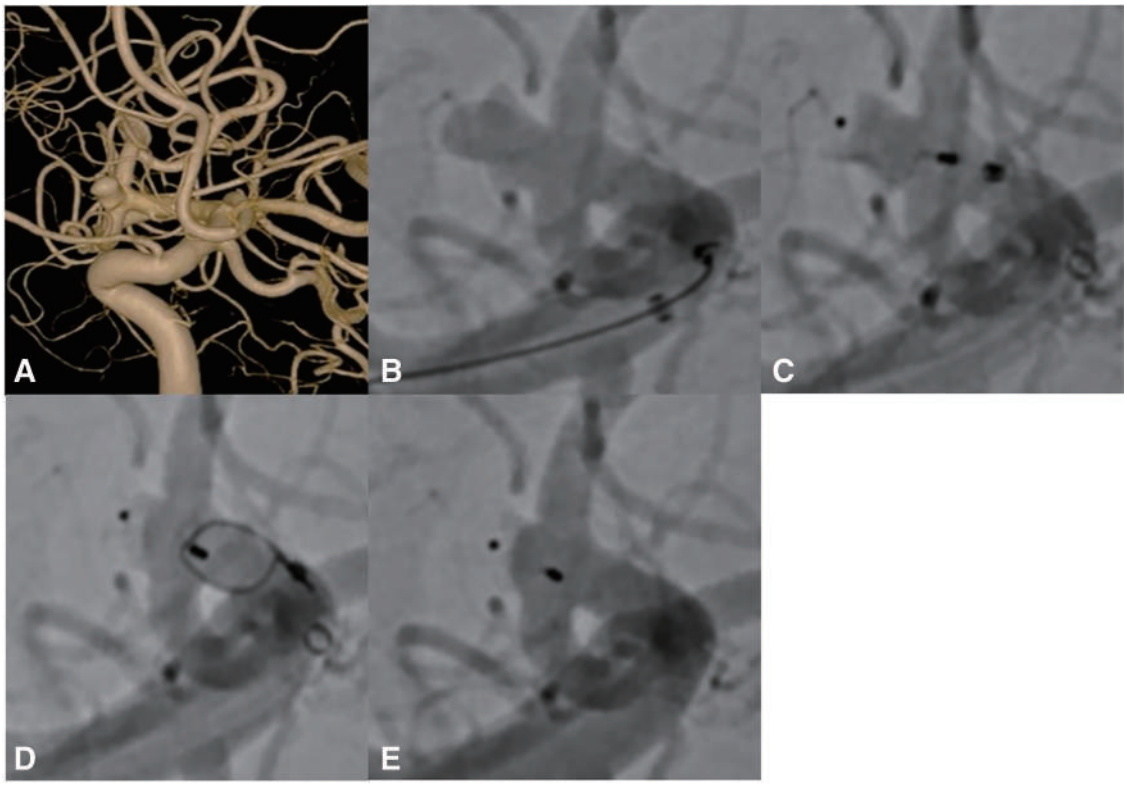

Fig. 1 (**A**) Unruptured right MCA aneurysm (maximum diameter 6.1 mm, height 4.5 mm, width 4.3 mm, neck 3.4 mm, dome-to-neck ratio 1.2). (**B**) Working angle. (**C**) After deploying the WEB SL 5 × 4 (MicroVention TERUMO, Tustin, CA, USA) into the aneurysm, we confirmed its appropriate positioning using DSA. (**D**) However, the WEB fully deviated into the MCA bifurcation upon detachment; therefore, it was retrieved using a Goose Neck Microsnare (Medtronic, Minneapolis, MN, USA). (**E**) Finally, another WEB was placed. MCA, middle cerebral artery; WEB, Woven EndoBridge

studies have reported its safety and acceptable mid- to long-term treatment outcomes as a device for treating WNBAs.[3–8] We have experienced 120 cases of cerebral aneurysms treated using a WEB device between January 2021 and March 2024. Treatment with WEB was achieved in 117 cases (98%) and adjunctive stenting was used in 12 cases (10%), which is consistent with previous reports[3,4,6,7]. However, among these cases, there were 3 (2.5%) in which the WEB device protruded into or migrated to the parent vessel during or after detachment, necessitating retrieval. Migration refers to the displacement of the WEB from its proper position within the aneurysm into the parent vessel. Protrusion refers to the WEB, placed within the aneurysm, protruding into the parent vessel. We report 3 such cases and discuss the factors contributing to these occurrences, as well as tips and pitfalls of the retrieval techniques, along with a review of the literature. The research within our submission has been approved by the ethics institutional review board of Fujita Health University (HM22-128).

Case Presentation

Case 1 (Supplementary video, Fig. 1)

A 58-year-old man underwent WEB treatment for an unruptured right middle cerebral artery (MCA) aneurysm (maximum diameter 6.1 mm, height 4.5 mm, width 4.3 mm, neck 3.4 mm, dome/neck ratio 1.2). Aspirin 100 mg and clopidogrel 75 mg were started as preoperative medications 2 weeks before the treatment. Under general anesthesia, after placing a sheath introducer (Glidesheath Slender 7F, 10 cm, 16 cm; MicroVention TERUMO) via the right distal radial artery, a guiding catheter (7F Roadmaster 90 cm; NIPRO, Osaka, Japan) was advanced to the right internal carotid artery (ICA). Subsequently, using Vecta46 (Stryker, Kalamazoo, MI, USA) as the intermediate catheter, we guided VIA21 (MicroVention TERUMO) into the aneurysm following the advancement of Synchro Select Standard 215 cm (Stryker). After deploying the WEB SL 5 × 4 into the aneurysm and confirming its appropriate positioning by digital subtraction angiography

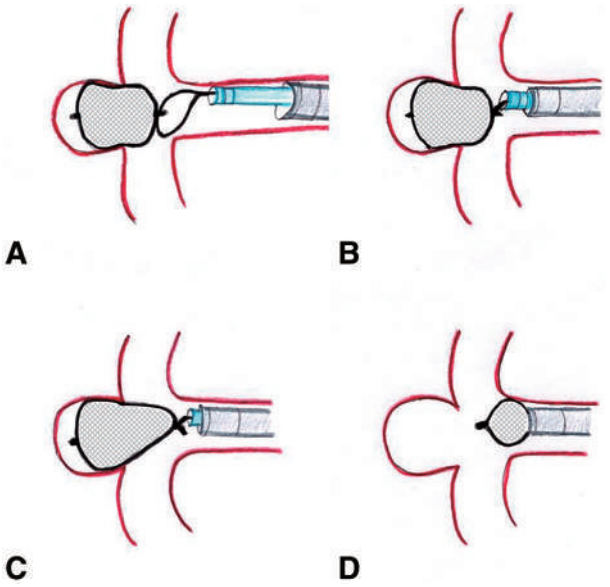

Fig. 2 Illustrated explanation of procedure in Case 1. (**A**) The proximal marker of the WEB (MicroVention TERUMO, Tustin, CA, USA) was oriented in a direction that allowed the Amplatz Goose Neck Microsnare (Medtronic, Minneapolis, MN, USA) to secure it successfully. The Amplatz Goose Neck Microsnare was then navigated from the VIA21 (MicroVention TERUMO), which was used for WEB deployment. (**B**) After securing the WEB with the GooseNeck Microsnare, (**C**) by advancing the intermediate catheter as far as possible toward the proximal end of the WEB while retrieving, (**D**) the WEB was retrieved into the intermediate catheter. WEB, Woven EndoBridge

(DSA), we tried to detach the WEB, but it resulted in sticky detachment, and we could not detach it. While pressing VIA21 against the WEB and applying slight backward tension to the delivery wire to attempt detachment, the WEB dislocated back into the parent vessel upon detachment. It fully deviated into the MCA bifurcation; therefore, we decided to retrieve the WEB. VIA21, which guided the WEB, was positioned proximal to the proximal marker of the WEB. We guided an Amplatz Goose Neck Microsnare (4 mm 175 cm; Medtronic, Minneapolis, MN, USA) and deployed the snare via VIA21. The proximal marker of the WEB was captured and grasped by carefully narrowing the snare loop. After positioning Vecta46 nearby, we retracted WEB and VIA21 into Vecta46 for retrieval. After performing DSA and confirming that there were no changes in the condition of the aneurysm and no vascular damage to the parent vessel or its branches, we performed another WEB and concluded the procedure. The patient was discharged postoperatively without any new neurological abnormalities. Explanation of the procedure is illustrated in **Fig. 2**.

Case 2 (Fig. 3)

A 51-year-old woman underwent WEB treatment for an unruptured left MCA aneurysm (maximum diameter 4.2 mm, height 3.3 mm, width 4.1 mm, neck 4.2 mm, dome/neck ratio 1.0). Aspirin 100 mg and clopidogrel 75 mg were started as preoperative medications 2 weeks before the treatment. Under general anesthesia, a guiding catheter (8F Roadmaster 80 cm; NIPRO) was placed in the left ICA via the right femoral approach. Utilizing 5F SOFIASELECT 125 cm (MicroVention TERUMO) as the intermediate catheter, we guided VIA21 into the aneurysm following the advancement of Synchro Select Standard 215 cm. After deploying the WEB SL 5 × 3 into the aneurysm and confirming its appropriate positioning via DSA, the WEB was detached. However, upon detachment, the WEB tilted, with a portion of its proximal side protruding into the superior MCA trunk. Owing to concerns regarding occlusion and thrombosis risk, we decided to attempt adjunctive stenting from the M2 superior trunk to the distal M1. Using a 5F SOFIASELECT, we tried to guide the Excelsior SL-10 (Stryker) and Synchro Select Standard into the M2 superior trunk. However, due to the sharp branching angle and the excessively dislodged WEB, we were unable to navigate SL-10 to M2. Therefore, we reluctantly decided to retrieve the WEB. We exchanged the Excelsior SL-10 with Headway 21 (MicroVention TERUMO) and, similar to Case 1, guided Headway 21 via 5F SOFIASELECT immediately before the WEB proximal marker. Using a Goose Neck Microsnare, we grasped the proximal marker and retrieved the WEB, and the WEB was then retrieved into the 5F SOFIASELECT. After performing DSA and confirming that there were no changes in the condition of the aneurysm and no vascular damage to the parent vessel or its branches, the WEB SL 4 × 3 was deployed into the aneurysm using the same method. The patient was discharged postoperatively without any new neurological abnormalities.

Case 3 (Fig. 4)

An 87-year-old woman presented to a local clinic with diplopia. Upon examination, a right internal carotid-posterior communicating artery (IC-PC) aneurysm was identified. Owing to the diagnosis of impending rupture, the patient was urgently transferred to our hospital. The aneurysm had a maximum diameter of 6.0 mm, a height of 4.4 mm, a width of 5.0 mm, a neck of 4.9 mm, and a dome/neck of 1.0, with a fetal-type posterior communicating artery (Pcom) originating from the wall of the aneurysm. The impending ruptured aneurysm was an urgent situation; thus, emergency treatment involving WEB deployment was devised. Aspirin 200 mg and clopidogrel 300 mg were administered as preoperative medications just before the

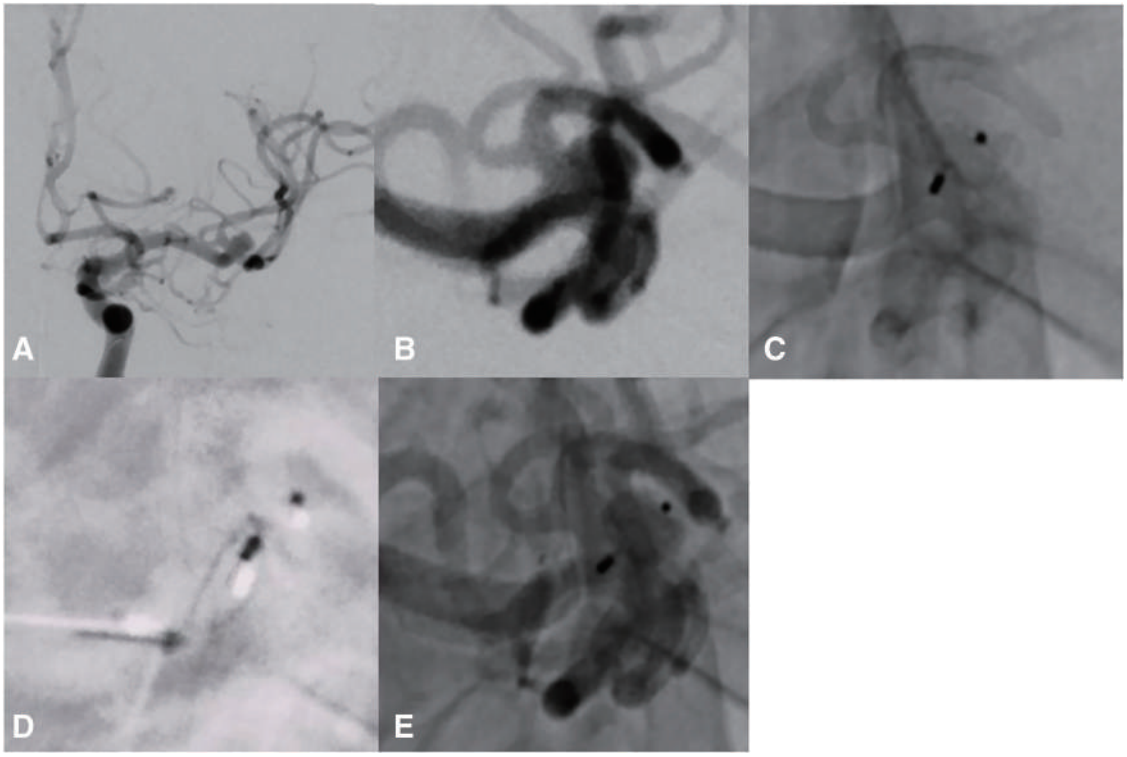

Fig. 3 (**A**) Unruptured Lt. MCA aneurysm (maximum diameter 4.2 mm, height 3.3 mm, width 4.1 mm, neck 4.2 mm, dome/neck ratio 1.0). (**B**) Working angle. (**C**) After deploying the WEB SL 5 × 4 (MicroVention TERUMO, Tustin, CA, USA) into the aneurysm, we confirmed its appropriate positioning using DSA. However, upon detachment, the WEB tilted, with a portion of its proximal side protruding into the superior MCA trunk. (**D**) Data were retrieved using a Goose Neck Microsnare (Medtronic, Minneapolis, MN, USA). (**E**) Finally, the WEB SL 4 × 3 was deployed into the aneurysm using the same method. Lt., light; MCA, middle cerebral artery; WEB, Woven EndoBridge

treatment. Under general anesthesia, a 6F FUBUKI guiding sheath (90 cm; Asahi Intecc Co., Ltd., Aichi, Japan) was placed in the left ICA via the right femoral approach. Subsequently, Vecta46 was advanced proximal to the Pcom as an intermediate catheter. The VIA21, shaped at 90° at its tip, was advanced into the aneurysm following the progression of the Synchro Select Standard 215 cm. Initially, a WEB SL 6 × 3 was placed; however, because of protrusion into the origin of the Pcom, it was downsized to a WEB SL 5 × 3 and deployed. After confirming the preservation of the Pcom and stasis of the contrast agent within the aneurysm, the WEB was detached. However, owing to sticky detachment, when attempting to retract it into the VIA, the WEB detached with dislocation, occluding the Pcom. Retrieval was performed using the same devices and methods as those used in the previous 2 cases. After performing DSA and confirming that there were no changes in the condition of the aneurysm and no vascular damage to the parent vessel or its branches, treatment was switched to balloon-assisted coil embolization. No new neurological abnormalities were observed after surgery.

Discussion

The frequency and factors contributing to WEB protrusion/migration

Previous studies have reported that the completion rate of WEB deployment in cases with intended placement is between 94.1% and 98.7%.[3–7] However, technical events such as detachment system failure due to WEB sticky detachment or difficulty in delivery due to a kinked pusher, including instances of the delivery pusher breaking, occur at a rate of 8.1%–15.7%.[3,4] The occurrence of WEB protrusions is between 10.4% and 15%.[3,8] Regarding the cases at our institution, sticky detachment was considered the cause in Cases 1 and 3, whereas tilting due to sizing failure of the WEB was thought to be the cause in Case 2. In these cases, management options include antiplatelet therapy to mitigate the risk of thrombosis, and additional interventions such as stent placement are also commonly performed.[8] Generally, when an improperly positioned WEB is encountered, it should be retrieved without detachment. However, owing to certain factors, there may be instances

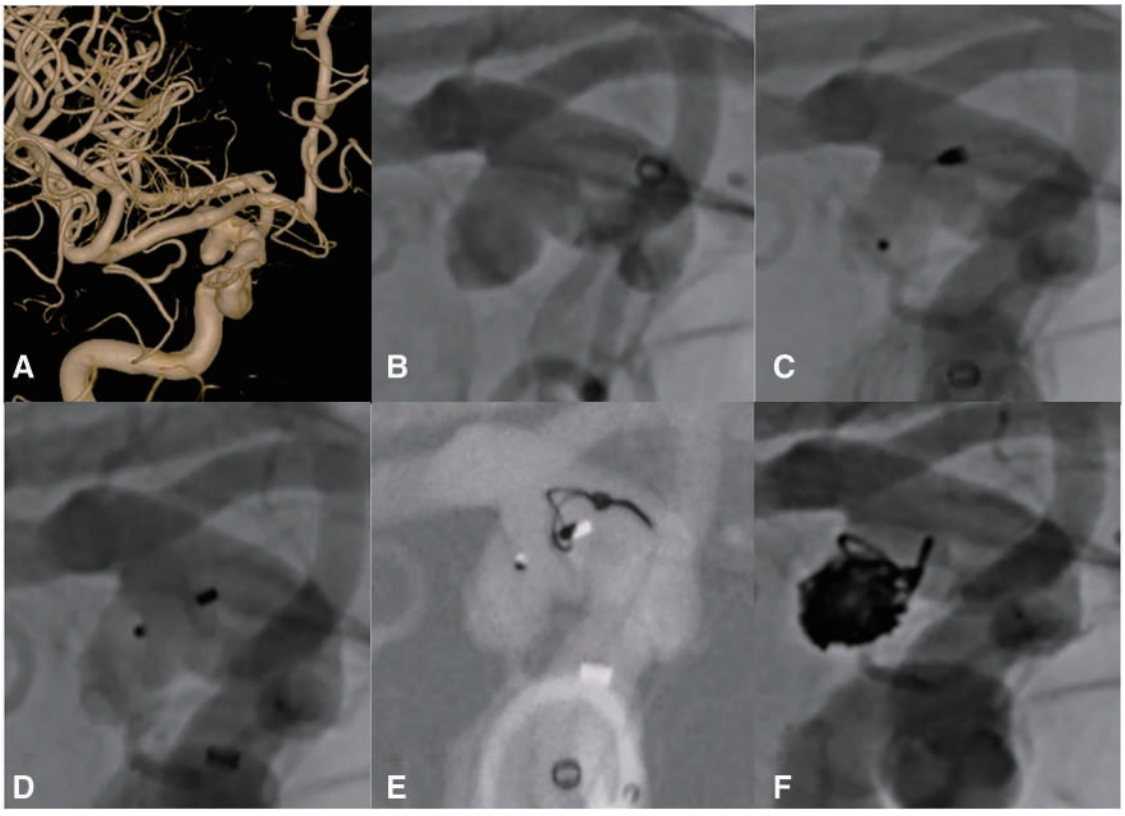

Fig. 4 (**A**) Impending ruptured right internal carotid-posterior communicating artery aneurysm (maximum diameter 6.0 mm, height 4,4 mm, width 5.0 mm, neck 4.9 mm, dome-to-neck ratio 1.0). (**B**) Working angle. (**C**) After confirming the preservation of the Pcom and stasis of the contrast agent within the aneurysm, the WEB SL 5×3 (MicroVention TERUMO, Tustin, CA, USA) was detached. (**D**) However, owing to sticky detachment, when attempting to retract it into the VIA (MicroVention TERUMO), the WEB SL 5×3 detached with dislocation, occluding the Pcom. (**E**) Retrieval was performed using the same devices and methods as in the previous 2 cases. (**F**) The final treatment was switched to balloon-assisted coil embolization. Pcom, posterior communicating artery; WEB, Woven EndoBridge

in which improper positioning occurs after detachment, as in our cases, and retrieval of the detached WEB becomes necessary. Reports on WEB retrieval are scarce, with only 15 cases, including our 3, found to be the best of our search capabilities (**Table 1**).[9–14] WEB migration into the parent vessel is thought to occur because of a combination of factors. Abdelrady et al.[11] reported a case in which WEB migration occurred during the treatment of an unruptured intracranial aneurysm associated with an arteriovenous malformation (AVM), suggesting that this may have been caused by a high-flow lesion associated with the AVM. König et al.[9] reported a case of WEB migration during microcatheter retrieval after WEB deployment for an unruptured intracranial aneurysm, suggesting the possibility of interlocking between the microcatheter and WEB. Additionally, other reports on the causes of WEB migration include inadequate apposition to the aneurysm wall during deployment, inadvertent manipulation of the delivery pusher in a state of incomplete detachment, treatment of small-caliber aneurysms, and inappropriate size selection.[10,12,13]

Tips and pitfalls of microsnare retrieval in WEB (Table 2)

An Amplatz Goose Neck Microsnare (4 mm × 175 cm) was used in all cases of WEB retrieval performed at our institution. The Amplatz Goose Neck Microsnare, 175 cm in diameter, had loop diameters of 2, 4, and 7 mm. It features a 90° snare loop deployment angle relative to the catheter and is compatible with a 0.021-inch inner lumen microcatheter for navigation (**Fig. 5**).

In all cases, the proximal marker of the WEB was oriented in the direction attainable to secure the Amplatz Goose Neck Microsnare. In Cases 1 and 3, upon confirming WEB migration, immediate extraction was performed, and the Amplatz Goose Neck Microsnare was successfully navigated from the VIA21 used for WEB deployment to retrieve the WEB. Because thrombus formation within

Table 1

Author	Date	AN (width/ neck/height)	WEB	Lesion	Retrieval device	Complication
König et al.[9]	2019	2.9/–/3.2	WEB SLS 4	Rt. IC top AN → Rt. MCA bifurcation	Alligator Retrieval	No deficit
Radu et al.[10]	2022	3.26/–/3.27	WEB SL 3/2	BA top AN → Rt.P1	1st Embotrap 5 × 37 failed 2nd Solitaire 4 × 20 failed 3rd GooseNeck Microsnare 4 mm	No vessel injury
Abdelrady et al.[11]	2022	3.6/–/4.2	WEB SL 5–4×2	BA-SCA AN → Lt. PCA	Solitaire Platinum 4 × 20 + 6F sofia intermediate catheter	Uneventful and discharge
Bañez et al.[12]	2022	5/–/3	WEB SL 5×2	BA top AN → BA	Solitaire Platinum 4 × 20 + 6F sofia intermediate catheter	No vessel injury
Santhumayor et al.[13]	2023	4.7/3.7/3.4	WEB SL 5×2	BA tip AN → BA	GooseNeck Microsnare 4 mm	No vessel injury
		5.1/4.6/4.8	WEB SL 4×3	Acom AN → Lt. A2	1st LVIS jr 2.5 mm failed 2nd GooseNeck Micorsnare 2 mm	–
Chew et al.[14]	2024	3.5/–/3.1	WEB SL 4.5×2	Acom → Pericallosal A	GooseNeck Microsnare 2 mm	No vessel injury
		2/–/3.1	WEB SL 3×2	Lt. ICPcom → Lt. MCA	GooseNeck Microsnare 4 mm	No vessel injury
		4.8/–/3.1	WEB SL 5×3	Acom (protrusion)	GooseNeck Microsnare 2 mm	No vessel injury
		3.3/–/5.7	WEB SL 5×2	Lt. P1/P2 (malposition)	GooseNeck Microsnare 2 mm	No vessel injury
		9.1/–/8	WEB SLS 9	Lt. IC-PC (protrusion)	GooseNeck Microsnare 4 mm	No vessel injury
		3.3/–/4.3	WEB SL 4 × 3	Rt. MCA (protrusion)	GooseNeck Microsnare 4 mm	Clot formation

Acom, anterior communicating artery; Alligator Retrieval, Medtronic, Minneapolis, MN, USA; AN, aneurysm; BA, basiler artery; Embotrap, Johnson & Johnson Medical, Irvine, CA, USA; Goose Neck Microsnare, Medtronic; IC, internal carotid artery; IC-PC, internal carotid-posterior communicating artery; Lt., light; LVIS jr, MicroVention TERUMO, Tustin, CA, USA; MCA, middle cerebral artery; Pcom, posterior communicating artery; Rt., right; Solitaire Platinum, Medtronic; WEB, Woven EndoBridge, MicroVention TERUMO

Table 2

Case	AN (width/height)	WEB	Lesion	Retrieval device	Complication
Case 1	4.0/5.0	WEB SL 5 × 4	Rt. MCA migration*	GooseNeck Microsnare 4 mm + Vecta46	No
Case 2	4.6/3	WEB SL 5 × 3	Lt. MCA bifurcation protrusion**	GooseNeck Microsnare 4 mm + 5F SOFIA	No
Case 3	4.9/3.9	WEB SL 5 × 3	Rt. IC-PC migration	GooseNeck Microsnare 4 mm + Vecta46	No

*Migration refers to the displacement of the WEB from its proper position within the aneurysm into the parent vessel.
**Protrusion refers to the WEB, placed within the aneurysm, protruding into the parent vessel.
AN, aneurysm; Goose Neck Microsnare, Medtronic, Minneapolis, MN, USA; IC-PC, internal carotid-posterior communicating artery; Lt., light; MCA, middle cerebral artery; Rt., right; SOFIA, MicroVention TERUMO, Tustin, CA, USA; Vecta46, Stryker, Kalamazoo, MI, USA; WEB, Woven EndoBridge, MicroVention TERUMO

the WEB is promoted upon deployment, early extraction upon determination of necessity is preferable. The ability to navigate the Amplatz Goose Neck Microsnare from the microcatheter used to deploy the WEB is a significant advantage. Furthermore, after securing the WEB with the GooseNeck Microsnare, by advancing the intermediate catheter as far as possible toward the proximal end of the WEB while retrieving, we were able to reduce the risk of vascular endothelial damage during the retrieval procedure. In all 3 cases, a WEB SL with a width of 5 mm and a height of 4 mm or less was used. Although there were concerns about potential WEB stagnation, it was retrieved without any issues into the 5F SOFIA (inner lumen: 1.4 mm/outer diameter: 1.47 mm) and Vecta46 (inner lumen: 1.17 mm). There was another concern regarding damage to the aneurysm wall caused by the WEB during retrieval,



Fig. 5 Amplatz GooseNeck Microsnare 175 cm 4 mm (Medtronic, Minneapolis, MN, USA)

as it was fully deployed within the aneurysm. As the WEB was drawn into Vecta46 from its fully deployed state, the lateral expansion was initially released. Subsequently, as the retrieval progresses, the width of the WEB contracts and the tip of the WEB moves proximally. When the lateral expansion is released, the tip of the WEB becomes extremely flexible, and the WEB is pulled outward from the aneurysm. Therefore, perforation is considered unlikely even if the WEB is in slight contact with the aneurysm wall.

Limitations

In our experience, all the cases involved a WEB with a width of 5 mm. Clinical cases regarding the feasibility of retrieval with WEBs of other sizes or in combination with other intermediate catheters have not yet been experienced. Furthermore, although not detailed in this manuscript, in model experiments conducted under dry-field conditions, WEBs with widths up to 7 mm, suitable for use with a 5F intermediate catheter, and WEBs with widths ranging from 8 to 11 mm, suitable for use with a 6F intermediate catheter, were found to be retractable into the intermediate catheter. When using a Goose Neck Microsnare, it is necessary to ensure the availability of the proximal markers. If access to a proximal marker is difficult, alternative methods should be considered. Previous reports on WEB retrieval have also documented the use of devices other than the Amplazt GooseNeck Microsnare, including the Solitaire Platinum Revascularization Device (Medtronic) and Alligator Retrieval Device (Medtronic). Additionally, reports from experiments using a porcine model have indicated the effectiveness of aspiration catheters in addition to the devices mentioned above.[15,16] Securing the parent vessel on the distal side of the WEB is necessary for Stent Retrieval and is considered challenging when the WEB remains within the aneurysm sac. With the Alligator, there is a concern that pushing during WEB capture may further distally push the WEB. It is not possible to determine which method is superior. However, it is necessary to consider an appropriate extraction method for each case.

Conclusion

WEB protrusion and migration are rare occurrences, but it is important to be aware of the potential situations that could arise to secure a WEB safely. If a situation arises where retrieval of a detached WEB becomes necessary, it is crucial to promptly address the risk of thrombosis, and being aware of the GooseNeck Microsnare as a method can be useful.

Disclosure Statement

Ichiro Nakahara has received honoraria as a technical advisor, lecturer, and proctor for Terumo Corporation. The other authors have no conflicts of interest.

Supplementary Information

Supplementary video

This video is an edited movie about the endovascular surgery of Case 1.

References

1) Goyal N, Hoit D, DiNitto J, et al. How to WEB: a practical review of methodology for the use of the Woven EndoBridge. *J Neurointerv Surg* 2020; 12: 512–520.
2) De Leacy RA, Fargen KM, Mascitelli JR, et al. Wide-neck bifurcation aneurysms of the middle cerebral artery and basilar apex treated by endovascular techniques: a multicentre, core lab adjudicated study evaluating safety and durability of occlusion (BRANCH). *J Neurointerv Surg* 2019; 11: 31–36.
3) Pierot L, Costalat V, Moret J, et al. Safety and efficacy of aneurysm treatment with WEB: results of the WEBCAST study. *J Neurosurg* 2016; 124: 1250–1256.
4) Fiorella D, Molyneux A, Coon A, et al. Demographic, procedural and 30-day safety results from the WEB intra-saccular therapy study (WEB-IT). *J Neurointerv Surg* 2017; 9: 1191–1196.
5) Fiorella D, Molyneux A, Coon A, et al. Safety and effectiveness of the Woven EndoBridge (WEB) system for the treatment of wide necked bifurcation aneurysms: final 5

year results of the pivotal WEB intra-saccular therapy study (WEB-IT). *J Neurointerv Surg* 2023; 15: 1175–1180.
6) Pierot L, Gubucz I, Buhk JH, et al. Safety and efficacy of aneurysm treatment with the WEB: results of the WEBCAST 2 study. *AJNR Am J Neuroradiol* 2017; 38: 1151–1155.
7) Pierot L, Moret J, Turjman F, et al. WEB treatment of intracranial aneurysms: feasibility, complications, and 1-month safety results with the WEB DL and WEB SL/SLS in the French Observatory. *AJNR Am J Neuroradiol* 2015; 36: 922–927.
8) Caroff J, Mihalea C, Klisch J, et al. Single-layer WEBs: intrasaccular flow disrupters for aneurysm treatment-feasibility results from a European study. *AJNR Am J Neuroradiol* 2015; 36: 1942–1946.
9) König I, Weber A, Weber W, et al. Dislocation of a WEB device into the middle cerebral artery: removal with the alligator retrieval device. *Clin Neuroradiol* 2019; 29: 361–364.
10) Radu RA, Gascou G, Derraz I, et al. Micro-snare retrieval as bail-out technique for a distally migrated WEB-device: a case report. *Interv Neuroradiol* 2022 Aug 4. 2022. doi.org/10.1177/15910199221118709. [Epub ahead of print].
11) Abdelrady M, Dargazanli C, Derraz I, et al. Successful WEBectomy during embolization of temporal arteriovenous malformation-associated flow-related basilar aneurysms. *Interv Neuroradiol* 2022; 28: 644–649.
12) Bañez RMF, Chong W. Retrieval of displaced Woven EndoBridge intrasaccular flow disruptor using Solitaire Platinum revascularization device. *Neurointervention* 2022; 17: 106–109.
13) Santhumayor BA, White TG, Werner C, et al. Woven EndoBridge device migration and microsnare retrieval strategy: single institutional case reports with technical video demonstration. *Neurointervention* 2023; 18: 129–134.
14) Chew HS, Altibi M, Al-Ali S, et al. Microsnare retrieval as a bail-out technique of detached Woven EndoBridge device: illustrative series. *Interv Neuroradiol* 2024 Apr 5. 2024. doi.org/10.1177/15910199241242170. [Epub ahead of print].
15) Simgen A, Yilmaz U, Dietrich P, et al. Rescue of migrated Woven Endobridge devices using a stent-retriever-technique in a porcine model. *Interv Neuroradiol* 2020; 26: 772–778.
16) Simgen A, Kettner M, Dietrich P, et al. Different rescue approaches of migrated Woven Endobridge (WEB) devices: an animal study. *Clin Neuroradiol* 2021; 31: 431–438.