Sponsored By Covidien

Clinical Versatility of the Concerto™ Detachable Coils in Peripheral Embolization

Applications and advantages of this unique system.

BY RIPAL T. GANDHI, MD, FSVM, AND REHAN MALIK, MD

Since the introduction of coils in the 1970s, the advent of embolotherapy has revolutionized nonsurgical treatment of both cerebral and peripheral vascular diseases. Although a range of materials is currently being used for embolization (including gelfoam, liquid agents, and particles), coils have proven to be strikingly effective for the treatment of hemorrhage,[1] aneurysms,[2] and a multitude of diverse vascular pathologies, including malignancies, vascular malformations, arteriovenous fistulas, pelvic congestion syndrome, and varicoceles.[3]

Traditional pushable coils have several limitations, including coil stretching, a limited range of available coil lengths, and difficulty in precise deployment with potential adverse repercussions of incomplete occlusion, revascularization, and nontarget embolization. Because of these shortcomings, pushable coils are being replaced with detachable coils, which not only offer better coil control and stability, but also a clean, precise, and instant deployment. The unique Concerto™ platinum-based detachable coil system designed by Covidien (Figure 1) has a handheld Instant Detacher for fast, accurate, and efficient coil deployment. Additional benefits of this detachable coil include reliability in achieving vascular occlusion, trackability, a wide range of sizes and lengths (Table 1), and ease of use. Finally, Concerto™ coils have remarkable softness and excellent distal performance, which enables easy loop formation. They can be repositioned and accurately deployed.

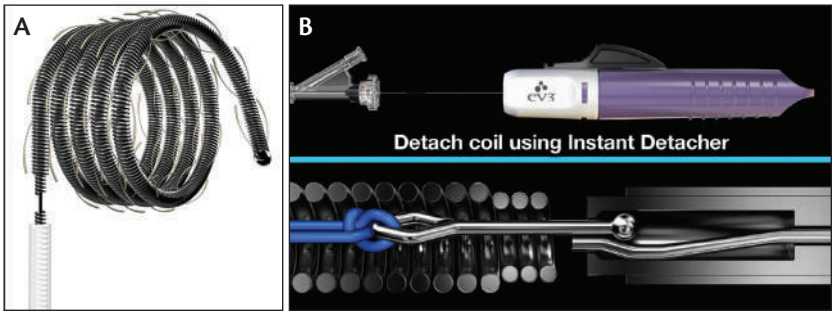

Figure 1. The Concerto™ detachable coil system (A) and the Instant Detacher (B) used to deploy the coil. Reprinted with permission of Covidien.

TABLE 1. AVAILABLE CONCERTO™ SIZES

Order Number	Description	Diameter (mm)	Length (cm)	Shape	Type	Minimum Microcatheter Compatibility (in)
NV-2-4-Helix	Concerto™ nylon helical	2	4	Helix	Fibered	0.0165"
NV-2-6-Helix	Concerto™ nylon helical	2	6	Helix	Fibered	0.0165"
NV-2-8-Helix	Concerto™ nylon helical	2	8	Helix	Fibered	0.0165"
NV-3-4-Helix	Concerto™ nylon helical	3	4	Helix	Fibered	0.0165"
NV-3-8-Helix	Concerto™ nylon helical	3	8	Helix	Fibered	0.0165"
NV-4-8-Helix	Concerto™ nylon helical	4	8	Helix	Fibered	0.0165"
NV-4-10-Helix	Concerto™ nylon helical	4	10	Helix	Fibered	0.0165"
NV-5-15-Helix	Concerto™ nylon helical	5	15	Helix	Fibered	0.021"
NV-5-20-Helix	Concerto™ nylon helical	5	20	Helix	Fibered	0.021"
NV-6-20-Helix	Concerto™ nylon helical	6	20	Helix	Fibered	0.021"
NV-7-30-Helix	Concerto™ nylon helical	7	30	Helix	Fibered	0.021"
NV-8-30-Helix	Concerto™ nylon helical	8	30	Helix	Fibered	0.021"
NV-9-30-Helix	Concerto™ nylon helical	9	30	Helix	Fibered	0.021"
NV-10-30-Helix	Concerto™ nylon helical	10	30	Helix	Fibered	0.021"
PV-12-30-Helix	Concerto™ PGLA helical	12	30	Helix	Fibered	0.021"
PV-14-30-Helix	Concerto™ PGLA helical	14	30	Helix	Fibered	0.021"
PV-16-40-Helix	Concerto™ PGLA helical	16	40	Helix	Fibered	0.021"
PV-18-40-Helix	Concerto™ PGLA helical	18	40	Helix	Fibered	0.021"
PV-20-50-Helix	Concerto™ PGLA helical	20	50	Helix	Fibered	0.021"

(Courtesy of Covidien.)

TECHNICAL DETAILS AND BENEFITS

The Concerto™ detachable coils are indicated for arterial and venous embolizations in the peripheral vasculature.

Sponsored By Covidien

CASE 1

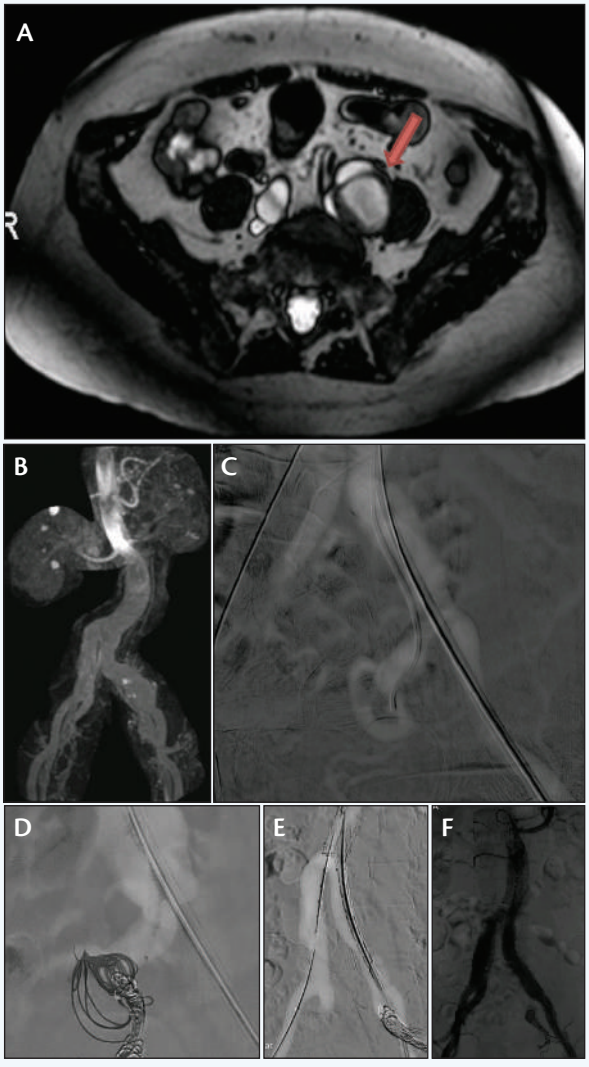

A 59-year-old woman with chronic renal insufficiency and chronic dissection of the distal aorta and iliac arteries presented with an enlarging left common iliac artery aneurysm measuring 4.2 cm (A). Please note that the dissection is not well visualized on the magnetic resonance angiography maximum-intensity projection images (B). Using CO_2 angiography, the left hypogastric artery was selected via the brachial artery approach (C). Multiple Concerto™ coils were successfully deployed in the left hypogastric artery to prevent retrograde blood flow into the left common iliac artery aneurysm sac (D). Subsequent CO_2 angiography during Endurant® II (Medtronic, Inc.) aortic stent graft placement demonstrates occlusion of the left hypogastric artery after coil embolization (E). Final aortogram after EVAR shows occlusion of the left common iliac artery and no retrograde flow through the embolized left hypogastric artery (F).

CASE 2

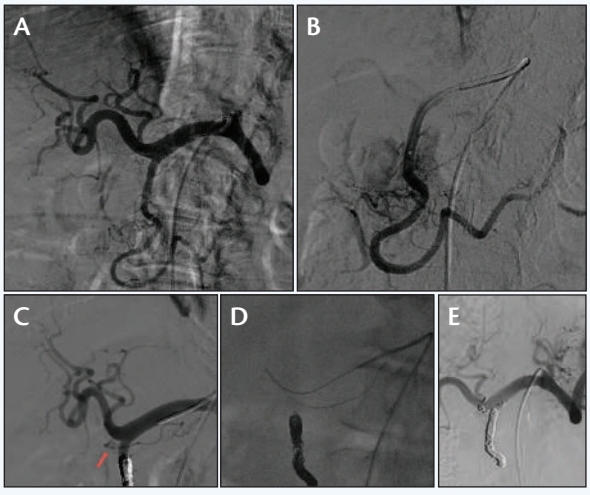

A 75-year-old woman with esophageal cancer metastasized to the liver presented for a mapping procedure before yttrium-90 radioembolization. Celiac angiography (A) and subsequent selective gastroduodenal artery (GDA) selection (B) showed a typical GDA. After partial embolization of the GDA with Concerto™ coils, the right gastric artery is better seen (C). After embolization to the origin of the GDA, the right gastric artery was catheterized and embolized (D). The postembolization celiac angiogram showed successful occlusion of the GDA and right gastric artery with Concerto™ coils (E). The ability to reposition the Concerto™ coils allowed successful coil embolization to the origin of the GDA.

The system's LatticeFX™ technology or scaffolding orients cell adhesion and extracellular deposition, enabling early homeostasis with reduced flow across the neck of aneurysms.[4,5] The nylon and PGLA fibers enlaced into the coils enhance thrombin generation, which results in a much higher occlusion rate, and the risk of thromboembolic events is kept to a minimum.[6] These second-generation, filament-containing coils provide higher flow resistance (reduced cross-neck flow velocity) imparted by the distribution of filament in the vessel,[7] potentially decreasing the time to achieve vascular occlusion. An in vitro study showed that the addition of nylon and PGLA filaments to bare platinum coils increases the thrombogenicity of the coil.[8] The clinical importance of the latter finding is underscored by studies that have shown that bare platinum coils' failure rates are not insignificant. For example, Kuo et al demonstrated a 14% rebleeding rate after superselective embolization for the treatment of lower gastrointestinal hemorrhage,[9] and Deshaies et al found a 33% aneurysm recurrence rate at 1 year after treatment with bare platinum coils.[10]

The Concerto™ detachable coil system can be carefully placed and remain attached until the coil configura-

Sponsored By Covidien

The ability to reliably place and reposition the coils provides immense benefits in clinical practice, especially when dealing with high-flow vascular beds and precarious anatomy.

tion and secure positioning are acceptable, minimizing the risk of coil migration and nontarget embolization. These coils have robust double polypropylene strands that confer superior stretch resistance, which not only enables responsive placement and repositioning, but also minimizes coil stretching even during extensive repositioning. Furthermore, there is no time limit on coil placement. The system's freely rotating ball-and-socket mechanism with a unique floating eyelet enables an instant detachment of the coil, allowing its full deployment in a desired location before release. The ability to reliably place and reposition the coils provides immense benefits in clinical practice, especially when dealing with high-flow vascular beds and precarious anatomy.

These coils are typically delivered through 0.021-inch microcatheters, although we have delivered them through high-flow microcatheters ranging in inner diameter from 0.025 to 0.027 inches (Table 1). The 2- to 4-mm coils can be delivered through microcatheters as small as 0.0165 inches in inner diameter, allowing placement in smaller and tortuous vessels that cannot be accessed and navigated with larger microcatheters. In performing mapping and embolization procedures in preparation for yttrium-90 radioembolization, small right gastric arteries at times can be catheterized only with 0.0165-inch microcatheters, because larger microcatheters will not track into these vessels. In this scenario, the 2- to 4-mm Concerto™ coils are an excellent option and provide significant cost savings compared with much more expensive neuro detachable coils that are compatible with these small microcatheters. Other detachable coils approved for the periphery are not compatible with 0.0165-inch microcatheters.

Nonclinical testing has demonstrated that these coils are magnetic resonance conditional and can be scanned safely.

COIL PACKING DENSITY

Coil packing density has been a matter of great concern, considering the ultimate goal of providing effective and long-term occlusion.[11] A recent study demonstrated that

CASE 3

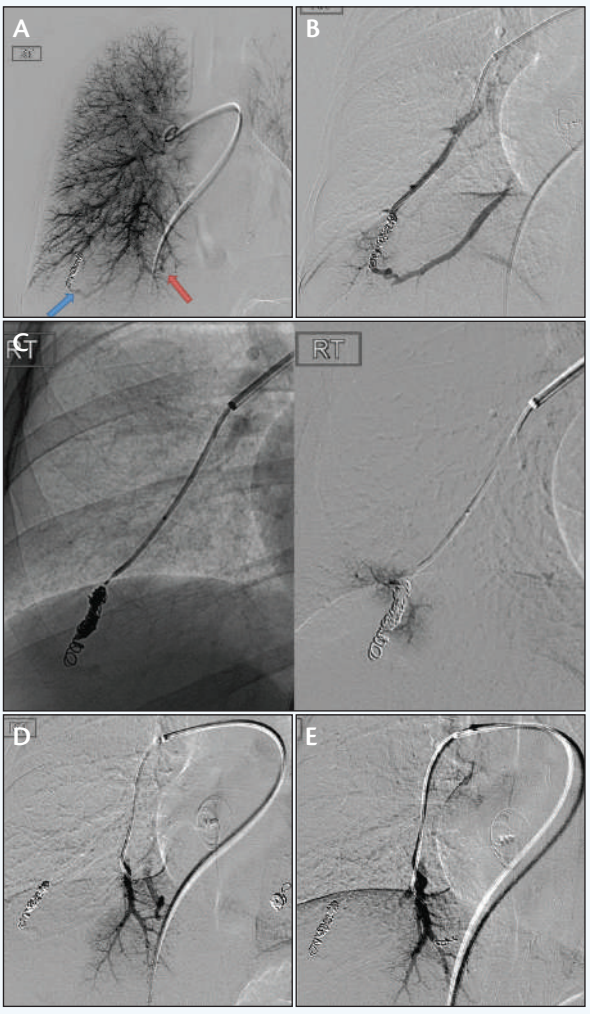

(Case courtesy of Kartik Kansagra and George Vatakencherry.)

A 37-year-old woman with Osler-Weber-Rendu syndrome had previously undergone embolization with pushable coils for pulmonary arteriovenous malformations (AVMs) in the right and left lower lobes. A follow-up chest CT scan (not shown) and subsequent pulmonary angiogram showed recanalization of the previously embolized right lower lobe pulmonary AVM (A, blue arrow) and a second AVM in the posterobasal right lower lobe (A, red arrow). A selective angiogram better showed the recanalized AVM in the right lower lobe (B). After embolization with 3- and 4-mm Concerto™ coils, there was complete occlusion of the AVM (C). Note the dense packing achieved with these coils. A selective angiogram of the posterior basal segmental pulmonary artery showed a second AVM with early filling of the pulmonary vein (D). After deployment of a single 4-mm Concerto™ coil, postembolization contrast injection showed complete occlusion of the AVM with preservation of flow to the branches feeding the posterior basal segment (E).

CASE 4

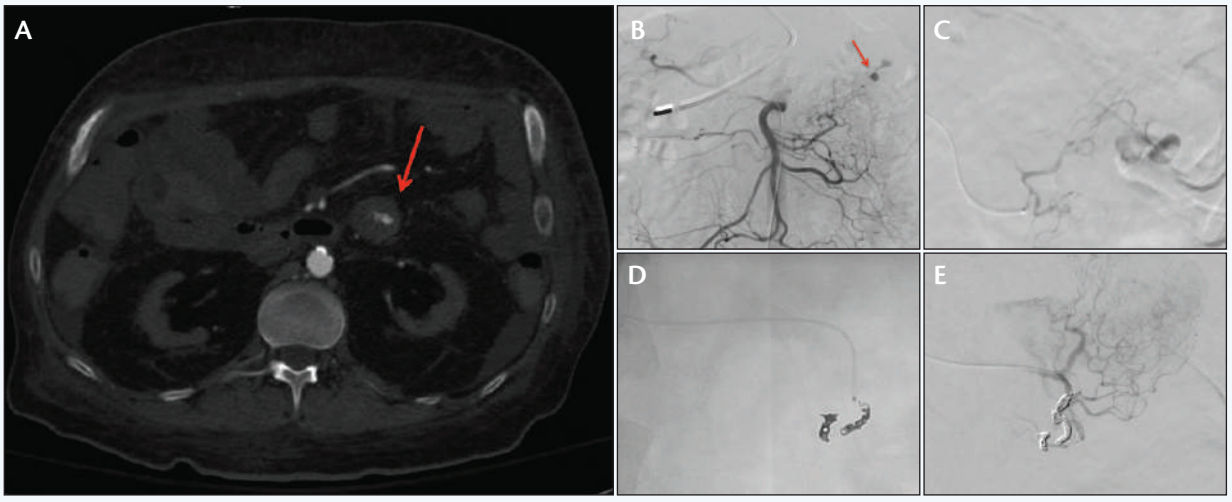

(Case courtesy of Paul Rochon.)

A 56-year-old man with a history of renal transplant and posttransplant lymphoproliferative disorder presented with hypotension and significant lower gastrointestinal hemorrhage. The patient's hemoglobin level was 4.7. A CT angiogram of the abdomen/pelvis showed intravenous contrast material in the lumen of the jejunum (A, red arrow). Superior mesenteric angiography (B) and subsequent selective angiogram (C) showed active extravasation in a jejunal arterial branch. Concerto™ coil embolization was performed with 2-, 4-, and 5-mm coils (D). The postembolization angiography showed resolution of contrast extravasation with preservation of blood flow to the adjacent jejunal arterial branches (E).

… benefits may include decreased fluoroscopy time, fewer complications, and fewer repeat interventions (due to recanalization), all of which may improve cost-effectiveness.

insufficient coil packing density within visceral aneurysms resulted in an increased incidence of coil compaction and recanalization.[12] There was no recanalization or compaction in aneurysms with a packing density of at least 24%, emphasizing the critical importance of adequately packing aneurysms with coils to achieve clinical success. The high packing density achieved by Concerto™ coils may be attributable to their remarkable softness and excellent distal performance, which enables easy loop formation, as well as the fact that they can be repositioned and accurately deployed.

CLINICAL APPLICATIONS

Concerto™ coils may be used for virtually any clinical application requiring embolization in the peripheral vasculature (both arterial and venous). Selected clinical cases presented here include the following:

- Hypogastric embolization before endovascular repair of a common iliac artery aneurysm in the setting of chronic dissection (Case 1).
- Yttrium-90 radioembolization mapping requiring occlusion of the GDA and right gastric artery (Case 2).
- Retreatment of a recanalized pulmonary AVM previously embolized with pushable coils, as well as treatment of a new pulmonary AVM (Case 3).
- Embolization of the jejunal branch of the superior mesenteric artery in a patient with massive lower gastrointestinal hemorrhage (Case 4).
- Treatment of an innominate artery pseudoaneurysm due to parathyroid surgery with a covered stent followed by coil embolization (Case 5).

COST-EFFECTIVENESS

There are not many studies specifically evaluating the cost-effectiveness of detachable coils versus pushable coils. Although detachable coils tend to be more expensive than conventional coils, Concerto™ coils may actually result in cost reduction if fewer coils are needed compared to bare platinum coils due to increased thrombogenicity and longer lengths (up to 50 cm). Additional benefits may include decreased fluoroscopy time, fewer complications, and fewer repeat interventions (due to recanalization), all of which may improve cost-effectiveness. The latter is increasingly important

Sponsored By Covidien

CASE 5



An 81-year-old woman with a history of hyperparathyroidism status after minimally invasive parathyroidectomy and subsequent ministernotomy for repair of an innominate artery injured during the surgery presented with a new onset of syncopal episode. CT angiogram demonstrates a likely pseudoaneurysm arising from the repair site of the innominate artery, which was confirmed on angiography (A). Two 12-mm X 38-mm Atrium Medical iCast™ covered stents were placed into the innominate artery via the femoral approach, however, there was persistent flow into the pseudoaneurysm (B). The right brachial artery was then accessed, and an angiogram again demonstrates the pseudoaneurysm (C). The pseudoaneurysm was successfully catheterized with a microcatheter and two Concerto™ coils were deployed (16 mm X 50 cm and 6 mm X 30 cm). A subsequent angiogram showed persistent flow into the pseudoaneurysm (D). Two additional Concerto™ coils were placed into the pseudoaneurysm (E). The soft nature and repositionability of the Concerto™ coil allowed for a very tight coil packing without prolapse into the innominate artery. The final angiogram showed complete occlusion of the pseudoaneurysm without residual flow (F).

today with rising health care costs and the need for cost containment without diminishing quality of care.

CONCLUSION

The Concerto™ detachable coil system represents a significant advancement in embolotherapy with its ease of delivery, precise and controlled deployment, increased thrombogenicity compared to bare platinum coils, diverse microcatheter compatibility, wide range of sizes and lengths, and trackability. The ability to reposition the coil, as well as its soft nature, may eliminate coil migration and nontarget embolization and allow for increased packing density during treatment, which has been shown to decrease the incidence of coil compaction and recanalization. This will ultimately ameliorate patient care with diminished treatment failures and resultant cost savings. ■

Ripal T. Gandhi, MD, FSVM, is with Miami Cardiac and Vascular Institute in Miami, Florida. He has disclosed that he is on the advisory board for Covidien. Dr. Gandhi may be reached at gandhi@baptisthealth.net.

Rehan Malik, MD, is with Miami Cardiac and Vascular Institute in Miami, Florida. He has disclosed that he has no financial interests related to this article.

1. Nicholson AA, Ettles DF, Hartley JE. Transcatheter coil embolectomy: a safe and effective option for major colonic haemorrhage. Gut. 1998;43:79-84.
2. Gandras EJ, Greben CR, Putterman D, et al. Visceral arterial embolization. Endovasc Today. 2008;6:66-74.
3. White RI Jr. Interventional radiology: reflections and expectations. The 1985 Eugene P. Pendergrass new horizons lecture. Radiology. 1987;162:593-600.
4. Yuki I, Lee D, Murayama Y, et al. Thrombus organization and healing in an experimental aneurysm model. Part II. The effect of various types of bioactive bioabsorbable polymeric coils. J Neurosurg. 2007;107:109-120.
5. Bashur CA, Dahlgren LA, Goldstein AS. Effect of fiber diameter and orientation on fibroblast morphology and proliferation on electrospin poly (D,L-lactic-co-gycolic acid) meshes. Biomaterials. 2006;27:5681-5688.
6. Liebig T, Henkes H, Fischer S, et al. Fibered electrolytically detachable platinum coils used for the endovascular treatment of intracranial aneurysms. Initial experiences and mid-term results in 474 aneurysms. Interv Neuroradiol. 2004;10:5-26.
7. Babiker MH, Gonzalez LF, Albuquerque F, et al. An in vitro study of pulsatile fluid dynamics in intracranial aneurysm models treated with embolic coils and flow diverters. IEEE Trans Biomed Eng. 2013;60:1150-1159.
8. Girdhar G, Read M, Sohn J, et al. In-vitro thrombogenicity assessment of polymer filament modified and native platinum embolic coils. J Neurol Sci. 2014;339:97-101.
9. Kuo WT, Lee DE, Saad WE, et al. Superselective microcoil embolization for the treatment of lower gastrointestinal hemorrhage. J Vasc Interv Radiol. 2003;14:1503-1509.
10. Deshaies EM, Adamo MA, Boulos AS. A prospective single-center analysis of the safety and efficacy of the HydroCoil embolization system for the treatment of intracranial aneurysms. J Neurosurg. 2007;106:226-233.
11. Gaba RC, Ansari SA, Roy SS, et al. Embolization of intracranial aneurysms with hydrogel-coated coils versus inert platinum coils: effects on packing density, coil length and quantity, procedure performance, cost, length of hospital stay, and durability of therapy. Stroke. 2006;37:1443-1450.
12. Yasumoto T, Osuga K, Yamamoto H, et al. Long-term outcomes of coil packing for visceral aneurysms: correlation between packing density and incidence of coil compaction and recanalization. J Vasc Interv Radiol. 2013;24:1798-1807.