Original communication

Early outcomes of the Third-generation of ClosureFast radiofrequency ablation for great saphenous vein reflux

Domenico Baccellieri, Vincenzo Ardita, Nicola Galati, Claudia Anselmi, Benedetta Mangili, and Roberto Chiesa

Vascular Surgery, Vita-Salute University School of Medicine, San Raffaele Scientific Institute, Milan, Italy

Summary: *Background:* This study aimed to assess the safety of the third-generation ClosureFast catheter for radiofrequency ablation (RFA) in the treatment of great saphenous vein (GSV) reflux in patients presenting to a dedicated vein center. *Materials and methods:* All consecutive patients with incompetent GSV who underwent RFA between December 2023 and May 2024 were retrospectively analyzed. The primary study endpoints were technical success and postoperative complication rate at 30 days. Secondary study endpoints were freedom from GSV recanalization and recurrent varicose vein (RVV) rate over the follow-up. The improvement in symptoms (measured by the Venous Clinical Severity Score [VCSS]) was evaluated. *Results:* During the study period, 50 limbs were treated in 50 consecutive patients (mean age 55.8±13.4 years; 56% women; CEAP 2-4; VCSS >5). The technical success rate was achieved in 100% of cases. There was no significant incidence of 30-day complications. There were no instances of deep venous thrombosis or puncture site thermal injury. One patient (2%) had hyperpigmentation; two patients (4%) had ecchymosis; 4 patients (8%) had pain. At a mean follow-up of 2.9±1.4 months, GSV occlusion and freedom from reintervention rates were both 100% within 1 week and 30 days respectively. No patients had RVV over the follow-up. The VCSS score had decreased a median of 3.5 (IQR: 2.4–5) points from baseline ($p<0.01$). The mean CEAP class had decreased to 1.59 points from baseline, reflecting a shift towards milder disease categories (C0–C2). *Conclusions:* The third generation of RFA is safe and effective to ablate the GSV with a low complication rate in the perioperative period. However, durability over the follow-up and further studies with larger cohorts of patients are still needed to confirm these outcomes.

Keywords: varicose veins recurrence, radiofrequency thermal ablation, great saphenous vein, accessory saphenous vein

Introduction

Chronic venous disease (CVD) is a widespread condition that significantly impacts the quality of life, presenting with symptoms such as lower limb pain, swelling, varicose veins, skin changes, and, in more severe cases, venous ulcers [1]. In recent decades, numerous minimally invasive techniques have been developed for the treatment of chronic venous insufficiency, including both thermal and non-thermal ablation methods. Among these are endovenous laser ablation (EVLA), radiofrequency ablation (RFA), mechanochemical ablation (MOCA), foam sclerotherapy, and cyanoacrylate glue closure [2].

Radiofrequency ablation has been recognized as a safe and effective minimally invasive treatment option for patients with CVD secondary to great saphenous vein (GSV) reflux [3]. The first-generation Closure system (VNUS Medical Technologies) had limitations such as prolonged treatment times, a higher risk of side effects, and increased recurrence rates. Subsequently, the second-generation ClosureFast 7 Fr device addressed many of these limitations by providing better heat distribution control, reducing postoperative pain and complications, and achieving a higher success rate [4, 5, 6].

The introduction of the third-generation ClosureFast catheter has further refined the technology, offering advantages such as a reduced caliber (6 Fr instead of 7 Fr), an increased treatment length (8 cm instead of 7 cm), and greater flexibility, making it particularly suitable for treating tortuous saphenous veins.

This study aims to evaluate the efficacy and safety of the third-generation ClosureFast catheter in the treatment of great saphenous vein reflux, highlighting its potential advantages over existing treatment techniques.

© 2025 Hogrefe

https://doi.org/10.1024/0301-1526/a001195

Materials and methods

Study design

This single-center, retrospective, and non-randomized study included all consecutive patients who underwent RFA treatment between December 2023 and May 2024. The first next-generation probes available for the Italian market were used. All patients presented with CVD grades C1 to C6, as defined by the Clinical-Etiology-Anatomy-Pathophysiology (CEAP) classification and received RFA of the GSV using the third-generation ClosureFast™ catheter (VNUS®, Covidien, Dublin, Ireland) by the manufacturer's instructions [6]. This study followed the principles outlined in the Declaration of Helsinki and used only information obtained from the review of medical records. Patients gave consent for the anonymous collection of their data on the standard consent form provided by our institution. Ethical committee approval was waived according to Italian laws.

Preoperative evaluation

Collected data were derived from a prospectively maintained computerized database, and included details on preoperative, intraoperative, and postoperative information.

Clinical severity data were collected using CEAP classification [7]. Data on symptoms were collected using the Venous Clinical Severity Score (VCSS) [8].

Preoperatively, color duplex ultrasound (CDUS) was employed to evaluate GSV incompetence and the saphenous femoral junction (SFJ), with diameters of the GSV and the characteristics of outflow and reflux being estimated. This diameter was recorded 3 cm below the SFJ in the upright position, according to the International Union of Phlebology consensus document on duplex ultrasound [9]. The retrograde flow was identified at the SFJ, and three points along the thigh and/or leg, with reflux >0.5 seconds and GSV diameter >4 mm indicating eligibility for treatment [4]. The Valsalva technique was employed to measure and assess the degree of reflux in the thigh area. The compression technique was employed to determine the existence of superficial and/or deep reflux in the leg. The presence of an accessory saphenous vein (ASV) was identified as well.

Eligibility for RFA was determined based on clinical examination and CDUS guidelines as specified in international standards. Exclusion criteria included significant tortuosity, GSV diameter exceeding 20 mm, skin-to-GSV distance less than 0.5 cm, SFJ dilation greater than 2 cm, GSV duplication, history of deep vein thrombosis (DVT), pregnancy, active malignancy, symptomatic peripheral arterial disease, or severe systemic illness. Additionally, patients with incompetent small saphenous vein (SSV) or femoral vein were excluded from the procedure during preoperative evaluation [10].

Endpoint

The primary study endpoint were technical success and the 30-day postoperative complication.

The technical success of the device was defined as the successful delivery of the ablation catheter to the target vein from the access point and the effective deployment of radiofrequency energy along the entire length of the incompetent vein, resulting in complete ablation of the insufficient saphenous trunk.

The postoperative complication rate was assessed at 1 week and 30 days after the procedure. Complications included hyperpigmentation, pain, ecchymosis, paraesthesia, phlebitis, heat-induced thrombosis (EHIT), DVT, and pulmonary embolism (PE).

The secondary study endpoints were freedom from GSV recanalization and recurrent varicose vein (RVV) rate within 1 week and 30 days from intervention.

The freedom from GSV recanalization was defined as the lack of blood flow in an incompressible GSV tract from 3 cm distal to the SFJ along the entire length of the treated vein. Recanalization was characterized as the presence of blood flow in at least 5 cm of the targeted treated GSV segment, disregarding the presence/absence of reflux.

Recurrent varicose vein was defined as the reopening or persistence of varicose veins following the treatment, with or without phlebectomy or foam sclerotherapy, as reported in the ESVS guideline [10].

Moreover, the clinical outcomes were evaluated using the CEAP class and venous clinical severity score (VCSS) [7, 8]. The clinical improvement was considered significant when it decreased at least 30% versus the baseline for the VCSS score during the follow-up [5].

Procedure

Detailed descriptions of these procedures have been previously documented [5]. The procedure was conducted under sterile conditions using tumescent anesthesia and ultrasound-guided percutaneous access. A ClosureFast radiofrequency catheter (VNUS®, Covidien, Dublin, Ireland) was introduced through a 6 Fr sheath to the target vein, and thermal ablation was performed with temperatures between 100 °C and 120 °C. The initial vein segment received a double cycle of energy, while subsequent segments were treated with single impulses. Ancillary treatments, such as phlebectomy or foam sclerotherapy, were performed as needed. Post-procedure, patients were advised to wear compression stockings for at least 10 days. Follow-up included clinical and duplex ultrasound evaluations within one week and at 30 days to assess technical success, vein occlusion, and absence of complications.

Follow-up examination

All patients underwent clinical and CDUS examination within 1 week and 30 days after treatment. According to

 © 2025 Hogrefe

Dermody et al., complications were evaluated and assessed during the initial postoperative visit and after 1 week [11]. This examination aimed to discern patients with recurrences (RVV with or without GSV recanalization) and determine the severity of symptoms. The diagnostic and follow-up CDUS were performed by the same practitioners. CDUS examination was conducted to recognize perioperative technical success and the efficacy of treatment, as well as to detect postoperative GSV occlusion, the necessity for reintervention, and the durability of RFA.

Statistical analysis

Demographic and anatomical characteristics of all patients, procedure, post-operative, and follow-up details were collected in a dedicated database (excel software). The collected data were expressed as means±standard deviation (SDs) and percentages. All analysis was performed using the R-studio package, (Version 0.99.902 – © 2009–2016 RStudio, Inc., Boston, USA).

Results

Between December 2023 and May 2024, 50 limbs with incompetent GSV were treated in 50 consecutive patients that were referred from high-volume Vein Center (San Raffaele Hospital, Milan), using the Third-generation ClosureFast™ system (VNUS®, Covidien, Dublin, Ireland).

Demographic and anatomical characteristics of all patients are listed in Table I. Mean age was 55.8±13.4 years and most of the patients were females (58%). Among enrolled patients 8% (n=4) were current smokers, 28% (n=14) had a pregnancy history, 2% (n=1) had a DVT history, and 2% (n=1) had thrombophilia.

Most of the patients were classified CEAP C3 (88%) with a mean preoperative GSV diameter and lesion length of 6.2 ±2.4 mm and 31.3±7.1 cm. Perforator veins (PV) were detected in 20% of cases (n=10), among these 30% (n=3) were incompetent. Accessory saphenous vein was documented in all limbs and its confluence was directly into the SFJ in 12% (n=6) of limbs and into the GSV in other cases. The accessory saphenous vein was incompetent in 6% (n=3) of patients.

The technical success rate was achieved in 100% of cases. No intraoperative complications were documented. Phlebectomy treatment was associated in 24% (n=12) of cases, whereas foam sclerotherapy in 11% of cases (n=22). In 48% (n=24) of cases RFA was performed alone. Patients with ASV incompetence were treated with RFA in 2 cases, and with foam sclerotherapy in the remaining 1 case. Patients with PV incompetence were treated with surgical ligation in 1 case, and with foam sclerotherapy in 2 cases.

All patients had one week of follow-up. Among these 22% (n=11) had ecchymosis, 2% (n=1) had pain, and 2% (n=1) reported paraesthesia. No hyperpigmentation or phlebitis were documented. No heat-induced thrombosis, DVT or pulmonary embolism (PE) was described. The mean GSV diameter was 5.1±1.2 mm compared to baseline (p<.01) (Table II).

Table I. Preoperative clinical characteristics in patients who underwent radiofrequency ablation with third generation ClosureFast system of patients with great saphenous vein reflux. Absolute values are expressed as n (%) and continuous data are expressed as mean ± SD, median and interquartile range (IQR)

Demographics characteristics (n=50)	Overall
Age, years	55.8±13.4
Sex, female n (%)	29 (58)
BMI >25 kg/m^2	27±3.1
Hypertension	12 (24)
DM, n (%)	1 (2)
Smoker, n (%)	4 (8%)
Dystiroidism, n (%)	2 (4%)
CAD, n (%)	0 (0%)
Pregnancy history, n (%)	14 (28%)
DVT history, n (%)	1 (2%)
Trombophilia, n (%)	1 (2%)
CEAP	
C1, n (%)	3 (6)
C2, n (%)	0 (0)
C3, n (%)	44 (88)
C4, n (%)	2 (4)
C5, n (%)	0 (0.0)
C6, n (%)	1 (2)
Right GSV, n (%)	28 (56)
Left GSV, n (%)	22 (44)
Perforator vein incompetence, n (%)	3 (6)
ASV incompetence, n (%)	3 (6)
CDUS preoperative characteristics	
GSV diameter at 5 cm from SFJ (mm)	6.2 ± 2.4
GSV diameter at 10 cm from SFJ (mm)	7.8 ± 1.9
GSV diameter at 20 cm from SFJ (mm)	6.4 ± 2.3
Mean lesion length (cm)	31.3 ± 7.1
ASV origin in the SFJ, n (%)	6 (12)
ASV origin from GSV, n (%)	44 (88)
Clinical score	
VAS scale median (IQR)	52 (32–81)
VCSS, median (IQR)	7 (5–9)

Notes. ASV: accessory saphenous vein; BMI: body max index; CAD: coronary artery disease; CDUS: color duplex ultrasound; CEAP: clinical-etiology-anatomy-pathophysiology (2: varicose vein with symptoms; 3: swollen ankle; 4: skin changes; 5: healed leg ulcer; 6: active ulcer); DM: diabetes mellitus; DVT: deep vein thrombosis; GSV: great saphenous vein; IQR: interquartile range; SFJ: saphenous femoral junction; VAS: visual analogue scale; VCSS: venous clinical severity score.

At 30-days years from intervention, 50 patients were analyzed (Table II). Among these 8% (n=4) had ecchymosis, 2% (n=1) had pain, and 2% (n=1) reported hyperpigmentation. No EHIT, DVT, or PE were described. The mean GSV diameter was 4.7±1.5 mm (p<.01) (Table II).

A significant improvement in the CEAP classification over the follow-up was documented. At baseline, the mean CEAP score was 3.02, indicating a predominance of patients with moderate-to-severe venous disease (C3–C4). After one month, this value decreased to 1.59, reflecting a shift towards milder disease categories (C0–C2). The mean

© 2025 Hogrefe

Table II. Intraoperative detail and perioperative complications analysis, within 1 week and 30-day from intervention, in patients who underwent radiofrequency ablation with third generation ClosureFast system of patients with great saphenous vein reflux. Categorical values are expressed as n (%) and continuous data are expressed as the median and interquartile range (IQR)

Intraoperative details	Overall limbs (n=50)
Anesthesia	
Local, n (%)	48 (96)
Local and sedation, n (%)	2 (4)
Intervention time (min), median (IQR)	27 (24–36)
Phlebectomy, n (%)	12 (24)
Foam scleroterapy, n (%)	11 (22)
RFA alone, n (%)	24 (48)
PVs ligation	1 (2)
PVs foam scleroterapy	2 (4)
ASV treatment	3 (6)
RFA	2 (4)
Foam scleroterapy	1 (2)
Technical success, n (%)	50 (100)
Postoperative complications (within 1 week)	
Ecchymosis, n (%)	11 (22)
Hyperpigmentation, n (%)	0 (0)
Pain, n (%)	1 (2)
Paresthesia, n (%)	1 (2)
Phlebitis, n (%)	0 (0)
EHIT, n (%)	0 (0)
DVT, n (%)	0 (0)
CEAP	
C0, n (%)	1 (2)
C1, n (%)	6 (12)
C2, n (%)	25(50)
C3, n (%)	14 (28)
C4, n (%)	1 (2)
C5, n (%)	0 (0.0)
C6, n (%)	1 (2)
Follow-up 30-day (Patients n=50)	Overall limbs (n=50)
Ecchymosis, n (%)	4 (8)
Hyperpigmentation, n (%)	1 (2)
Pain, n (%)	1 (2)
Paresthesia, n (%)	0 (0)
Phlebitis, n (%)	0 (0)
EHIT, n (%)	0 (0)
DVT, n (%)	0 (0)
CEAP	
C0, n (%)	3 (6)
C1, n (%)	21 (42)
C2, n (%)	18 (36)
C3, n (%)	7 (14)
C4, n (%)	0 (0)
C5, n (%)	1 (2)
C6, n (%)	0 (0)

Notes. ASV: accessory saphenous vein; CEAP: clinical-etiology-anatomy-pathophysiology (2: varicose vein with symptoms; 3: swollen ankle; 4: skin changes; 5: healed leg ulcer; 6: active ulcer); DVT: deep vein thrombosis; IQR: interquartile range; EHIT: phlebitis and heat-induced thrombosis; PVs: perforator veins; RFA: radiofrequency ablation.

reduction of 1.43 points demonstrates the effectiveness of the treatment in alleviating the severity of chronic venous disease (Table II).

In follow-up, the venous clinical severity score had decreased a median of 3.6 (IQR: 2.4–6) points from baseline (p<.01) (Figure 1). Specifically, 85% of patients experienced an improvement in the VCSS score greater than 30% compared to baseline at one week, and approximately 97% at one month.

At a mean follow-up of 2.9±1.4 months, no patients were lost. Freedom from GSV recanalization and reintervention rate were both 100% within 1 week and 30 days from intervention, respectively.

Discussion

Chronic venous disease is a vascular disorder characterized by impaired venous return and the progressive deterioration of the venous system. The venous circulatory system operates in accordance with the principles of fluid dynamics, and prolonged orthostasis, coupled with inadequate activation of the distal muscle pump, increases the risk of its onset [12].

Occupational factors play a significant role in the development of CVD. A systematic review of 25 studies, published by Hirsch et al. in 2024, revealed that prolonged standing (over four hours daily), repetitive heavy lifting, and extended static postures in secondary and tertiary sector jobs are significant risk factors for CVD. Occupational history and patient activity profiles are crucial for diagnosis, while compression therapy serves as the primary secondary and tertiary prevention method. However, primary preventive measures through workplace design remain insufficient [13].

For more advanced stages (CEAP clinical class C2S), interventional treatment is recommended [10].

In the last few years, there has been an exponential growth of minimal-invasive techniques for the management of truncal reflux in patients with varicose veins, particularly due to more frequent application of diagnostics and evaluation of new approaches with marginal invasiveness [14, 15, 16]. First-generation RFA exemplified by the VNUS Closure System, employed a catheter to deliver radiofrequency energy to the vein wall, causing it to heat, collapse, and eventually seal shut [17]. This method was shown to be effective in treating superficial chronic venous insufficiency, however, it presented two main issues: the catheter pullback velocity had to be slow enough to allow resistive heating of the vein wall to a target temperature of 85 °C to 90 °C and the impossibility to measure the amount of energy delivered to the vein wall [15]. Several drawbacks have been found since its introduction, such as the extended duration of treatment, complexity of use, as well as incidence of both superficial and DVT post-treatment [18, 19].

 © 2025 Hogrefe

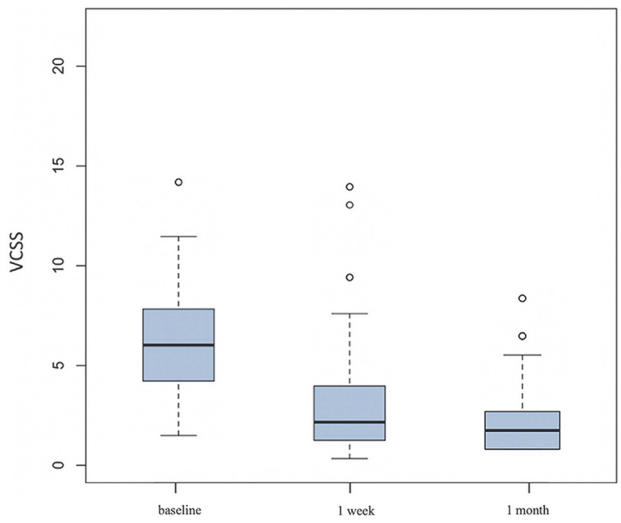

Figure 1. Venous clinical severity score (VCSS) before and after radiofrequency ablation (RFA) for great saphenous vein incompetence. The median (line within the box) and range (error bar), are shown.

The second generation of RFA catheters, ClosureFast 7 Fr, were engineered to enhance procedural efficiency by reducing the duration and simplifying the process. Unlike the first-generation RFA catheters (Closure and Closure Plus, respectively), ClosureFast utilizes a segmental ablation technique, activating the 7 cm long heating element in 20-second intervals. After each interval, the heat is automatically deactivated, and the catheter is repositioned to the subsequent treatment zone, as indicated by markers on the catheter shaft. The updated catheter (ClosureFast 6 Fr) design eliminated the need for a saline drip and mitigates high impedance issues caused by coagulum accumulation present in the previous models. The segmental approach, also known as segmental RFA ablation (s-RFA), accelerates the procedure and reduces dose variability delivered to the tissue. Additionally, this design incorporates changes in energy delivery by shielding the energy field, preventing the generation of an electrical field within the tissue, thereby minimizing potential interference with other implanted devices such as pacemakers [4].

This study aimed to assess the safety and efficacy of the last-generation ClosureFast catheter for RFA in treating GSV reflux. The results demonstrated a high technical success rate with minimal complications, positioning the last generation ClosureFast as a promising treatment for GSV reflux, confirming the safety and effectiveness with a low recanalization rate in the early period, associated with a shorter postoperative hospital stay, a quicker return to work, and a low incidence of periprocedural complications [10, 16, 17, 20].

The primary outcome of the study was technical success, defined as the capacity to deliver the ablation catheter to the target vein from the access point and to deploy radiofrequency energy for the entire length of the incompetent vein, totally ablating the insufficient saphenous trunk. The study reported a 100% technical success rate, aligning with other studies that have demonstrated high efficacy rates for RFA [16]. Moreover, the absence of significant complications within 30 days post-procedure is noteworthy. The study found no instances of DVT or puncture site thermal injury, with minor complications such as hyperpigmentation and ecchymosis occurring in a small percentage of patients (Table II). These findings are consistent with the reported safety profile of RFA in existing literature [5, 6, 16].

When compared to endovenous laser ablation (EVLA) and traditional surgical methods such as high ligation and stripping (HL/S), RFA has consistently demonstrated comparable or superior outcomes. A randomized clinical trial by Lawaetz and colleagues comparing RFA, EVLA, and foam sclerotherapy found that RFA and EVLA had higher occlusion rates and lower recurrence rates compared to foam sclerotherapy, with similar safety profiles [21]. Additionally, RFA is associated with less post-operative pain and faster recovery times compared to HL/S, making it a more patient-friendly option [21]. The study also evaluated the clinical outcomes using the VCSS and CEAP classification, reporting a significant score reduction from baseline to follow-up.

Furthermore, a study by H. Uthoff et al. confirmed that endovenous thermal ablation of varicose veins is both feasible and safe year-round [22]. In particular, in this study, the authors evaluated 846 endovenous thermal ablation procedures in 679 patients to determine if ambient temperature affects treatment outcomes for varicose veins. Patients were grouped by temperature (<25 °C, 25–29.9 °C, and ≥30 °C) recorded within 14 days post-treatment. Despite higher rates of obesity and prior superficial vein thrombosis in warmer groups, occlusion rates remained excellent (99–100%) with no significant differences in complications, work loss, or patient satisfaction. Overall, endovenous thermal ablation is demonstrated to be a safe and effective treatment for varicose veins year-round, including during hotter conditions.

This substantial improvement underscores the efficacy of the intervention and supports its use as a reliable and effective method for managing great saphenous vein reflux. The findings align with previous research demonstrating that RFA leads to substantial improvements in clinical symptoms and quality of life measures. Moreover, a study by Subramonia and Lees reported significant improvements in VCSS and quality of life scores following RFA, supporting the current study's results [23].

The Third-generation ClosureFast catheter used in this study represents a significant advancement in RFA technology. This generation features a reduced catheter diameter, increased treatment length, and greater flexibility, enhancing its applicability in treating tortuous veins. The reduced diameter minimizes the invasiveness of the procedure, potentially decreasing the risk of complications such as vessel perforation and improving patient comfort. The increased treatment length and flexibility allow for more efficient and effective vein ablation, particularly in anatomically challenging cases, such as in case of venous tortuosity.

© 2025 Hogrefe

While the short-term results are promising, the durability of the Third-generation RFA over longer follow-up periods remains a critical consideration. The study's follow-up period averaged 2.9 months, with no cases of RVV or GSV recanalization reported.

Long-term studies have shown varying recurrence rates for RFA, with some reporting rates as low as 2% over five years, while others indicate higher recurrence rates depending on patient characteristics and follow-up duration [10, 24, 25, 26].

Personalized treatment strategies are becoming increasingly important in the management of CVD. Factors such as vein anatomy (e.g. direct confluence of the accessory saphenous vein into safe-femoral junction), patient comorbidities (female gender, pregnancy >2, and CEAP class 4 and 5), and lifestyle (e.g. smoking) should be considered when selecting the most appropriate treatment modality [5, 6, 27]. The current study included a diverse patient population, with varying degrees of venous disease severity and comorbid conditions, highlighting the need for individualized treatment plans. Personalized approaches can optimize clinical outcomes and enhance patient satisfaction by tailoring treatment to specific patient needs.

Limitations

This study has several limitations. First, the retrospective and non-randomized nature of the research introduces potential biases in patient selection and data collection. Second, the follow-up period was limited to a mean of 2.9 months, restricting the ability to evaluate long-term outcomes, such as recurrence rates and durability of the treatment. Finally, the absence of an independent assessors and of a comparative cohort using alternative techniques, such as endovenous laser ablation (EVLA) or surgical stripping, precludes a direct evaluation of the relative efficacy and safety of the Third-generation ClosureFast catheter.

Further studies with larger, randomized cohorts and extended follow-up durations are necessary to confirm these preliminary findings.

Conclusions

The Third-generation ClosureFast catheter demonstrates high efficacy and safety in the treatment of GSV reflux, with significant improvements in clinical symptoms and minimal complications at follow-up. These findings reinforce the role of RFA as a cornerstone in the management of CVD. Longer follow-up and further study with larger cohorts of patients are still needed to confirm these outcomes.

References

1. Attaran RR, Carr JG. Chronic venous disease of the lower extremities: a state-of-the art review. J Soc Cardiovasc Angiogr Interv. 2022; 2(1):100538.
2. Shahzad N, Elsherif M, Obaidat I, Brar R. A systematic review and meta-analysis of randomised controlled trials comparing thermal versus non-thermal endovenous ablation in superficial venous incompetence. Eur J Vasc Endovasc Surg. 2023; 66(5):687–95.
3. Lawson JA, Gauw SA, van Vlijmen CJ, Pronk P, Gaastra MTW, Tangelder MJ, et al. Prospective comparative cohort study evaluating incompetent great saphenous vein closure using radiofrequency-powered segmental ablation or 1470-nm endovenous laser ablation with radial-tip fibers (Varico 2 study). J Vasc Surg Venous Lymphat Disord. 2018;6(1):31–40.
4. Woo HY, Kim SM, Kim D, Chung JK, Jung IM. The outcome of ClosureFAST radiofrequency ablation for a large-diameter incompetent great saphenous vein. Ann Surg Treat Res. 2019;96(6):313–8.
5. Baccellieri D, Ardita V, Pannone A, Valente FBA, Lembo R, Chiesa R, et al. Factors influencing recurrent varicose vein formation after radiofrequency thermal ablation for truncal reflux performed in two high-volume venous centers. J Vasc Surg Venous Lymphat Disord. 2024;12(2):101675.
6. Baccellieri D, Ardita V, Carta N, Melissano G, Chiesa R. Anterior accessory saphenous vein confluence anatomy at the saphenofemoral junction as a risk factor for varicose veins recurrence after great saphenous vein radiofrequency thermal ablation. Int Angiol. 2020;39(2):105–11.
7. Eklöf B, Rutherford RB, Bergan JJ, Carpentier PH, Gloviczki P, Kistner RL, et al. Revision of the CEAP classification for chronic venous disorders: consensus statement. J Vasc Surg. 2004;40(6):1248–52.
8. Vasquez MA, Munschauer CE. Venous Clinical Severity Score and quality-of-life assessment tools: application to vein practice. Phlebology. 2008;23(6):259–75.
9. Coleridge-Smith P, Labropoulos N, Partsch H, Myers K, Nicolaides A, Cavezzi A, UIP. Duplex ultrasound investigation of the veins in chronic venous disease of the lower limbs – UIP consensus document. Part I. Basic principles. Vasa. 2007; 36(1):53–61.
10. De Maeseneer MG, Kakkos SK, Aherne T, Baekgaard N, Black S, Blomgren L, et al. Editor's ChoiceEuropean Society for Vascular Surgery (ESVS) 2022 clinical practice guidelines on the management of chronic venous disease of the lower limbs. Eur J Vasc Endovasc Surg. 2022;63(2):184–267.
11. Dermody M, O'Donnell TF, Balk EM. Complications of endovenous ablation in randomized controlled trials. J Vasc Surg Venous Lymphat Disord. 2013;1(4):427–36.
12. Guven H.. Fluid dynamics and venous hemodynamics in the lower extremities. Vasa. 2024;53:308–13.
13. Hirsch T, Wahl U, Rabe E. Venous disorders as an occupational disease – a systematic review on epidemiology, pathophysiology, and modification strategies. Vasa. 2024;53:172–84.
14. Apruzzi L, Bilman V, Ardita V, Favia N, Saracino C, Chiesa R, et al. Comparison of mechanochemical ablation versus ligation and stripping for the treatment of incompetent small saphenous vein. Phlebology. 2022;37(1):48–54.
15. Chan SSJ, Chan YC, Walsh SR, Chong TT, Choke ETC, Tiwari A, et al. Endovenous cyanoacrylate ablation for chronic venous insufficiency and varicose veins among Asians. Ann Acad Med Singap. 2021;50(3):241–9.
16. Kheirelseid EAH, Crowe G, Sehgal R, Liakopoulos D, Bela H, Mulkern E, et al. Systematic review and meta-analysis of randomized controlled trials evaluating long-term outcomes of endovenous management of lower extremity varicose veins. J Vasc Surg Venous Lymphat Disord. 2018;6(2):256–70.
17. Proebstle TM, Vago B, Alm J, Göckeritz O, Lebard C, Pichot O. Treatment of the incompetent great saphenous vein by endovenous radiofrequency powered segmental thermal ablation: first clinical experience. J Vasc Surg. 2008;47(1):151–6.
18. Puggioni A, Marks N, Hingorani A, Shiferson A, Alhalbouni S, Ascher E. The safety of radiofrequency ablation of the great saphenous vein in patients with previous venous thrombosis. J Vasc Surg. 2009;49(5):1248–55.

 © 2025 Hogrefe

19. Puggioni A, Kalra M, Carmo M, Mozes G, Gloviczki P. Endovenous laser therapy and radiofrequency ablation of the great saphenous vein: analysis of early efficacy and complications. J Vasc Surg. 2005;42(3):488–93.
20. National Institute for Health and Care Excellence.Varicose veins: diagnosis and management. Clinical guideline [CG168]. Published: 24 July 2013. Available at: https://www.nice.org.uk/guidance/cg168
21. Lawaetz P, Bjoern L, Danielsson G, Kósa A, Mailund KR, Petersen LH, et al. Comparison of endovenous ablation techniques, foam sclerotherapy and surgical stripping for great saphenous varicose veins. Extended 5-year follow-up of a RCT. Int Angiol. 2017;36(3):281–8.
22. Uthoff H, Teruzzi E, Boesch P, Hofer M, Spinedi L, Bossart S, et al.. Safety and efficacy of endovenous thermal ablation for treatment of symptomatic varicose veins during summertime. Vasa. 2023;(52):332–41.
23. Subramonia S, Lees T. Radiofrequency ablation vs. conventional surgery for varicose veins–a comparison of treatment costs in a randomised trial. Eur J Vasc Endovasc Surg. 2010;39(1):104–11.
24. Wittens C, Davies AH, Bækgaard N, Broholm R, Cavezzi A, Chastanet S. Management of chronic venous disease: clinical practice guidelines of the European Society for Vascular Surgery (ESVS). Eur J Vasc Endovasc Surg. 2015;49:678–737.
25. Brake M, Lim CS, Shepherd AC, Shalhoub J, Davies AH. Pathogenesis and etiology of recurrent varicose veins. J Vasc Surg. 2013;57(3):860–8.
26. Lomazzi C, Bissacco D, Logan MS, Grassi V, Piffaretti G, Trimarchi S. Risk factors for saphenous vein recanalization after endovenous radiofrequency ablation. J Cardiovasc Surg. 2021;6:427–34.
27. Engelhorn CA, Engelhorn ALDV, Salles-Cunha SX, Andreatta CB, Santos DB, Nakata GTM, et al. Associations of anterior accessory or thigh posterior tributary and great saphenous reflux patterns in early stages of chronic venous valvular insufficiency. Veins Lymphatics. 2014;3:1938.

History
Submitted December 19, 2024
Accepted after revision March 7, 2025
Published online XX.XX.2025

Conflict of interest
The authors declare that there are no conflicts of interest.

ORCID
Domenico Baccellieri
https://orcid.org/0000-0003-1201-0508
Benedetta Mangili
https://orcid.org/0009-0002-7615-4228

Correspondence address
Vincenzo Ardita, MD, PhD
Department of Vascular Surgery
San Raffaele Scientific Institute
Vita-Salute University School of Medicine
Via Olgettina 60
20132 Milan
Italy

ardita.vincenzo@hsr.it

© 2025 Hogrefe