Effectiveness of Nitinol-Constrained Balloon Angioplasty for Treating Postangioplasty Dissections in Chronic Total Occlusions of the Femoropopliteal Segment

Domenico Mirabella, MD, Salvatore Bruno, MD, Manfredi La Marca, MD, Ettore Dinoto, MD, Carlo Setacci, MD, and Felice Pecoraro, MD

ABSTRACT

Purpose: To assess the effectiveness of nitinol-constrained balloon (NCB; Chocolate; Medtronic, Dublin, Ireland) percutaneous transluminal angioplasty (PTA) for treating Diameter reduction, Spiral shape, Flow impairment, or adverse Morphology (DISFORM) III postangioplasty dissections in chronic total occlusions (CTOs) of the femoropopliteal segment.

Materials and Methods: The CHOCOlate-STABilization (CHOCO-STAB) study was conducted from February 2019 to February 2022. It included patients with peripheral arterial disease affected by chronic limb-threatening ischemia. This study specifically included patients with DISFORM III postangioplasty dissections who were treated using NCB angioplasty after initial PTA. The main outcomes assessed in this study were technical success and the occurrence of major adverse events.

Results: This study included 68 patients with a mean age of 72 years (SD ± 10), of whom 39% had diabetes. The initially treated CTOs had a mean length of 10.32 mm (SD ± 5; interquartile range, 5–15 mm), with moderate or severe calcification in 28%. Forty-seven (69%) patients received initial treatment with drug-coated balloons (DCBs). NCB angioplasty was feasible in all patients, achieving technical success in 62 (91%). Stent placement was required in the remaining 6 (9%) cases. Three-year estimated overall survival was 98.5%, primary patency was 88.2%, freedom from major amputation was 94.1%, and freedom from clinical target lesion revascularization was 94.1%.

Conclusions: Postangioplasty dissections represent a relevant adverse event that necessitates scaffolding in moderate and severe grades. The CHOCO-STAB study demonstrated the safety and potential of NCB angioplasty to reduce stent placement in patients treated with DCB and plain old balloon angioplasty who present with postangioplasty dissections.

ABBREVIATIONS

ABI = ankle-brachial index, CHOCO-STAB = CHOCOlate-STABilization, CT = computed tomography, CTO = chronic total occlusion, DCB = drug-coated balloon, DISFORM = Diameter reduction, Spiral shape, Flow impairment, or adverse Morphology, IRB = Institutional Review Board, NCB = nitinol-constrained balloon, PACSS = Peripheral Arterial Calcium Scoring System, PAD = peripheral arterial disease, POBA = plain old balloon angioplasty, PPA = proximal popliteal artery, PTA = percutaneous transluminal angioplasty, SFA = superficial femoral artery, STROBE = Strengthening the Reporting of Observational Studies in Epidemiology, TLR = target lesion revascularization, US = ultrasound.

Postangioplasty dissection is a frequent adverse event of percutaneous transluminal angioplasty (PTA), occurring in up to 80% of lower limb artery interventions (1). This phenomenon is clinically relevant because it is associated with an increased risk of major adverse limb events, including restenosis, reocclusion, and limb ischemia. In cases of severe dissections that jeopardize procedural success, bailout stent placement is commonly required. However, this strategy carries long-term drawbacks such as in-stent restenosis, stent thrombosis, and stent fracture, all

Figure E1 can be found by accessing the online version of this article on *www.jvir.org* and selecting the Supplemental Material tab.

© SIR, 2025. This is an open access article under the CC BY license (http://creativecommons.org/licenses/by/4.0/).

J Vasc Interv Radiol 2026; 37:107912
https://doi.org/10.1016/j.jvir.2025.107912

RESEARCH HIGHLIGHTS

- This was a single-center retrospective cohort study.
- Overall, 68 patients were treated with nitinol-constrained balloon for postangioplasty dissections.
- Technical success was 91.2%, with 6 residual dissections.
- Primary patency was 88.2%, freedom from major amputation was 94.1%, and freedom from clinical target lesion revascularization was 94.1%.
- Nitinol-constrained balloon angioplasty is effective in managing postangioplasty dissection with promising 3-year outcomes.

STUDY DETAILS

Study type: Retrospective, observational, cohort study

Study phase: NA

Level of evidence: 2 (SIR-B)

of which may compromise vessel patency and limb function (2–4).

The CHOCOlate-STABilization (CHOCO-STAB) study was designed to evaluate the effectiveness of a nitinol-constrained balloon (NCB; Chocolate; Medtronic, Dublin, Ireland) in the treatment of Diameter reduction, Spiral shape, Flow impairment, or adverse Morphology (DISFORM) Class III dissections. The trial focused on patients with chronic total occlusions (CTOs) of the superficial femoral artery (SFA) and/or proximal popliteal artery (PPA). Its primary aim was to determine whether NCB-based angioplasty could stabilize complex dissections without the need for stent placement, thereby improving long-term vessel patency and clinical outcomes.

MATERIALS AND METHODS

The CHOCO-STAB study is a retrospective single-center study conducted in accordance with the Declaration of Helsinki and following the Strengthening the Reporting of Observational Studies in Epidemiology (STROBE) guidelines for reporting observational studies (5) . All patients included in this study provided informed consent for the procedure and for the anonymous collection and analysis of their data. The study protocol was reviewed and approved by the Institutional Review Board (IRB) - CEL Palermo 1. Given its retrospective design and the use of fully anonymized data, the Board determined that further approval from a medical ethics committee was not required.

Data Source and Patient Selection

Data were collected from patients with femoropopliteal chronic occlusions from February 2019 to February 2022. This study excluded patients presenting with stenotic arterial lesions, previous arterial or endovascular procedures in the target limb, planned amputation, acute or subacute occlusions, inadequate runoff (at least 1 patent infrapopliteal vessel with <50% diameter stenosis), or femoropopliteal dissection before the initial PTA. Only patients affected by critical limb-threatening ischemia in Rutherford Categories 4, 5, and 6 who underwent primary PTA with a drug-coated balloon (DCB) or plain old balloon angioplasty (POBA) were considered eligible. Patients in Rutherford Category 3 were deliberately excluded to ensure homogeneous results. Patients with postangioplasty dissections were identified through intraoperative imaging and classified according to the DISFORM study into 4 classes. Patients with DISFORM III postangioplasty dissections treated with NCB angioplasty were included in this study. The primary angioplasty allowed the use of either POBA or DCB (Fig 1).

Baseline Characteristics

This study included 68 patients, 55 (80.8%) of whom were male, with a mean age of 72.02 years (SD ± 10; median, 73.12 years; interquartile range [IQR], 65–80 years). Forty-seven (69%) patients initially underwent angioplasty with DCB, and 21 (31%) underwent POBA.

The initial clinical presentation was categorized as Rutherford Categories 4, 5, and 6 in 4 (5.88%), 62 (91.18%), and 2 (2.94%) patients, respectively. The mean preoperative ankle-brachial index (ABI) was 0.29 (SD ± 0.06; IQR, 0.23–0.32). Patients treated with DCB had a higher incidence of lipid disorder (25.53%, $P = .027$) and cerebrovascular disease (21.28%, $P = .027$), whereas patients in the POBA group had a higher incidence of hypertension (95.24%, $P < .001$) and diabetes (85.71%, $P < .001$). Baseline demographic and clinical features are reported in Table 1.

CTO locations were in the SFA in 46 (67.65%), in the PA in 8 (11.76%), and in both SFA and PA in 14 (20.59%) patients. The mean CTO length was 10.43 cm (SD ± 5; IQR, 5–14 cm). A calcified artery was reported in 42 (61.76%) patients—25 mild, 12 moderate, and 5 severe cases. No significant differences were observed in terms of lesion characterization as reported in Table 2.

Vessel predilation with POBA was employed in all patients treated with DCB (47, 100%) and in 16 (76%) treated with POBA. A significantly higher rate of vessel predilation and balloon use was reported in the DCB group. Details of the employed DCB and POBA are reported in Table 3.

Different DISFORM III grades were identified at completion angiography and are reported in Table 4. No differences were observed between the DCB and POBA groups regarding dissection characterization.

Management of DISFORM III postangioplasty dissections with NCB angioplasty was feasible in all patients,

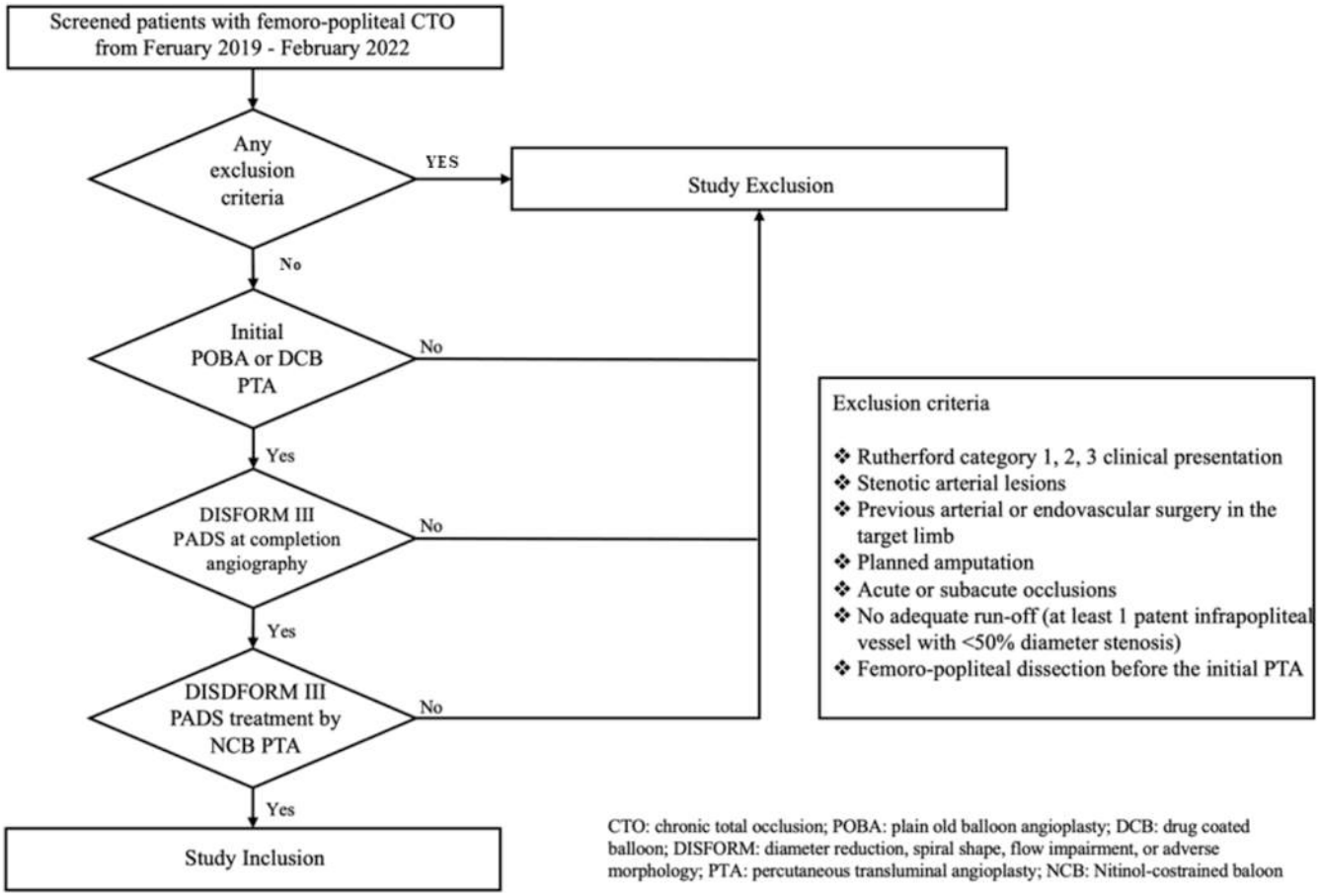

Figure 1. Flow diagram for inclusion and exclusion criteria: Algorithm employed to include patients in this study.

Table 1. Baseline Demographic and Clinical Features

Characteristics	TOT	DCB	POBA	*P*
Patients, n	68	47	21	
Age, y, mean (SD)	72 (10.27)	71.01 (12.88)	73.12 (9.35)	
Male, n (%)	55 (80.88)	37 (78.72)	18 (85.71)	.16
Associated comorbidities				
Hypertension, n (%)	56 (82.35)	36 (76.60)	20 (95.24)	**<.001**
Smoker, n (%)	23 (33.82)	15 (31.92)	8 (38.10)	.37
Chronic obstructive pulmonary disease, n (%)	26 (38.23)	17 (36.17)	9 (42.86)	.37
Cerebrovascular disease, n (%)	15 (22.06)	10 (21.28)	5 (20.84)	**.027**
Coronary artery disease, n (%)	26 (38.23)	16 (34.04)	10 (47.62)	.14
Diabetes mellitus, n (%)	53 (77.94)	35 (74.47)	18 (85.71)	**.027**
Lipid disorders, n (%)	15 (22.06)	12 (25.53)	3 (14.29)	**.027**
RFI (GFR < 60 mL/min), n (%)	19 (27.94)	12 (25.53)	7 (33.33)	.23
Cancer, n (%)	4 (5.88)	3 (6.38)	1 (4.76)	.60
Clinical Rutherford category				.74
Rutherford 4, n (%)	4 (5.88)	2 (4.26)	2 (9.52)	
Rutherford 5, n (%)	62 (91.18)	43 (91.49)	19 (90.48)	
Rutherford 6, n (%)	2 (2.94)	2 (4.26)	0 (0)	
Ankle-brachial index, mean (SD)	0.29 (0.06)	0.28 (0.07)	0.30 (0.05)	.22

Note–Bold values indicate statistical significance.
DCB = drug-coated balloon; GFR = glomerular filtration rate; POBA = plain old balloon angioplasty; RFI = renal function impairment; TOT = total.

Table 2. Lesion Characterization

Characteristics	TOT	DCB	POBA	P
Patients, n	68	47	21	
Chronic total occlusion distribution				.50
Superficial femoral artery, n (%)	46 (67.65)	31 (65.96)	15 (71.42)	
Popliteal artery, n (%)	8 (11.76)	5 (10.64)	3 (14.29)	
Superficial femoral artery + popliteal artery, n (%)	14 (10.29)	11 (23.40)	3 (14.29)	
Chronic total occlusion length, mm (SD)	10.43 (5)	10.19 (5)	10.95 (4)	.31
Chronic total occlusion calcification, n (%)	42 (61.76)	28 (59.58)	14 (66.67)	.44
Mild calcification, n (%)	25 (36.76)	16 (34.04)	9 (42.85)	
Moderate calcification, n (%)	12 (17.65)	8 (17.02)	4 (19.04)	
Severe calcification, n (%)	5 (7.35)	4 (8.51)	1 (4.76)	

DCB = drug-coated balloon; POBA = plain old balloonangioplasty; TOT = total.

showing no adverse events during balloon positioning, inflation, or retrieval. The mean NCB transverse diameter and length used were 5.24 mm (SD ± 0.69; IQR, 5–6 mm) and 77.06 mm (SD ± 24.25; IQR, 80–80 mm), respectively. The mean follow-up duration was 31.44 months (SD ± 13; IQR, 20–41 months).

Definitions

Postangioplasty dissections were identified after the initial angioplasty using the DISFORM classification (6) (Table 5).

The DISFORM III pattern includes postangioplasty dissections with less than 50% diameter reduction and any of the following: (*a*) 1 single short (<2 cm) spiral dissection without flow impairment (D0S1F0M0), (*b*) 1 long or multiple short (<2 cm) linear dissections with minor flow impairment (D0S0F1M1), (*c*) multiple long linear dissections with no minor flow impairment (D0S0F0M2), or (*d*) multiple long linear dissections with minor flow impairment (D0S0F1M2).

Arterial calcifications were categorized according to the Peripheral Arterial Calcium Scoring System (PACSS) (7) as none (PACSS Grades 0–1), mild (PACSS Grade 2), moderate (PACSS Grade 3), or severe (PACSS Grade 4).

A hemodynamically arterial lesion was defined as any obstruction of arterial flow causing major flow impairment, identified angiographically (>70% of original diameter using anteroposterior and oblique projections) or ultrasonographically (peak systolic velocity, >240 cm/s).

Technical success was defined as the resolution of DISFORM III postangioplasty dissection after the use of NCB without additional stent placement and with no residual vessel stenoses greater than 30%.

Table 3. Balloon Angioplasty Catheter Employed in the Initial Angioplasty

Characteristics	Total	DCB	POBA	P
Patients, n	68	47	21	
Vessel preparation	63 (92.65)	47 (100)	16 (76)	<.001
Mean balloon transverse diameter, mm (SD)	3.07 (0.62)	3.15 (0.61)	2.84 (0.60)	.80
Mean balloon length, mm (SD)	132.77 (67.60)	122.98 (66.17)	159.38 (70.57)	.54
Total balloon employed, n	65*	47	18	.77
Bard Ultraverse	15	11	4*	
Boston Scientific Mustang	7	5	2	
Cordis Powerflex	6	5	1	
iVascular Oceanus	21	14	7	
Medtronix Admiral Xtreme	16	12	4*	
Initial balloon angioplasty				
Mean balloon transverse diameter, mm (SD)	5.29 (0.94)	5.05 (0.89)	5.89 (1.11)	.15
Mean balloon length, mm (SD)	158.90 (86.74)	171.27 (89.01)	128.62 (87.18)	.24
Total balloon employed, n	100	71	29	0.041
Bard Lutonix DCB	15	15	-	
iVascular Luminor DCB	28	28	-	
Medtronic Admiral DCB	21	21	-	
Philips Stellarex DCB	7	7	-	
Bard Ultraverse	7	-	7	
Boston Scientific Mustang	4	-	4	
Cordis Powerflex	3	-	3	
iVascular Oceanus	4	-	4	
Medtronix Admiral Xtreme	11	-	11	
Patients requiring 2 balloon catheters	32	24	8	

DCB = drug-coated balloon; POBA = plain old balloonangioplasty.
*In 2 patients in the POBA group, an additional balloon for vessel preparation was required.

Table 4. Diameter reduction, Spiral shape, Flow impairment, or adverse Morphology Parameters and DISFORM III Grade Identification at Completion Angiography after the Initial Angioplasty

Characteristics	Total	DCB	POBA	*P*
Patients, n	68	47	21	
DISFORM parameters				
Diameter				NA
D_0: diameter reduction < 50%	68	47	21	
D_1: diameter reduction ≥ 50%	0	0	0	
Spiral shape				.84
S_0: nonspiral (linear) configuration	48	33	15	
S_1: any spiral configuration	20	14	6	
Flow impairment				.92
F_0: FLIPI 0, normal antegrade flow	35	24	11	
F_1: FLIPI 1, reduced antegrade flow	33	23	10	
F_2: FLIPI 2, minor antegrade penetration	0	0	0	
F_3: FLIPI 3, no flow through dissected segment, only collateral filling	0	0	0	
Morphology				.47
M_0: One single dissection <2 cm in length	20	14	6	
M_1: Multiple dissections <2 cm length or a single dissection ≥2 cm length	18	14	4	
M_2: Multiple dissections ≥2 cm in length	30	19	11	
DISFORM III grade				.60
$D_0S_1F_0M_0$	20	14	6	
$D_0S_0F_1M_1$	18	14	4	
$D_0S_0F_0M_2$	15	10	5	
$D_0S_0F_1M_2$	15	9	6	

DCB = drug-coated balloon; DISFORM = Diameter reduction, Spiral shape, Flow impairment, or adverse Morphology; NA = not available; POBA = plain old balloonangioplasty.

Table 5. DISFORM Classification

DISFORM parameters
Diameter
D_0: diameter reduction <50%
D_1: diameter reduction ≥50%
Spiral shape
S_0: nonspiral (linear) configuration
S_1: any spiral configuration
Flow impairment
F_0: FLIPI 0, normal antegrade flow
F_1: FLIPI 1, reduced antegrade flow
F_2: FLIPI 2, minor antegrade penetration
F_3: FLIPI 3, no flow through dissected segment, only collateral filling
Morphology
M_0: One single dissection <2 cm in length
M_1: Multiple dissections <2 cm length or a single dissection ≥2 cm length
M_2: Multiple dissections ≥2 cm in length
DISFORM III grade
$D_0S_1F_0M_0$
$D_0S_0F_1M_1$
$D_0S_0F_0M_2$
$D_0S_0F_1M_2$

DISFORM = Diameter reduction, Spiral shape, Flow impairment, or adverse Morphology.

Procedure

Procedures were carried out by senior vascular surgeons of the team, with over 10 years of experience (D.M., E. D., F.P.) in endovascular treatment of peripheral arterial disease (PAD). Patients eligible for endovascular treatment were identified using ultrasound (US) and computed tomography (CT) scans, particularly when severe calcification in the vessel walls complicated flow assessment (PACSS Grade 3–4). To qualify for endovascular treatment, candidates needed to demonstrate patency of the common femoral artery and have an occlusion length not exceeding 25 cm. The operative procedure involved baseline angiography to confirm CTO, assess runoff vessels, and identify any femoropopliteal dissection before the initial angioplasty (**Fig 2a–c**). In case of arterial calcification (PACSS Grades 3–4), POBA angioplasty was used after vessel recanalization, whereas DCB angioplasty was chosen for the remaining cases (**Fig 3a–e**). After the initial angioplasty, a DISFORM III postangioplasty dissection was diagnosed upon completion angiography with at least 2 views. Upon identification of DISFORM III dissection, NCB angioplasty was routinely adopted as the first-line maneuver to treat the residual dissection, reserving scaffolding in case of failure. The NCB PTA balloon was positioned to cover at least 2 cm of the proximal and distal extension for postangioplasty dissections shorter than 80 mm. For dissections longer than 80 mm, NCB angioplasty was performed from the distal to the proximal side. Sizing was performed 1:1 with the native vessel diameter, with oversizing not exceeding 1 mm. Balloon inflation was maintained for 3 minutes (**Fig 3d**). Two NCBs were used to ensure adequate vessel dilation to its original caliber in case of discrepancy between distal SFA and PPA diameters. Residual dissections and vessel patency following NCB angioplasty were assessed angiographically and ultrasonographically, with stent placement performed only for residual severe (>70%) flow stenosis. After each procedure, patients were prescribed dual antiplatelet therapy (100 mg of acetylsalicylic acid and 75 mg of clopidogrel) plus a high-dose statin for 3 months, followed by long-term monotherapy with acetylsalicylic acid. The follow-up protocol included duplex US and clinical examinations at 1, 6, and 12 months.

Outcomes

The primary outcomes were technical success (vessel patency with residual stenosis < 30% without bailout stent placement) and new-onset major adverse events. Major adverse events included perioperative death, primary patency, clinical target lesion revascularization (TLR), and major amputation (any amputation above the ankle). Minor amputations, changes in the clinical Rutherford category, and ABI at follow-up were reported as secondary outcomes.

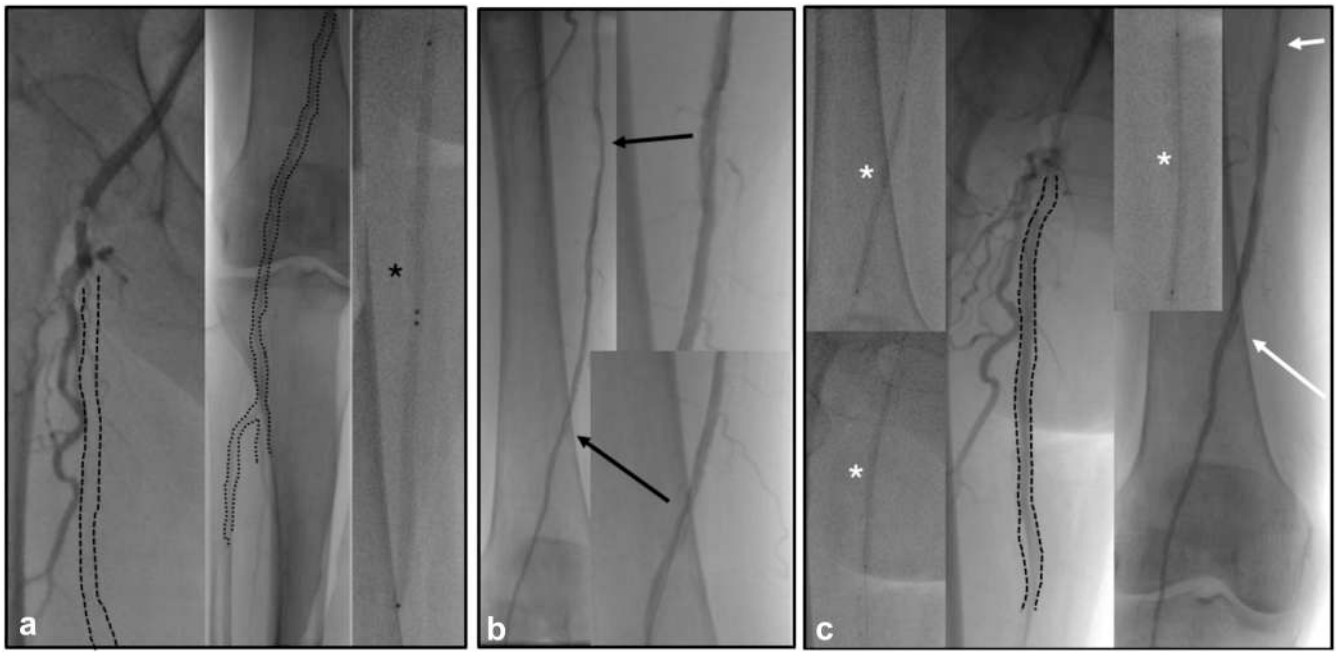

Figure 2. Procedure description. **(a)** Initial digital subtraction angiography (DSA) of femoropopliteal chronic occlusion (black dashed vessel outline) and distal revascularization of the vessel (black dotted vessel outline) treated initially using a plain old balloon (black asterisk). **(b)** Diameter reduction, Spiral shape, Flow impairment, or adverse Morphology III postangioplasty dissection in Grade $D_0S_0F_0M_2$ (black arrows). **(c)** Nitinol-constrained balloon percutaneous transluminal angioplasty (PTA) (white asterisks) of the Diameter reduction, Spiral shape, Flow impairment, or adverse Morphology III and final DSA showed restored flow in femoropopliteal axis (black dashed vessel outline) and the postangioplasty dissection resolution (white arrows).

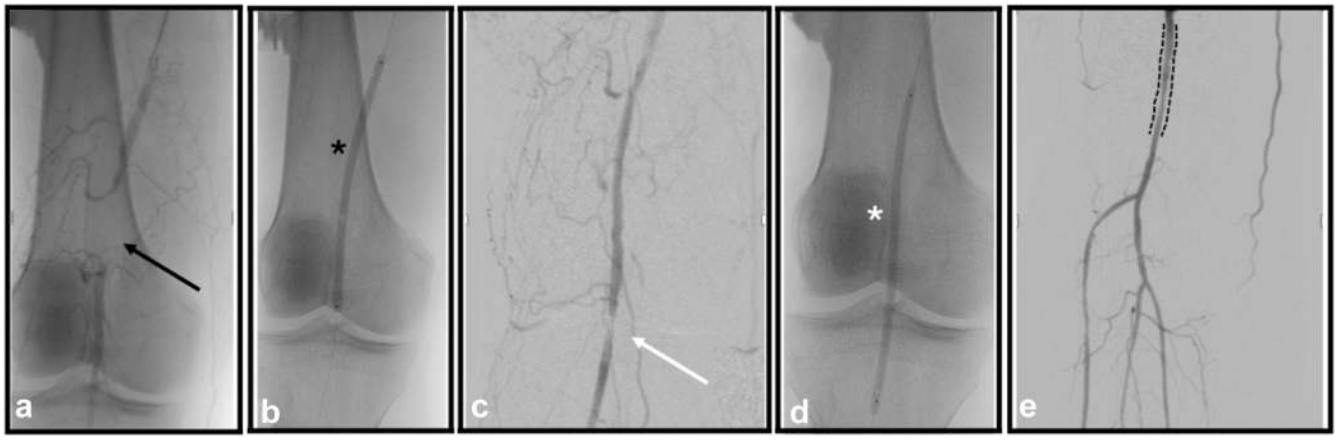

Figure 3. Drug-coated balloon use for primary percutaneous transluminal angioplasty (PTA). **(a)** Initial digital subtraction angiography (DSA) of popliteal chronic occlusion (black arrow). **(b)** Initial management using a drug-coated balloon (black asterisk). **(c)** Diameter reduction, Spiral shape, Flow impairment, or adverse Morphology III postangioplasty dissection (white arrow) in Grade $D_0S_1F_0M_0$. **(d)** Nitinol-constrained balloon PTA (white asterisk) of the Diameter reduction, Spiral shape, Flow impairment, or adverse Morphology III. **(e)** Final DSA showed the postangioplasty dissection resolution (black dashed vessel outline).

Statistical Analysis

Categorical variables were reported as absolute numbers and frequencies (%); continuous data were expressed as means (IQRs and SDs). Differences between groups were assessed using the *t*-test and chi-square test. Multivariate analysis was performed with analysis of variance. Kaplan-Meier curves were used to estimate survival, primary patency, major amputation, clinical TLR, and minor amputations rates. The Tarone-Ware test was used to assess differences between curves. Statistical significance was $P <$

.05. For Kaplan-Meier analyses, CIs and SEs were reported. Statistical analysis was conducted using SPSS 22.0 (SPSS, Chicago, Illinois).

RESULTS

Outcomes

Technical success was achieved in 62 (91.2%) patients. Residual dissections after NCB angioplasty occurred in 4 patients in the DCB group and 2 in the POBA group, with no significant differences ($P = .79$). Residual dissections were located in the SFA in 4 patients and 2 in the PPA.

Residual dissections after NCB angioplasty underwent stent placement with a bare-metal stent in the SFA. PPA post-angioplasty dissections were treated with stent-graft placement in cases with absent genicular collateralization. The mean stent length was 53.33 mm (SD ± 8.16; IQR, 50–60 mm).

During the perioperative period, no perioperative death was recorded; however, 2 (2.9%) major amputations occurred —1 patient presented with DCB and 1 with POBA. Both patients presented with target vessel occlusion.

During the follow-up, 7 (10.29%) patients died. There were 2 (2.9%) major amputations and 2 patients experienced target vessel occlusion.

At the 3-year follow-up, the estimated overall survival was 98.5% (SE ± 1.33; CI, 50–55) (**Fig 4a**), primary patency was 88.2% (SE ± 1.87; CI, 47–54) (**Fig 4b**), freedom from major amputation was 94.1% (SE ± 1.51; CI, 50–56) (**Fig E1a**, available online on the article's Supplemental Material page at *www.jvir.org*.), and freedom from clinical TLR was 94.1% (SE ± 1.19; CI, 51–56) (**Fig E1b**, available online at *www.jvir.org*). No significance was observed between DCB and POBA in terms of survival ($P = .67$), primary patency ($P = .78$),

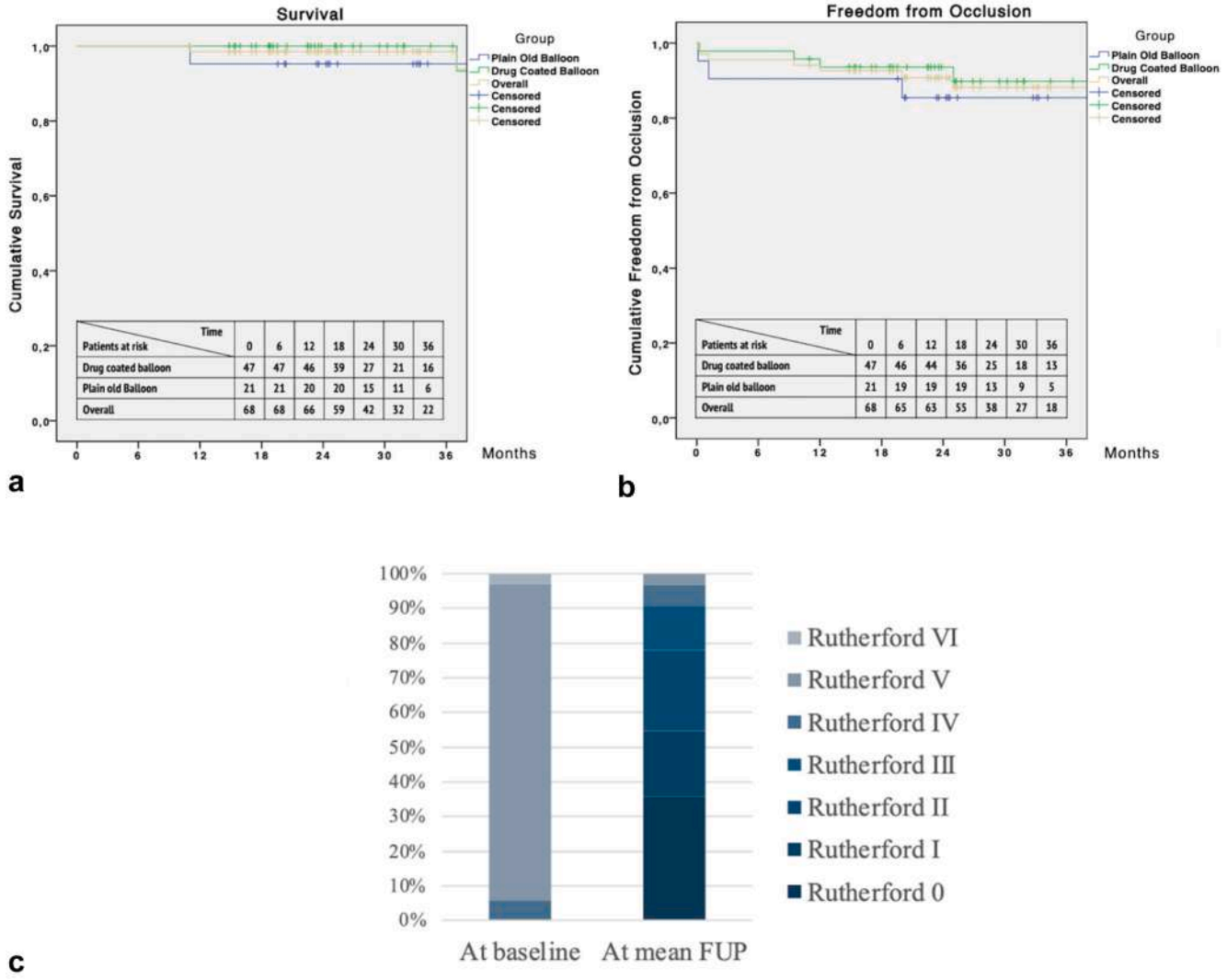

Figure 4. Outcomes of this study. **(a)** Survival Kaplan-Meier curve at 36 months. **(b)** Freedom from occlusion Kaplan-Meier curve at 36 months. **(c)** Rutherford category changes from baseline. For all curves, the number of subjects at risk is listed inside the graph area, and standard error is <10%. For all curves, no significant differences are reported between the drug-coated balloon and plain old balloon groups. FUP = follow-up.

freedom from major amputation ($P = .68$), or freedom from clinical TLR ($P = .99$).

A total of 22 (32.35%) minor amputations were required—15 during the perioperative period and 7 during follow-up. At the 3-year follow-up, the estimated overall freedom from minor amputation was 71.6% (SE ± 2.95; CI, 33–45) (**Fig E1c**, available online at *www.jvir.org*). No significant differences were observed between the DCB and POBA groups ($P = .99$).

At the mean follow-up, among the 64 patients without major amputation, the clinical Rutherford categories were 0 in 23 (35.94%), 1 in 12 (18.75%), 2 in 15 (23.44%), 3 in 8 (12.5%), 4 in 4 (6.25%), and 5 in 2 (3.13%), showing a significant improvement compared with baseline ($P < .001$). A significant difference was found between the baseline ABI and the ABI at a mean follow-up of 0.29 (SD ± 0.06; IQR, 0.23–0.32) versus 0.66 (SD ± 0.18; IQR, 0.56–0.81; $P < .001$; **Fig 4c**).

DISCUSSION

PAD is a widespread condition associated with chronic limb-threatening ischemia and an increased risk of limb loss. Current evidence supports the use of endovascular approaches such as PTA, especially in advanced stages of PAD. This approach is particularly suitable for patients who are not candidates for conventional open surgery and involves the use of DCBs or POBA. The clinical relevance of postangioplasty dissections has become increasingly recognized because of their substantial impact on clinical outcomes. The prevalence of postangioplasty dissections is high, particularly after SFA angioplasty. However, data on the incidence of infrapopliteal postangioplasty dissections are limited, primarily due to smaller vessel size and diagnostic challenges (3,4,8–10). Diagnostic imaging tools such as intravascular US have been used to detect postangioplasty dissections, revealing a higher incidence after balloon angioplasty (11,12). Furthermore, studies following PTA often exclude patients with preexisting postangioplasty dissections; however, it can be argued that such dissections occur in nearly all balloon angioplasty procedures, regardless of the type of balloon used. Available studies have shown no significant difference in postangioplasty dissection prevalence between DCB and POBA (13,14), aligning with current findings. The mechanism underlying postangioplasty dissection development remains under investigation. It is believed to be related to vessel trauma during PTA, which can cause vessel wall damage and varying degrees of dissection. The process involves not only plaque compression and redistribution but also the fissuring and separation of the intima from the media layer. Lumen gain is primarily secondary to dissection, which may be confined to the intima or extend into the media or adventitia. The subsequent inflammatory response and mechanical forces can further damage the vessel wall (15–17). The extent of damage after PTA can range from simple plaque rupture to flow-limiting dissections. Accurate classification and diagnosis of postangioplasty dissections remain challenging because of the limitations of angiography and lack of standardized classification system (1).

The widely used angiographic dissection grading scale from the National Heart, Lung, and Blood Institute, originally developed for coronary arteries, has limitations when applied to peripheral arteries owing to its complexity and lack of specific guidance for different dissection grades (18). To address this, alternative systems such as the Kobayashi classification—based on lumen patency (4)—and the intravascular US–based classification proposed by Shammas et al (12) have been suggested. The 2021 Delphi consensus classification, known as DISFORM, was specifically developed for postangioplasty dissections. It considers parameters such as diameter reduction, spiral morphology, flow impairment, and dissection morphology, providing a pragmatic framework for treatment decisions (6). In advanced stages of postangioplasty dissections, there is an increased risk of intraprocedural and postprocedural adverse events, especially when associated with hemodynamic alterations. The current management approach for postangioplasty dissections is scaffolding, with a high rate of stent placement associated with severe dissections. A large multicenter study (3) identified PAD in 84% of cases, with many treated using stent placement to improve outcomes. Furthermore, patients managed with angioplasty alone experienced higher rates of adverse events, particularly in severe dissections (3). Emerging therapies such as the Tack Endovascular System (Intact Vascular, Wayne, Pennsylvania) have been developed as promising alternatives to traditional scaffolding. The TOBA III trial demonstrated favorable safety and effectiveness outcomes in patients treated for PAD in the SFA and PPA following DCB angioplasty for claudication and rest pain. Tack placement was associated with sustained freedom from clinically driven TLR and improvements in patient health indicators (19). However, Philips recently discontinued the device due to reports of issues, including failure to resolve dissections, implant migration, and the need for additional procedures to retrieve or remove Tack devices.

Unlike conventional techniques, the CHOCO-STAB method does not initially require stent placement. Instead, it aims to stabilize postangioplasty dissections using the NCB angioplasty. NCB balloons are designed to minimize vessel trauma by limiting balloon expansion through a unique structure that creates segmented inflation zones. This design includes a nitinol constraining framework that forms pillows and grooves, ensuring uniform, controlled, and gentle dilation (20). The pillows facilitate vessel expansion without cutting or scoring, whereas the grooves relieve stress and modify plaque. Although not commonly used as a primary intervention, this technology offers a potential strategy for managing complex dissections. In this study, the NCB was routinely used after POBA or DCB angioplasty when DISFORM III postangioplasty dissections appeared during endovascular procedures. This

scenario remains a matter of debate in the literature, with no strong consensus on management. DISFORM III post-angioplasty dissections are moderately recommended for scaffolding; however, this approach can lead to future adverse events such as stent fracture or occlusion, worsening the mid- and long-term vessel patency. Therefore, in patients with postangioplasty dissection, the possibility of requiring a stent after NCB angioplasty was considered when choosing between initial stabilization and scaffolding. The results of this study show an excellent rate of technical success with this approach, preventing stent placement in 91.2% of cases. Moreover, results appear to be independent of the initial use of POBA or DCB, as the 6 failures are almost equally distributed between the 2 groups. It could be hypothesized that differences in vessel predilation and initial treatment may affect NCB effectiveness; however, outcomes in this study are not in line with this prediction. Additionally, the results of both POBA and DCB were excellent, reflecting the operators' expertise in device selection based on lesion type, extent, and location to optimize balloon performance. Furthermore, a detailed analysis of the DISFORM classification parameters revealed no statistically significant differences between groups, indicating that the final postangioplasty dissection pattern was similar across treatment types. This further supports the effectiveness of NCB use in DISFORM III postangioplasty dissections regardless of the initial vessel treatment. Ultimately, the CHOCO-STAB study indicates that in a small subset (8.8%) of patients, additional scaffolding may be necessary when NCB angioplasty fails to stabilize the dissection. The stents used in these cases were of limited length, further reducing potential adverse events. Further prospective studies are warranted to evaluate the effectiveness of plaque stabilization with NCB angioplasty in other DISFORM grades, especially Grade IV, given its lower primary patency rate compared with DISFORM I-III in midterm phase (21).

This study has several limitations. First, it is a single-center, retrospective, and nonrandomized analysis. Second, the lack of standardized initial vessel predilation and treatment among patients may have influenced the results after NCB use, although the outcomes reported in this series do not support that hypothesis.

Third, there was no core laboratory to adjudicate the angiographic images. Additionally, the study sample size was relatively small. Identification of postangioplasty dissections was performed using angiographic imaging without intravascular US.

Postangioplasty dissection is a frequent and underestimated adverse event associated with worse outcomes. The current indication for moderate and severe postangioplasty dissections remains bailout scaffolding, despite the risks specifically related to the femoropopliteal artery segment. The CHOCO-STAB study demonstrated that NCB angioplasty is a safe treatment option for DISFORM III postangioplasty dissections. The use of NCB was associated with limited need for scaffolding in patients treated with DCB and POBA who presented with postangioplasty dissections. Further studies are necessary to confirm the CHOCO-STAB study findings.

ACKNOWLEDGMENTS

The authors received no financial support for the research, authorship and/or publication for this article.

AUTHOR INFORMATION

From the Vascular Surgery Unit, Azienda Ospedaliera Universitaria Policlinico 'P. Giaccone' (D.M., S.B., M.L.M., E.D., F.P.), Palermo, Italy; Vascular and Endovascular Surgery Department (C.S.), University of Siena, Siena, Italy; and Department of Precision Medicine in Medical, Surgical and Critical Care (F.P.), University of Palermo, Palermo, Italy. Received May 14, 2025; final revision received October 22, 2025; accepted October 31, 2025. Address correspondence to F.P., Vascular Surgery Unit, Azienda Ospedaliera Universitaria Policlinico 'P. Giaccone,' and Department of Precision Medicine in Medical, Surgical and Critical Care, University of Palermo, Via Liborio Giuffrè, 5. 90128 – Palermo, Italy; E-mail: felice.pecoraro@unipa.it

D.M. and S.B. contributed equally to this work and are co-first authors.

F.P. is a consultant for Medtronic. All the other authors have no identified a conflict of interest.

REFERENCES

1. Armstrong EJ, Brodmann M, Deaton DH, et al. Dissections after infrainguinal percutaneous transluminal angioplasty: a systematic review and current state of clinical evidence. J Endovasc Ther 2019; 26:479–489.
2. Caradu C, Lakhlifi E, Colacchio EC, et al. Systematic review and updated meta-analysis of the use of drug-coated balloon angioplasty versus plain old balloon angioplasty for femoropopliteal arterial disease. J Vasc Surg 2019; 70:981–995.e10.
3. Fujihara M, Takahara M, Sasaki S, et al. Angiographic dissection patterns and patency outcomes after balloon angioplasty for superficial femoral artery disease. J Endovasc Ther 2017; 24:367–375.
4. Kobayashi N, Hirano K, Yamawaki M, et al. Simple classification and clinical outcomes of angiographic dissection after balloon angioplasty for femoropopliteal disease. J Vasc Surg 2018; 67:1151–1158.
5. von Elm E, Altman DG, Egger M, Pocock SJ, Gøtzsche PC, Vandenbroucke JP, STROBE Initiative. The Strengthening the Reporting of Observational Studies in Epidemiology (STROBE) statement: guidelines for reporting observational studies. Ann Intern Med 2007; 147: 573–577.
6. Voûte MT, Stathis A, Schneider PA, Thomas SD, Brodmann M, Armstrong EJ, et al. Delphi consensus study toward a comprehensive classification system for angioplasty-induced femoropopliteal dissection: the DISFORM study. JACC Cardiovasc Interv 2021; 14: 2391–2401.
7. Rocha-Singh KJ, Zeller T, Jaff MR. Peripheral arterial calcification: prevalence, mechanism, detection, and clinical implications. Catheter Cardiovasc Interv 2014; 83:E212–E220.
8. Gray WA, Cardenas JA, Brodmann M, et al. Treating post-angioplasty dissection in the femoropopliteal arteries using the Tack Endovascular System: 12-month results from the TOBA II study. JACC Cardiovasc Interv 2019; 12:2375–2384.
9. Razavi MK, Mustapha JA, Miller LE. Contemporary systematic review and meta-analysis of early outcomes with percutaneous treatment for infrapopliteal atherosclerotic disease. J Vasc Interv Radiol 2014; 25: 1489–1496, 1496.e1–e3.
10. Fanelli F, Cannavale A, Corona M, Lucatelli P, Wlderk A, Salvatori FM. The "DEBELLUM"–lower limb multilevel treatment with drug eluting balloon–randomized trial: 1-year results. J Cardiovasc Surg (Torino) 2014; 55:207–216.
11. Isner JM, Rosenfield K, Losordo DW, et al. Percutaneous intravascular US as adjunct to catheter-based interventions: preliminary experience in patients with peripheral vascular disease. Radiology 1990; 175: 61–70.
12. Shammas NW, Torey JT, Shammas WJ. Dissections in peripheral vascular interventions: a proposed classification using intravascular ultrasound. J Invasive Cardiol 2018; 30:145–146.
13. Micari A, Brodmann M, Keirse K, et al. Drug-coated balloon treatment of femoropopliteal lesions for patients with intermittent claudication and ischemic rest pain: 2-year results from the IN.PACT Global Study. JACC Cardiovasc Interv 2018; 11:945–953.

14. Kokkinidis DG, Jeon-Slaughter H, Khalili H, et al. Adjunctive stent use during endovascular intervention to the femoropopliteal artery with drug coated balloons: insights from the XLPAD registry. Vasc Med 2018; 23: 358–364.
15. Gasser TC, Holzapfel GA. Modeling plaque fissuring and dissection during balloon angioplasty intervention. Ann Biomed Eng 2007; 35:711–723.
16. Becker GJ, Katzen BT, Dake MD. Noncoronary angioplasty. Radiology 1989; 170:921–940.
17. Tan M, Urasawa K, Koshida R, et al. Comparison of angiographic dissection patterns caused by long vs short balloons during balloon angioplasty of chronic femoropopliteal occlusions. J Endovasc Ther 2018; 25:192–200.
18. Rogers JH, Lasala JM. Coronary artery dissection and perforation complicating percutaneous coronary intervention. J Invasive Cardiol 2004; 16:493–499.
19. Brodmann M, Wissgott C, Brechtel K, et al. Optimized drug-coated balloon angioplasty of the superficial femoral and proximal popliteal arteries using the Tack Endovascular System: Tack Optimized Balloon Angioplasty (TOBA) III 24-month results in standard and long lesions. Catheter Cardiovasc Interv 2023; 102: 701–712.
20. CLR782: final study report: the Chocolate BAR by TriReme Medical, LLC. Available at: https://www.medtronic.com/content/dam/medtronic-wide/public/united-states/products/cardiac-vascular/cardiovascular/pta-ballons/chocolate-pta-balloon-brocure.pdf. Accessed March 12, 2025.
21. Yamada T, Tokuda T, Yoshioka N, et al. Validation of the usefulness of the diameter reduction, spiral shape, flow impairment, or adverse morphology classification system in real-world clinical practice. J Atheroscler Thromb 2024; 31:148–157.

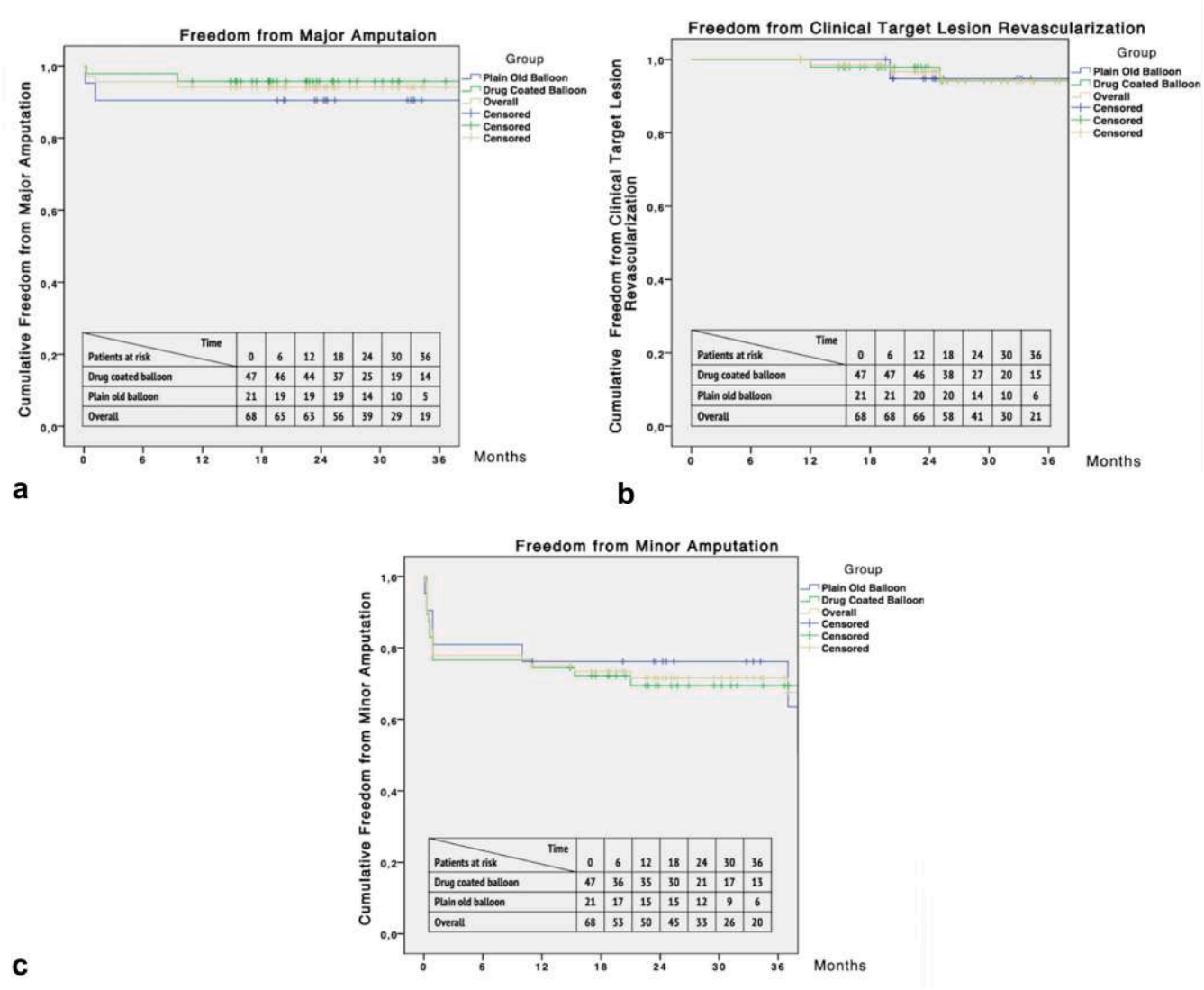

Figure E1. (a) Freedom from clinical target lesion revascularization Kaplan-Meier curve at 36 months. **(b)** Freedom from minor amputation Kaplan-Meier curve at 36 months. **(c)** Freedom from major amputation Kaplan-Meier curve at 36 months. For all curves, the number of subjects at risk is listed inside the graph area, and standard error is <10%. For all curves, no significant differences are reported between the drug-coated balloon and plain old balloon groups.