Femoral Veno–Arterial Extracorporeal Life Support With Minimal or No Heparin

Sary F. Aranki, MD, David H. Adams, MD, Robert J. Rizzo, MD, Gregory S. Couper, MD, Malcolm M. DeCamp, MD, Daniel J. Fitzgerald, CCP, and Lawrence H. Cohn, MD

Division of Cardiac Surgery, Brigham and Women's Hospital, and Department of Surgery, Harvard Medical School, Boston, Massachusetts

Recent technological advances in cardiopulmonary bypass circuits achieving surface bonding with heparin have permitted prolonged extracorporeal life support (ECLS) in experimental studies without the use of systemic anticoagulation. Excessive bleeding and the need for massive transfusions after extended ECLS with systemic heparinization have often led to the development of sepsis and multisystem organ failure. The Carmeda bioactive surface circuit, along with a Bio-Medicus centrifugal pump (Bio-Pump) and the femoral veno–arterial route, were used successfully in 3 patients requiring ECLS between April 1992 and December 1992. In 2 patients the need for ECLS was acute allograft dysfunction after orthotopic cardiac transplantation with no evidence of cellular rejection. Both patients were receiving multiple inotropes and intraaortic balloon counterpulsation; their condition continued to deteriorate rapidly before the initiation of ECLS. The third patient failed to be weaned from cardiopulmonary bypass after myocardial revascularization for ischemic cardiomyopathy. Time on ECLS ranged from 57 to 128 hours. No systemic anticoagulation was used. One patient received no heparin, and the other 2 patients received intermittent heparin infusion to maintain an average activated clotting time of 195 and 214 seconds. Multisystem organ dysfunction present before initiation of ECLS was rapidly reversed, and all patients were weaned successfully without any immediate major complications. The ability to conduct prolonged ECLS without systemic anticoagulation and without repeat sternotomy opens new avenues for the use of this procedure in profound heart failure.

(Ann Thorac Surg 1993;56:149–55)

Prolonged extracorporeal circulatory support that allows for preservation of vital body functions until such time when the supported organs (heart, lung, or both) are repaired or replaced has been the gold standard since the first successful clinical application of extracorporeal life support (ECLS) in 1972 [1]. Unfortunately, this vision was behind the technology of the time for extracorporeal support in general, and for cardiac ECLS in particular. Initial reports of randomized [2, 3] and nonrandomized [4] studies have shown a survival of only 10% [5] to 50% [4] at best after adult ECLS for various indications.

The need for systemic anticoagulation on ECLS, combined with the potential for serious bleeding complications, the need for massive transfusion of blood and blood products, and the development of mediastinitis and sepsis, can convert a potentially hopeful clinical situation into a disastrous one with the inevitable onset of multisystem organ failure and death [5, 6].

Recent technological advances in the form of modern membrane oxygenators, better cannula design, centrifugal pumps, and biocompatible bypass circuits such as the Carmeda bioactive surface (CBAS) have the potential for less morbidity and better survival. This has allowed for prolonged ECLS use in the experimental setting [7] and in a few clinical uses, mainly in Europe [8].

We report on our experience with using the Bio-Medicus centrifugal pump (Bio-Pump) and the Carmeda circuit for prolonged femoral veno–arterial bypass in 3 patients primarily for cardiac support with minimal or no heparin and with favorable outcome.

Material and Methods

Between April, 1992 and December, 1992, three patients required acute circulatory support due to biventricular failure (Table 1). All patients had femoral veno-arterial bypass using a CBAS bioactive circuit (Medtronic Blood System Inc, Anaheim, CA) and a centrifugal Bio-Medicus pump (Bio-Pump; Medtronic, Minneapolis, MN).

Patient 1

A 46-year-old man presented with end-stage cardiac failure secondary to idiopathic cardiomyopathy. He was in United Network for Organ Sharing status 1 in the coronary care unit on multiple inotropes and intraaortic balloon pump counterpulsation for 35 days. He underwent orthotopic transplantation of a heart from a 20-year-old, female, ABO-compatible donor. Ischemia time was 166 minutes. He was weaned off cardiopulmonary bypass (CPB) easily and required minimal inotropic support, and he was weaned from the intraaortic balloon pump on the

Accepted for publication April 12, 1993.

Address reprint requests to Dr Aranki, Division of Cardiac Surgery, Brigham and Women's Hospital, 75 Francis St, Boston, MA 02115.

© 1993 by The Society of Thoracic Surgeons

0003-4975/93/$6.00

Table 1. Patient Characteristics and Outcomes

Patient No.	Age (y)	Diagnosis	Duration of ECLS (h)	Successful Wean	Outcome
1	46	Acute allograft failure	88	+	Discharged home alive and well
2	54	Failure to be weaned off CPB after CABG	57	+	Discharged home alive and well
3	64	Acute allograft failure	128	+	Initially stable for 1 month, then GI bleed/ATN/and multisystem organ failure developed

ATN = acute tubular necrosis; CABG = coronary artery bypass grafting; CPB = cardiopulmonary bypass; ECLS = extracorporeal life support; GI = gastrointestinal.

second postoperative day. A routine echocardiogram performed on the third postoperative day showed normal biventricular function. He was receiving steroids and cyclosporine with adequate levels. On the 7th postoperative day he had his first endomyocardial biopsy. After the procedure he reported feeling unwell. An echocardiogram showed no pericardial effusion but marked reduction in ventricular function, and he was given a gram of methylprednisolone sodium succinate (Solu-Medrol; Upjohn, Kalamazoo, MI) intravenously immediately. His condition deteriorated rapidly over the next 2 hours. He became profoundly hypotensive, acidotic, and oliguric. He was intubated, given dopamine, amrinone, and epinephrine, and placed on an intraaortic balloon pump. There was no improvement, and he remained in severe hemodynamic compromise with a mean blood pressure of 40 mm Hg, anuria, and severe acidosis. He was placed on ECLS. The diagnosis was presumed to be rejection. He was treated with three pulses of methylprednisolone, 1 g for 3 days, and OKT3, 5 mg per day for 14 days. The biopsy showed no evidence of cellular rejection; however, there were marked ischemic changes with coagulative necrosis. His ECLS course was uncomplicated, and he was weaned successfully 86 hours later with intact multisystem function. Subsequent endomyocardial biopsy showed complete resolution of the ischemic changes. He was discharged home after 33 days. He is alive and well 8 months later. The final diagnosis was acute allograft dysfunction, with no evidence of cellular rejection.

Patient 2

A 58-year-old man with a long history of angina who had an anterolateral myocardial infarction presented in October 1992 with an acute inferior myocardial infarction, complicated by complete heart block. He suffered another myocardial infarction one month later. He was admitted to the hospital with congestive heart failure and postinfarction angina, and required a temporary transvenous pacemaker. His catheterization showed severe left main disease and triple-vessel coronary artery disease with an estimated ejection fraction on left ventriculogram of 0.20. He had moderate mitral regurgitation and elevated filling pressures. His echocardiogram showed moderately dilated left ventricle with moderate to severe depression of overall left ventricular contractile function. He was transferred for assessment for possible cardiac transplantation. Because of his ongoing ischemia and his borderline myocardial function that did not meet transplant criteria, we elected to perform coronary artery revascularization. He was taken to the operating room, where a triple-vessel bypass was performed using saphenous veins only. He was not able to be weaned off CPB in spite of intraaortic balloon counterpulsation and multiple inotropes. After 3½ hours of CPB we decided to place him on femoral veno–arterial ECLS. The heparin was reversed with protamine, and the thoracic cannulas were removed. Because of the prolonged bypass time he had diffuse bleeding. His ECLS course was notable for groin exploration for bleeding from around the arterial cannula. He was returned to the operating room and successfully weaned after 57 hours; his groin was decannulated, and his sternotomy wound was reopened and explored for bleeding. The intraaortic balloon pump was removed after 48 hours, and he was extubated 24 hours later. His final echocardiogram before discharge showed no deterioration of his left ventricular function as compared with preoperatively. He was discharged home 12 days after his successful ECLS. The final diagnosis was acute cardiac failure after coronary artery bypass grafting and failure to be weaned from cardiopulmonary bypass.

Patient 3

A 64-year-old man with end-stage cardiac failure secondary to ischemic and dilated cardiomyopathy was in United Network for Organ Sharing status 1 in the coronary care unit, ventilated, receiving multiple inotropes, and on intraaortic balloon counterpulsation for 10 days. He underwent orthotopic transplantation of a heart from a 19-year-old male, ABO-compatible donor. Ischemic time was 202 minutes. He was weaned off CPB with minimal inotropes. He was receiving a regimen of steroids and cyclosporine for immune suppression. A routine echocardiogram done on the first postoperative day showed normal biventricular function. On the second postoperative day he became suddenly bradycardic with a decrease in blood pressure. He responded to isoproterenol infusion, and his blood pressure and indices recovered rapidly. He was weaned from the intraaortic balloon pump, and it was about to be removed, when the cardiac index decreased to 1.5 $L \cdot min^{-1} \cdot m^{-2}$ with a corresponding

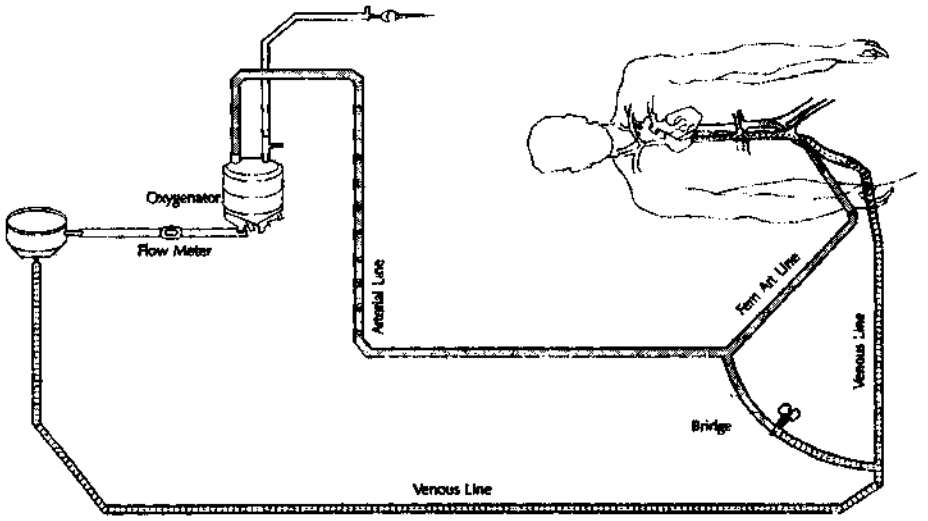

Fig 1. Schematic presentation of the extracorporeal life support circuit showing the Bio-Medicus pump, the Maxima oxygenator, and the long venous line in the right atrium. The bridge allows for circulation of blood to prevent clot formation in case the circuit has to be used again. All the above components are coated with the Carmeda bioactive surface. (Fem Art = femoral arterial.)

decrease in mixed venous saturation. The intraaortic balloon pump was turned back to full augmentation with no improvement. He continued to deteriorate with an increasing inotrope requirement. An echocardiogram showed marked deterioration in ventricular function compared with the previous day, with no evidence of pericardial effusion. The diagnosis was presumed to be acute rejection, and he was given 1 g of Solu-Medrol intravenously. His condition continued to deteriorate over the course of the next 4 hours, becoming profoundly hypotensive, oliguric, and acidotic with a poor cardiac index and mixed venous saturations. He was placed on ECLS. The endomyocardial biopsy showed exactly the same findings as in patient 1, and he received the same treatment as patient 1. His ECLS course was complicated by bleeding from the femoral arterial site, for which he required return to the operating room for repositioning of the arterial cannula. He was weaned successfully off ECLS after 129 hours with intact multisystem organ function. Four weeks later, however, a large gastrointestinal bleed and acute renal failure requiring hemodialysis developed. Multisystem organ failure developed, and all support was withdrawn on the request of his family. The final diagnosis was acute allograft failure with no evidence of cellular rejection.

Operative Technique

All 3 patients were placed on ECLS through the femoral veno–arterial route. The CBAS circuits were used (Fig 1). A 17F Bio-Medicus arterial cannula was used to cannulate the common femoral artery by an open technique through a transverse incision. For the femoral vein a 27F Bio-Medicus cannula was used for cannulating the long saphenous vein at its junction with the common femoral vein. It was advanced over a guidewire and an obturator and positioned in the right atrium. Distal leg ischemia and venous congestion were treated in 1 patient with a 10F Bio-Medicus cannula inserted in the profunda branch distally and connected to the arterial side of the circuit, and a 10F Bio-Medicus cannula inserted in the femoral vein distally and connected to the venous side of the circuit. This relieved the ischemia immediately, and markedly reduced the congestion from the distal limb. Percutaneous femoral cannulation was not used because of the increased incidence of atherosclerotic femoral artery disease in this patient population. We believe that an open technique is far superior because it allowed for direct vision cannulation of a nondiseased portion of the artery and therefore reduced the potential for arterial dissection. In addition, larger arterial and venous cannulas can be used by the open technique to achieve better drainage and lower arterial resistance.

All patients were managed on the surgical intensive care unit. A perfusionist was in constant attendance to run the pump during the duration of ECLS, as we have no other trained personnel in our institution for this purpose.

The Bio-Pump

The Biomedicus Medtronic 540 Bio-Console was used in all 3 patients. This has a centrifugal, magnetically driven Bio-Pump, which can operate from a standard alternating-current line, an internal battery pack, or a model 100 emergency handcrank. This device is sensitive to preload and afterload and has a built-in alarm system that can be programmed to give a warning when a sudden change in the flow occurs due to either a sudden fall in circulating blood volume, air in the circuit, or an increase in the resistance in the arterial circuit or the patient. This device is ideal because it is a compact system that is easily portable and requires minimal adjustments once in operation. The Bio-Pump is also CBAS coated.

Type of Oxygenator

A membrane oxygenator is always used when prolonged ECLS in required. A CBAS-coated Maxima oxygenator

Table 2. Efficiency of Membrane Oxygenation

Patient No.	Premembrane		Postmembrane		Radial artery		Mean sweep gas flow (L/min)
	PO_2 (mm Hg)	PCO_2[a] (mm Hg)	PO_2 (mm Hg)	PCO_2 (mm Hg)	PO_2 (mm Hg)	PCO_2 (mm Hg)	
1	49	37	311	34	203	29	3[b]
							5.8[c]
2	42	43	299	34	140	33	6[b]
3	40	51	343	30	188	35	3.5[b]
							3.3[c]

[a] PO_2/PCO_2 values are mean values. [b] Maxima oxygenator. [c] Scimed oxygenator.
PCO_2 = carbon dioxide tension; PO_2 = oxygen tension.

(Medtronic Blood System, Anaheim, CA) is initially used. This is a hollow-fiber membrane oxygenator with a relatively small surface area (2 cm^2), and has a limited life span. It has a built-in heat exchanger that will allow rewarming the patient in the initial period of ECLS. This oxygenator is used without heparin. The disadvantage of this oxygenator is that it may need to be changed frequently during prolonged support. It holds 450 mL of blood, which is usually lost when the oxygenator is changed. Signs of oxygenator failure consist of foaming of the blood as it passes through the oxygenator, external leaking of plasma, and ineffective arterial oxygenation or carbon dioxide clearance. Changing of the oxygenator can be performed easily by one perfusionist, and it takes approximately 30 seconds.

A Scimed Oxygenator (Scimed, Minneapolis, MN) is a large surface area membrane oxygenator (4.5 cm^2) that can hold 550 mL of blood. It is made of silicone rubber sheaths cylindrically wrapped around a polycarbonated plastic spool. It is designed for prolonged ECLS use. It is not Carmeda coated, as the current technology does not apply to silicone rubber, and therefore its use requires anticoagulation, which does not necessarily have to be systemic if high flows are achieved. This oxygenator is used when the patient's condition is stable enough to begin heparin administration or when the Maxima oxygenator has failed. It also has a built-in heat exchanger, which is rarely used.

An oxygen blender (Sechrist, Anaheim, CA) is used to combine air and oxygen to achieve an inspired oxygen fraction of 1.0. This is directed through the oxygenator at variable flow rates (sweep gas) ranging from 2 to 8 L/min (Table 2), which in turn determines the rate of carbon dioxide clearance. The flow rate or the estimated optimum ventilation (EOV) is adjusted using the following formula:

$$EOV = \text{current } O_2 \text{ flow rate (sweep gas)} \times PaCO_2/\text{desired } PCO_2$$

Where $PaCO_2$ = arterial carbon dioxide tension.

Flow Rates and Hemodynamics

Flow rates and hemodynamic values are shown in Table 3. The flow rates are determined mainly by the preload (preoxygenator) venous oxygen saturations and by the circuit and patient resistance. Central venous pressure is kept about 5 mm Hg or more by adding blood, plasma, or crystalloids as indicated. The venous saturations are kept about 70%. The flow rates on ECLS usually account for 70% to 80% of the resting cardiac output. If the venous line shatters or "sumps," this means that either the patient is hypovolemic or the venous line is not in the ideal position and, therefore, should be repositioned.

The long Bio-Medicus femoral venous cannulas are thin walled, with reduced external to internal diameter ratio and wire reinforcing, which prevents kinking. We have achieved adequate venous drainage and flow rates through these cannulas. The average flow rate using a 27F cannula was 3.3 L/min as reported previously [9]. This flow rate is very satisfactory on ECLS because higher flow rates may cause an increase in pressure on the arterial side of the cannula and may cause leakage through the oxygenator. In addition, it is beneficial to have blood circulating through the heart and ventilated lungs [10].

All 3 patients had an intraaortic balloon pump in place at the start of ECLS. This was kept in place to produce

Table 3. Extracorporeal Life Support Hemodynamics[a]

Patient No.	Bio-Pump Flow Rate (L/min)	Mean Flow Index ($L \cdot min^{-1} \cdot m^{-2}$)	Mean RA Pressure (mm Hg)	PA Diastolic Pressure (mm Hg)	Mean BP (mm Hg)
1	1.9–5.7 (4.6)	0.9–2.7 (2.2)	6–15 (9)	7–22 (15)	55–115 (90)
2	1.5–5 (3.7)	0.7–2.3 (1.7)	10–16 (12)	7–24 (17)	46–117 (75)
3	1.5–4.5 (3.3)	0.8–2.4 (1.8)	3–14 (6)	5–19 (12)	60–114 (84)

[a] Values are shown as range with mean in parentheses.
BP = blood pressure; PA = pulmonary artery; RA = right atrial.

Table 4. Extracorporeal Life Support Anticoagulation

Patient No.	Initial Bolus Heparin Dose (U)	Heparin Infusion (U/h)		ACT (s)	
		Range	Mean	Range	Mean
1	1,000	1,000–2,000	1,250	150–251	195
2	0	0	0	115–135	127
3[a]	2,000	400–1,500	960	149–534	214

[a] No heparin infusion for first 9 hours and last 37 hours; 2,000 U intravenous bolus given 2 hours before weaning, achieving an ACT of 200 seconds.
ACT = activated clotting time.

pulsatile perfusion, which is beneficial to the function of other organs, especially the kidneys [6].

Anticoagulation Management

Table 4 shows the anticoagulation management during ECLS. Heparin was given to patients 1 and 3 as an intravenous infusion, achieving a sufficient degree of heparinization as shown in the table. Patient 3 had no heparin for the first 9 hours, and heparin administration was stopped for the last 37 hours after bleeding complications around the femoral arterial cannula site. A Maxima oxygenator was used during the period of no heparinization. Patient 2 received no heparin bolus or infusion. He required groin exploration twice, and sternal exploration for bleeding. We elected not to give him any heparin, and a Maxima oxygenator was used for the entire duration of ECLS.

In all 3 patients the general policy was that if there was any bleeding or possible complications of anticoagulation, no heparin was given. During this period a Maxima oxygenator was used. We preferred to use low-dose heparin not only for CPB, but also for prevention of deep venous thrombosis, especially in the presence of the long venous cannula in the femoral vein and inferior vena cava, which may cause distal stasis. Indeed, in patient 3, venous stasis was so severe that the whole leg became congested and a distal venous cannula was inserted to relieve this congestion. All 3 patients had noninvasive venous studies after termination of ECLS, and none had evidence of deep venous thrombosis.

Transfusion Requirements

Patient 2 had prolonged CPB before placement on ECLS. He had a severe coagulopathy and required mediastinal and groin exploration on several occasions. He required a total of 34 units of red blood cells, 20 units of fresh frozen plasma, and 8 units of platelets. Patients 1 and 3 required a daily average of 2 units of red blood cells and 1 unit (6-pack) of platelets to keep the platelet count greater than $70 \times 10^3/\mu L$. However, patient three had a significant bleed around his femoral arterial cannulation site which required exploration and on that particular day he required 15 units of red cells and 11 units of fresh frozen plasma. The inevitable hemolysis and platelet destruction that occurs with extended ECLS explains the need for daily transfusions. This hemolysis is reflected in plasma hemoglobin concentration that ranged between 14 and 35 mg/dL (normal <5 mg/dL). Also, there is an obligatory loss of 450 to 550 mL of blood on changing the oxygenator, which has to be eventually replaced.

Pulmonary Management

In all three patients ventilation through the native lungs was maintained at a minimum with an inspired oxygen fraction range of 0.40 to 0.60, tidal volume of 75 to 100 mL, a respiratory rate of 4 to 10 per minute, 5 cm H_2O of positive end-expiratory pressure, and a positive inspiratory pressure of lessthan 30 cm H_2O. This minimal ventilation is important, because in all 3 patients the heart was ejecting blood, as demonstrated by the transesophageal echocardiogram (opening of the aortic and pulmonary valves) and as indicated by the pulmonary artery pressures. In addition, the indication for initiating ECLS was cardiac failure and not pulmonary failure. Therefore, it was important to use native ventilation in the presence of lung perfusion for the purpose of saturating the blood. This allows for better systemic saturation when mixing of blood occurs in the ascending aorta (see Table 2). There is also some evidence that allowing the lungs to function at this minimal level is actually beneficial and prevents subsequent parenchymal damage [11].

Supportive Measures

If ECLS is started before the onset of irreversible multisystem organ damage and failure, all transient dysfunction of these systems are reversible. Sedation was withheld initially, and when there was no evidence of cerebral dysfunction, all 3 patients had intravenous infusion of analgesia, sedatives, and muscle relaxants to prevent any sudden movement by the patient that could interfere with the ECLS performance.

All 3 patients were oliguric before ECLS, and all were started on a furosemide infusion ($0.5\ mg \cdot kg^{-1} \cdot h^{-1}$), hemofiltration, or both during the duration of support. This resulted in a brisk urine output and normalization of renal function at the time of weaning. In patients 1 and 3 cyclosporine administration was stopped during this period because adequate immune suppression in the form of Solu-Medrol and OKT3 was given. Cyclosporine administration was resumed when the urine output was adequate and after normalization of renal function.

Total parentral nutrition, antibiotic cover, prevention of bed sores, and pneumatic boots for deep venous thrombosis prophylaxis were used as early as possible in all

patients and continued throughout the duration of bypass.

Comment

The current technology of CPB allows a wide variety of cardiac procedures to be performed with an acceptable risk even though CPB is nonphysiologic and can trigger a cascade of potentially harmful changes due to contact of blood and its cellular elements with foreign and noncompatible surfaces. These changes include activation of the coagulation cascade, platelets, leukocytes, and complement activation [6]. The severity of these responses depends in part on the surface of the devices used and on the length of CPB. The need for anticoagulation in the form of heparin, to prevent thrombus formation on contact of blood with foreign surfaces, is an essential part of conducting safe CPB. However, bleeding complications are common with anticoagulation [5] and more importantly due to the upset of the delicate balance between normal hemostasis and thrombogenesis caused by CPB.

The CBAS, introduced by Larm and associates [12] in 1983, is the most promising attempt to achieving a biocompatible CPB surface that will lessen the adverse effects mentioned above. Earlier attempts to bind heparin on CPB circuits failed to demonstrate thromboresistance because either heparin was unstable and was washed out upon contact with blood, as with the various ionic preparations [13], or the heparin molecule was nonfunctional because of covalent bonding with the functional portion of heparin [14]. The CBAS advantage over other technologies is that it is stable or nonleaching and the active anticoagulant portion on the heparin molecule is preserved. This is achieved by a process called end-point attachment of heparin by covalent bonding at the terminal aldehyde group, thus preserving the specific antithrombin binding site of the reduced heparin molecule, which is readily exposed to blood [12]. The resulting surface is thromboresistant, and mimics the intact vascular endothelium. In an experimental study, the CBAS surface remained functional and free of thrombi for 120 hours of prolonged CPB support in sheep without any systemic heparinization [7]. Other potential benefits of CBAS are reduced platelet aggregation and activation [15], reduced leukocyte and complement activation [16, 17], and reduced fibrin deposition and fibrinolysis [15, 18]. Experimental [19] and clinical studies [8] are encouraging for the use of CBAS in prolonged bypass situations such as ECLS.

Extracorporeal life support is a complex, labor-intensive, and multidisciplinary therapy that involves continuous interaction between physicians, perfusionists, nurses, and a multitude of other support service personnel. The salient features of successful ECLS as demonstrated in our 3 patients were the realization that the clinical situations encountered were potentially reversible, initiation of ECLS in a timely fashion before the onset of irreversible multisystem organ damage, use of the femoral veno–arterial approach to avoid an open sternotomy, continuing intraaortic balloon pump counterpulsation to achieve pulsatile flow, and resting the lungs with a minimal level of ventilation and perfusion. Other general support aspects were the use of hemofiltration and furosemide infusion to improve urine output, initiation of nutrition as early as possible, the use of antibiotics throughout the duration of ECLS, and the use of pneumatic boots to prevent venous congestion and deep venous thrombosis. This technique allowed excellent decompression of the left ventricle documented by transesophageal echocardiogram.

We believe that avoidance of an open or repeated sternotomy and avoidance of systemic anticoagulation are major contributors to a successful ECLS course. Since the initial report of ECLS in 1972 [1], the undesirable results of such procedures were attributed mainly to bleeding complications, mediastinitis, and sepsis with the inevitable onset of multisystem organ failure [6]. Prolonged hospital stay and rehabilitation are inevitable after successful weaning from ECLS. All patients had substantial muscle weakness that prevented them from independent mobilization for 5 to 15 days after successful weaning. Therefore, intensive physical therapy with muscular retraining is an essential part of recovery, and adequate caloric intake should be continued using enteral or parenteral feeding if necessary.

In conclusion, modern technology of biocompatible surfaces and improved pump and cannula designs allow a prolonged ECLS course without the need for systemic anticoagulation, with its undesirable effects, and allow a possible reduction in nonphysiologic effects that arise from the activation of the various blood cells. Avoiding an open or repeated sternotomy markedly reduces the risk of mediastinitis, sepsis, multisystem organ failure, and death.

References

1. Hill JD, O'Brien TG, Murray JJ, et al. Extracorporeal oxygenation for acute posttraumatic respiratory failure (shock-lung syndrome): use of the Bramson membrane lung. N Engl J Med 1972;286:629–34.
2. Zapol WM, Snider MT, Hill JD, et al. Extracorporeal membrane oxygenation in severe respiratory failure. JAMA 1979; 242:2193–6.
3. Pratt PC, Vollmer RT, Shelburn JD, et al. Pulmonary morphology in a multihospital collaborative extracorporeal membrane oxygenation project. Am J Pathol 1979;95:191–212.
4. Anderson HL, Delius RE, Sinard JM, et al. Early experience with adult extracorporeal membrane oxygenation in the modern era. Ann Thorac Surg 1992;53:553–63.
5. NHLBI-NIH. Extracorporeal support for respiratory insufficiency. Bethesda, MD: DHEW publication, 1980.
6. Bartlett RH. Extracorporeal life support for cardiopulmonary failure. Curr Probl Surg 1990;27:621–705.
7. Mottaghy K, Oedekoven B, Pöppel K, et al. Heparin free long-term extracorporeal circulation using bioactive surfaces. ASAIO Trans 1989;35:635–7.
8. Peters J, Radermacher P, Kuntz M, et al. Extracorporeal CO_2 removal with a heparin coated artificial lung. Intensive Care Med 1988;14:578–84.
9. Jones RC, Fitzgerald D, Cohn LH. Reoperative cardiac surgery using a new femoral venous right atrial cannula. J Cardiac Surg 1990;5(3):170–3.
10. Koul B, Willen H, Sjoberg T, Wetterberg T, Kugelberg J, Steen S. Pulmonary sequelae of prolonged total venoarterial

bypass: evaluation with a new experimental model. Ann Thorac Surg 1991;51:794–9.
11. Koul B, Wollmer P, Willen H, Kugelberg J, Steen S. Venoarterial extracorporeal membrane oxygenation—how safe is it? Evaluation with a new experimental method. J Thorac Cardiovasc Surg 1992;104:579–84.
12. Larm O, Larsson R, Olsson P. A new non-thrombogenic surface prepared by selective covalent binding of heparin via a modified reducing terminal residue. Biomater Med Dev Artif Organs 1983;11:161–3.
13. Gott VL, Whiffen JD, Dutton RC. Heparin bonding on colloidal graphite surfaces. Science 1963;142:1297.
14. Schmer G. The biological activity of covalently immobilized heparin. Trans Am Soc Artif Organs 1972;18:321.
15. Kundu SK, Klein MD, Whittlesey GC, Barmatoski SP, Salley SO. Quantitative scanning electron microscopy for the evaluation of thrombosis in extracorporeal circuits. ASAIO Trans 1988;34:568–72.
16. Videm V, Nilsson L, Venge P, Svennevig J. Reduced granulocyte activation with heparin coated device in an in vitro model of cardiopulmonary bypass. Artif Organs 1991;15(2): 90–5.
17. Videm V, Svennevig JL, Fosse E, et al. Reduced complement activation with heparin-coated oxygenator and tubings in coronary bypass operations. J Thorac Cardiovasc Surg 1992; 103:806–13.
18. Von Segesser L, Weiss B, Gallino A, et al. Superior hemodynamics in left heart bypass without systemic heparinization. Eur J Cardiothorac Surg 1990;4:384–9.
19. Koul B, Vesterqvist O, Egberg N, Steen S. Twenty-four–hour heparin-free veno–right ventricular ECMO: an experimental study. Ann Thorac Surg 1992;53:1046–51.

Southern Thoracic Surgical Association: Fortieth Annual Meeting

The Fortieth Annual Meeting of the Southern Thoracic Surgical Association will be held at Marriott's Bay Point Resort, Panama City Beach, Florida, November 4–6, 1993. The Postgraduate Course will be held the mornnig of Thursday, November 4, 1993, and will provide in-depth coverage of thoracic surgical topics selected primarily as a means to enhance and broaden the knowledge of practicing thoracic and cardiac surgeons.

Advance registration forms, hotel reservation forms, and details regarding transportation arrangements, as well as the complete meeting program, will be mailed to Association members. Nonmembers wishing to receive information on attending the meeting should write to the Association's Secretary, Hendrick B. Barner.

Hendrick B. Barner, MD
Secretary-Treasurer
Southern Thoracic Surgical Association
401 North Michigan Avenue
Chicago , IL 60611-4267