Article published online: 2024-11-07

Management of Iliofemoral Venous Stent Thrombosis

Teodora Bochnakova, MD[1]

[1] Department of Interventional Radiology, Dotter Institute of Interventional Radiology, Oregon Health and Science University, Portland, Oregon

Address for correspondence Teodora Bochnakova, MD, Department of Interventional Radiology, Dotter Institute of Interventional Radiology, Oregon Health and Science University, 800 NW Spring Avenue, Portland, OR 97229 (e-mail: Tnb5002@gmail.com).

Semin Intervent Radiol 2024;41:424–429

Stenting has become more prevalent in recent years as a durable treatment to reestablish venous flow in cases of iliofemoral deep vein thrombosis (DVT). Venous stents have helped alleviate symptoms of both acute DVT and chronic postthrombotic syndrome of the lower extremities, such as pain, edema, and chronic skin changes leading to ulceration.[1] However, despite the development of vein-specific, self-expanding nitinol stents such as the Venovo (BD Interventional), Zilver Vena (Cook Medical), and Abre (Medtronic), achieving long-term venous stent patency remains a complex challenge. The incidence of repeat interventions in patients with iliofemoral venous stents has been reported between 11 and 33.5% of cases due to recurrence of symptoms in the setting of in-stent stenosis, stent compression, and complete occlusion.[2,3] Patients treated with dedicated venous stents for thrombotic disease have shown significantly lower primary patency rates compared with those stented for nonobstructive stenotic lesions of the iliac vein (70 vs. 93.6% in the VERNACULAR Trial and 70.4 vs. 97.1% in the ABRE Study) at 3 years.[4,5] This complexity underscores the need for close follow-up and continuous imaging surveillance of these patients who tend to return with in-stent thrombosis and recurrent lower extremity symptoms.

Some degree of endothelialization, remodeling, and narrowing along the stent wall inevitably occurs and is postulated to stabilize by 3 months after stenting.[2] However, progression of this process to hemodynamically significant stenosis >50% or complete thrombosis has been attributed to numerous causes, including inadequate inflow veins from the lower extremity that are necessary to supply blood flow into the stent to keep it open, residual outflow stenosis of the inferior vena cava (IVC) or common iliac vein, noncompliance or failure of anticoagulation, or mechanical malfunction of the stent[6–8] (►**Fig. 1**). While data on the exact mechanism of in-stent stenosis remains unclear, several observations stay at the forefront. Histologic samples from animal models with in-stent stenosis have shown a layer of neointima within the stent as early as 1 week after implantation and intimal thickening with fibrotic changes and smooth muscle proliferation by 8 weeks.[9]

Diagnosis

Because in-stent thrombosis most typically occurs soon after placement (3–6 months), surveillance with ultrasound of iliofemoral stents is critical, especially within the first few months.[10] While exact protocols vary among providers, ultrasound of the IVC and iliac veins can be performed 1, 3, and 6 months after intervention and annually thereafter unless new or worsening lower extremity symptoms develop.[3,11]

With time, non–flow-limiting mural thickening or neointimal hyperplasia may develop along the wall of the stent, which can be easily identified on transabdominal ultrasound. This mural thickening often correlates with similar findings on surveillance venography and intravascular ultrasound (IVUS; ►**Fig. 2**). The degree of in-stent stenosis on imaging alone should not determine whether to intervene. Instead, intervention should be guided by the severity of recurrent symptoms. In an asymptomatic patient, neointimal hyperplasia can be monitored conservatively with routine imaging to document stability over time. However, if this stenosis is greater than 50% occlusive or has significantly progressed from the prior surveillance ultrasound, intervention should be considered, especially if symptoms of postthrombotic syndrome have recurred.[3]

If in-stent occlusion is evident on ultrasound, CT, or MR venography can ascertain the extent of thrombosis and evaluate the underlying etiology of thrombosis for preprocedural planning.

Intervention

Improvement in symptoms after reintervention for in-stent stenosis has been reported in the literature, with secondary patency rates ranging from 19 to 70%.[2,3]

Issue Theme Vascular Anomalies; Guest Editor, Kari J. Nelson, MD, FSIR, FAMWA

© 2024. Thieme. All rights reserved.
Thieme Medical Publishers, Inc., 333 Seventh Avenue, 18th Floor, New York, NY 10001, USA

DOI https://doi.org/10.1055/s-0044-1791191.
ISSN 0739-9529.

This document was downloaded for personal use only. Unauthorized distribution is strictly prohibited.

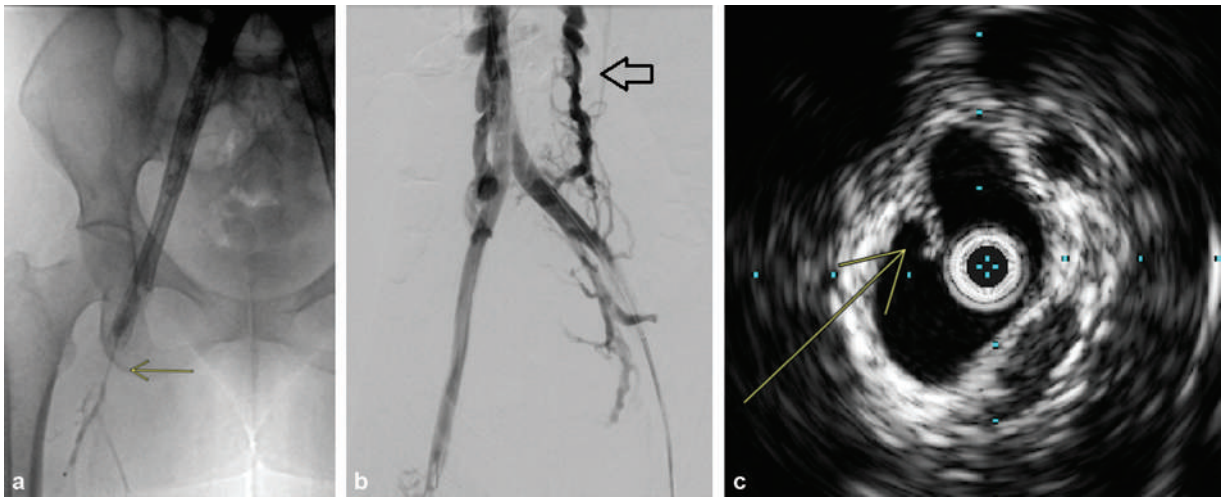

Fig. 1 A venogram performed for in-stent thrombosis shows recalcitrant inflow stenosis of the common femoral vein (**a**, arrow). Despite angioplasty of the common femoral stenosis, the stents rethrombosed at 2 weeks. A venogram in a different patient also performed for in-stent thrombosis shows large, dilated collateral lumbar veins (**b**, arrow) corresponding to hemodynamically significant outflow stenosis of the inferior vena cava with synechiae on intravascular ultrasound (**c**, arrow).

If a patient is acutely symptomatic with in-stent thrombosis, early intervention is critical, as outcomes for chronic DVT remain inferior.[12] Furthermore, providers should consider early venography with potential intervention if a patient is symptomatic with ultrasound findings limited to focal hemodynamically significant stenosis to prevent complete occlusion.

Thrombolysis

Many operators have moved away from overnight thrombolysis, and alternatively, they have utilized single-procedure thrombectomy techniques to minimize lytic dose and time spent in intensive care unit monitoring.[13] However, overnight thrombolysis remains a sound option in managing acute clots within a stent, whether as an isolated first step

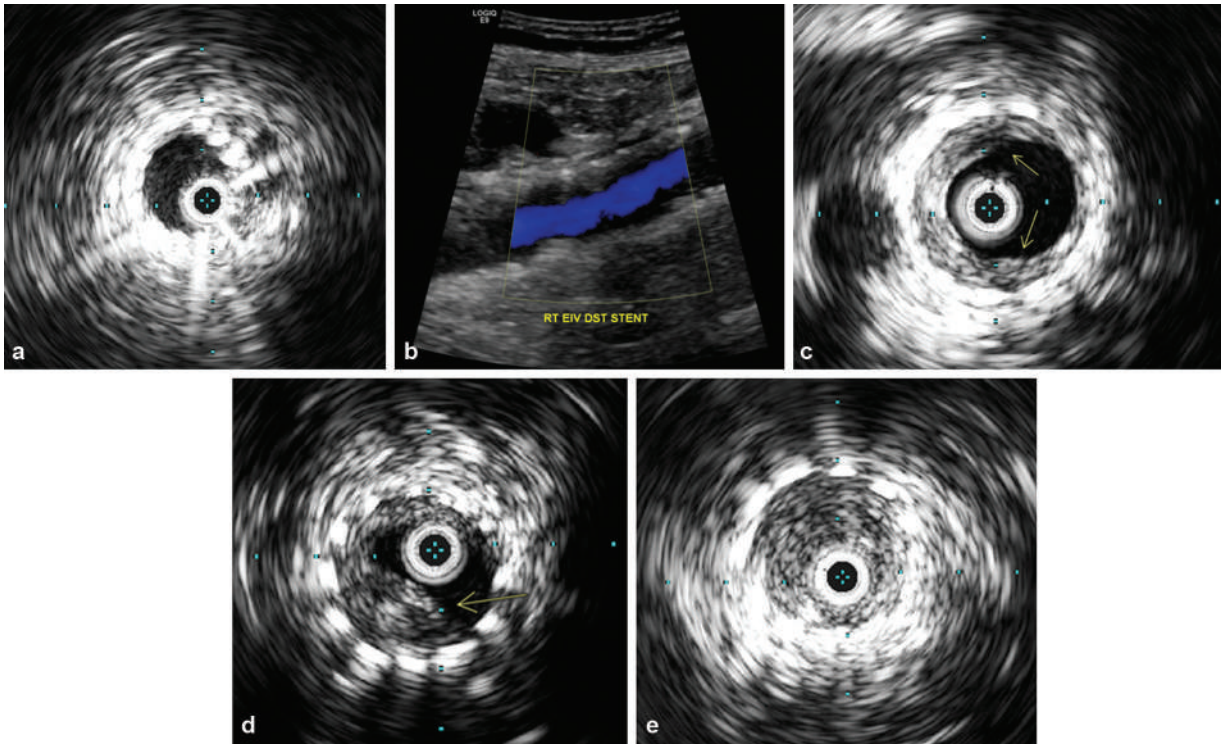

Fig. 2 Intravascular ultrasound (IVUS) image of an iliac venous stent immediately after deployment (**a**) compared with transabdominal (**b**) and IVUS (**c**) obtained months after stenting shows expected changes of chronic neointimal hyperplasia and mural thickening along the venous stent wall (**c**, arrows). IVUS appearance of hemodynamically significant in-stent stenosis (**d**, arrow) and complete in-stent thrombosis (**e**).

 © 2024. Thieme. All rights reserved.

This document was downloaded for personal use only. Unauthorized distribution is strictly prohibited.

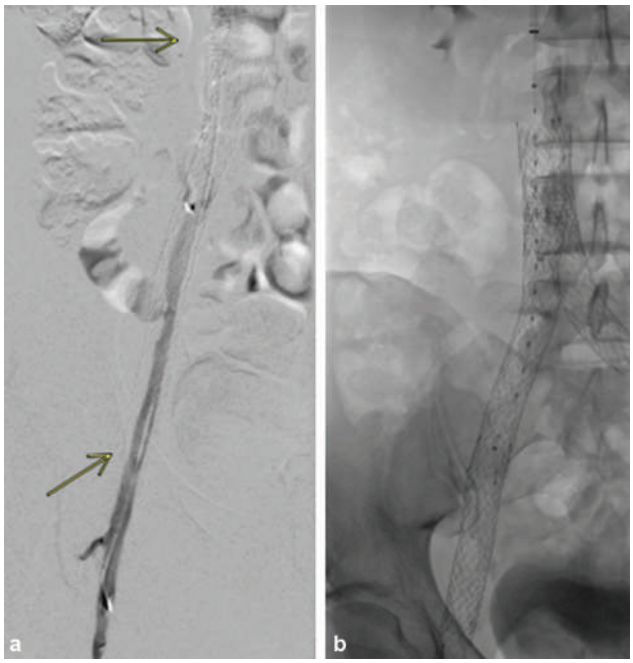

Fig. 3 A venogram shows the occluded length of an iliofemoral stent (**a**, arrows). A thrombolysis catheter with markers is positioned to span the entire length of the thrombus (**b**).

or a continuation after mechanical thrombectomy to clear the remaining clot. Depending on the length of thrombosis and the location of the affected veins proximal and distal to the existing stent complex, a multi-side-hole catheter is typically placed across the occluded segment of the vein covering its entire length including the thrombosed stented portion (►**Fig. 3**). Thrombolytic agents, most commonly alteplase (tissue plasminogen activator [tPA]), can run up to 24 hours. Typical infusion protocols call for up to 1 mg of alteplase per hour. Patency through the vascular sheath is maintained throughout lysis with heparin (500 units per hour).[14] Immediate postthrombolysis venography and IVUS often show extensive residual softened clots and are inappropriate endpoints, even if a small flow channel is reestablished. Further lumen gain should then be achieved with the higher-level techniques described later.

Mechanical and Pharmacomechanical Thrombectomy

Pharmacomechanical thrombectomy (PMT) can be performed as the first approach to opening a thrombosed stent, resulting in complete recanalization and clot removal with restoration of stent patency in a single procedure. However, if a first attempt at PMT shows incomplete clot resolution with stagnant flow, subsequent overnight thrombolysis remains a safety net followed by repeat intervention the following day with an attempt at complete clot clearance. Operators should heparinize and check the activated clotting time throughout the procedure so that it is maintained over 250 to prevent active intraprocedural thrombosis.[11]

Balloon angioplasty remains the mainstay of mechanical thrombectomy within venous stents and can be performed after instilling tPA with the clotted segment. Balloon catheters are serially inflated to the existing stent diameter along the thrombosis segment. Angiographic elimination of a balloon "waste" marks successful angioplasty without evidence of recoil. The use of drug-coated balloons remains under investigation for in-stent thrombosis but is a potential application.[15]

Advanced tools employed for PMT within stents seem to be ever-diversifying, with operators utilizing "everything but the kitchen sink," some off-label for the venous system, to remove recalcitrant in-stent thrombus. PMT with Angiojet (Boston Scientific), suction thrombectomy with Lightening Flash (Penumbra Inc.), rotational thrombectomy with devices such as the Cleaner (Argon Medical) and RevCore (Inari Medical), and finally the use of laser catheters, and sharp recanalization, to name only a few techniques, have all been reportedly used to debulk chronic, intractable thrombus from the wall of venous stents with varying success[16,17] (►**Fig. 4**). It is critical to magnify and watch diligently with

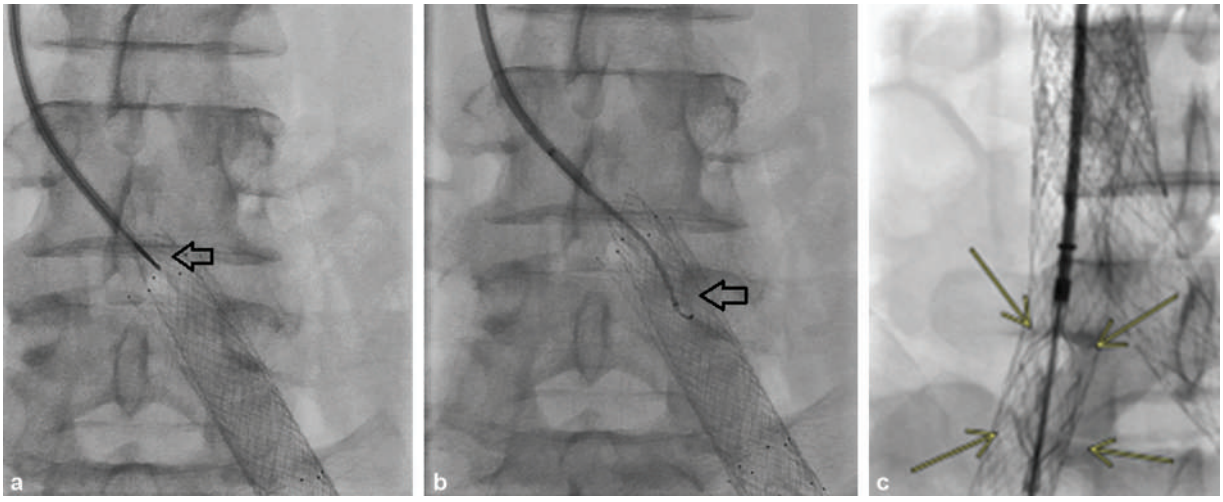

Fig. 4 Fluoroscopic images demonstrate a sharp recanalization technique of a thrombosed iliofemoral vein utilizing the metal cannula and needle from the Rosch-Uchida transjugular liver access set (Cook Medical, Bloomington, IN) (**a**, arrow), followed by blunt dissection with a guidewire and catheter (**b**, arrow). In a different patient, rotational thrombectomy (**c**, arrows) is performed within an iliofemoral stent to remove a flow-limiting nonocclusive thrombus along the wall.

 © 2024. Thieme. All rights reserved.

This document was downloaded for personal use only. Unauthorized distribution is strictly prohibited.

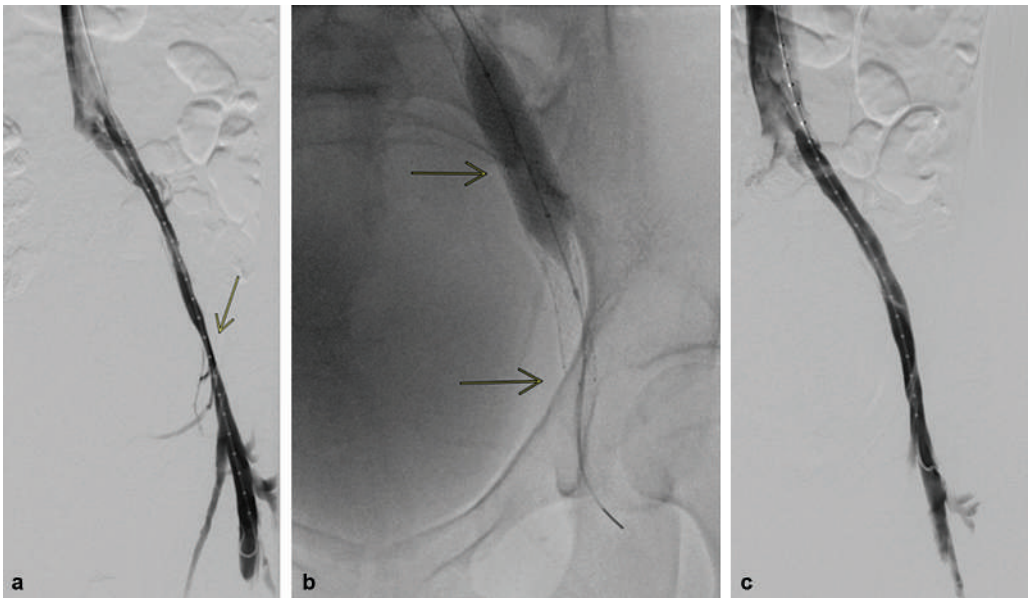

Fig. 5 A nonocclusive echogenic thrombus was identified on surveillance ultrasound within a left iliac venous stent in a highly symptomatic patient, which prompted an intervention. Venography showed hemodynamically significant stenosis at the proximal unstented portion of the external iliac inflow vein (**a**, arrow). The stent complex was extended with a 12-mm self-expanding stent to the femoral head, followed by balloon angioplasty (**b**, arrows). The post–stent extension venogram shows an improvement in flow (**c**).

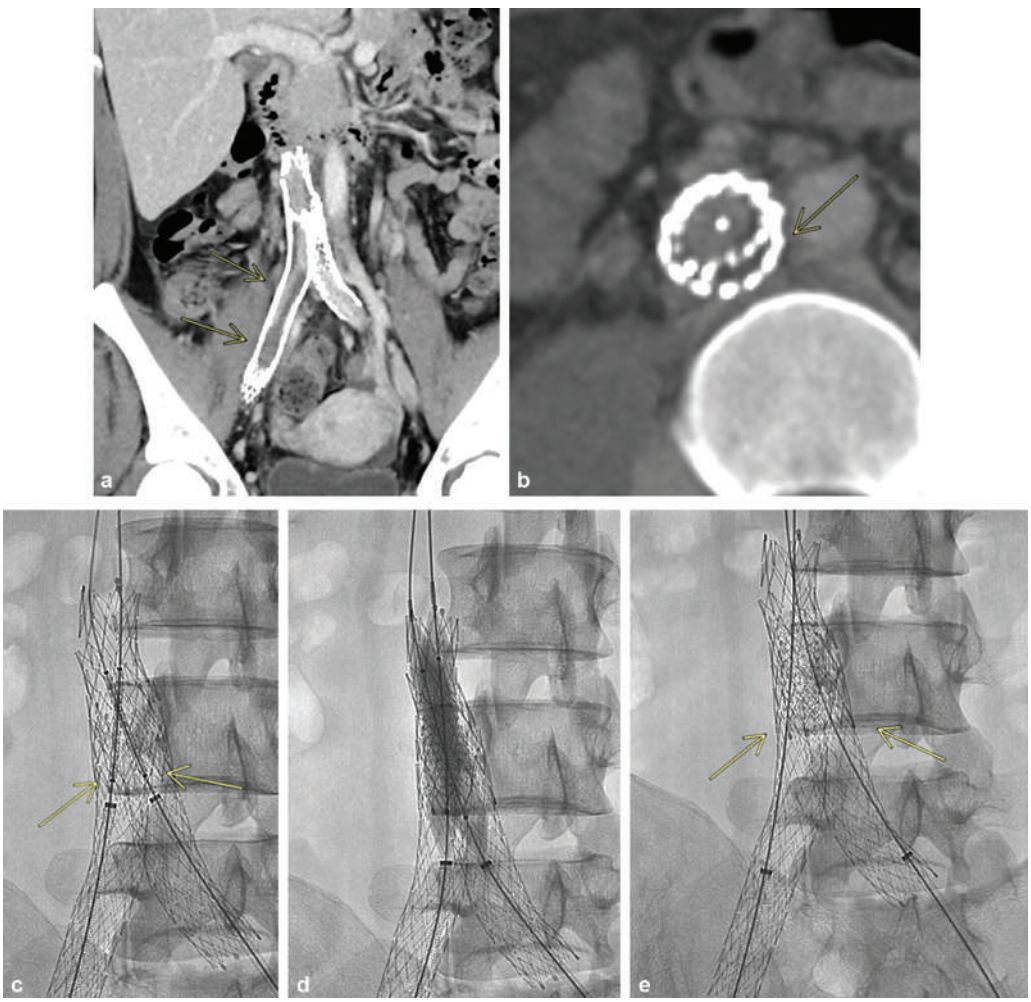

Fig. 6 A patient presented with acute in-stent thrombosis due to an overriding contralateral venous stent (**a** and **b**, arrow). After successful overnight thrombolysis, "kissing angioplasty" and relining the superior aspect of the iliac self-expanding stents with balloon-expandable stents (**c–e**, arrows) maintained long-term patency.

 © 2024. Thieme. All rights reserved.

This document was downloaded for personal use only. Unauthorized distribution is strictly prohibited.



Fig. 7 Angiography of a left common femoral arterial venous fistula that was surgically created to maintain left iliofemoral venous stent patency in a patient who failed numerous interventions to maintain flow (black arrow—common femoral artery; white arrow—femoral vein; arrowhead—arteriovenous fistula.

real-time fluoroscopy during the use of such devices, preferably over a wire, to catch the earliest sign of compromised stent integrity.

Stent Extension and Relining

If there is angiographic or IVUS evidence of inflow or outflow vein compromise, either due to failure of the original stent to completely cover the diseased vein segment, propagation of in-stent thrombosis to the adjacent vein, or narrowing of the adjacent vein from stent oversizing, stent extension may be necessary. Stents are overlapped by at least 2 cm or deployed with a "skip" technique that does not cover healthy segments of the vein. Although with low-quality evidence, more recent studies have shown that stents can be extended safely across the inguinal ligament to the inferior trochanter with similar patency outcomes[18,19] (►**Fig. 5**).

If chronic mural thrombus cannot be completely cleared or debulked or if there is a mechanical failure of the stents, relining within the stent can be performed for added radial force; however, it does not remove thrombus[16] (►**Fig. 6**). Venous stent relining techniques have yet to be extensively studied and should be considered cautiously. They have the added risk of further narrowing the lumen, especially with incomplete expansion.

Surgical Correction

Limited case reports have described the creation of a small fistula at the common femoral artery and vein as a method to maintain adequate pressurized anterograde flow through an iliofemoral stent[20] (►**Fig. 7**). However, more studies are needed to show the durability of this surgery, which may be unhelpful in relieving symptoms if the inflow veins from the leg remain occluded.

Angiographic and IVUS Endpoint of Reintervention

After thrombolysis and thrombectomy, the angiographic endpoint should show brisk anterograde flow through the stent, followed by contrast washout on delayed imaging. Stagnant contrast within the stent may be a sign of residual stenosis that needs to be treated before the case is completed. If left untreated, early rethrombosis may occur. Furthermore, angiographic flow restoration remains insufficient in determining the degree of underlying residual stenosis or the success of intervention unless confirmed with IVUS. Hemodynamically, significant stenoses may not be discernible on two-dimensional angiograms that become obvious on IVUS.

Anticoagulation

Clinical practice on the type and duration of anticoagulation after venous stenting continues to vary drastically. Anticoagulative measures are likely to be more aggressive in individuals with in-stent thrombosis who undergo reintervention to prevent additional thrombosis, morbidity, and repeat procedures. Retrospective studies have shown that using low-molecular-weight heparin for more than 10 days after the procedure or combined with an antiplatelet agent was associated with improved patency.[21]

References

1 Neglén P, Hollis KC, Olivier J, Raju S. Stenting of the venous outflow in chronic venous disease: long-term stent-related outcome, clinical, and hemodynamic result. J Vasc Surg 2007;46(05):979–990
2 Jayaraj A, Fuller R, Raju S, Stafford J. In-stent restenosis and stent compression following stenting for chronic iliofemoral venous obstruction. J Vasc Surg Venous Lymphat Disord 2022;10(01):42–51
3 Pouncey AL, Kahn T, Morris RI, Saha P, Thulasidasan N, Black SA. Risk factors and classification of reintervention following deep venous stenting for acute iliofemoral deep vein thrombosis. J Vasc Surg Venous Lymphat Disord 2022;10(05):1051–1058.e3
4 Dake MD, O'Sullivan G, Shammas NW, Lichtenberg M, Mwipatayi BP, Settlage RAVERNACULAR Trial Investigators. Three-year results from the venovo venous stent study for the treatment of iliac and femoral vein obstruction. Cardiovasc Intervent Radiol 2021;44(12):1918–1929
5 Black S, Sapoval M, Dexter DJ, et al; ABRE Study Investigators. Three-year outcomes of the Abre venous self-expanding stent system in patients with symptomatic iliofemoral venous outflow obstruction. J Vasc Interv Radiol 2024;35(05):664–675.e5
6 Cervi A, Douketis JD. Stent thrombosis after endovascular treatment of iliofemoral or caval veins in patients with postthrombotic syndrome. Thromb Haemost 2019;119(12):1897–1899
7 Li N, Ferracane J, Andeen N, et al. Impact of postthrombotic vein wall biomechanics on luminal flow during venous angioplasty and stent placement: computational modeling results. J Vasc Interv Radiol 2022;33(03):262–267
8 Saleem T, Barry O, Thaggard D, Peeples H, Raju S. Iliac vein stent failure in community practice and results of corrective reinterventions. J Vasc Surg Venous Lymphat Disord 2023;11(03):525–531.e3

 © 2024. Thieme. All rights reserved.

This document was downloaded for personal use only. Unauthorized distribution is strictly prohibited.

9 Li G, Hu B, Sun Y, Huang X, Zhang X. Histological features of in-stent restenosis after iliac vein thrombus removal and stent placement in a goat model. J Vasc Interv Radiol 2024;35(04): 611–617
10 Sebastian T, Spirk D, Engelberger RP, et al. Incidence of stent thrombosis after endovascular treatment of iliofemoral or caval veins in patients with the postthrombotic syndrome. Thromb Haemost 2019;119(12):2064–2073
11 Iliac Vein Stenting: Best Practices for Patient Safety and Successful Outcomes - Endovascular Today. Accessed August 31, 2024 at: https://evtoday.com/articles/2021-july/iliac-vein-stenting-best-practices-for-patient-safety-and-successful-outcomes
12 Meissner MH, Gloviczki P, Comerota AJ, et al; Society for Vascular Surgery American Venous Forum. Early thrombus removal strategies for acute deep venous thrombosis: clinical practice guidelines of the Society for Vascular Surgery and the American Venous Forum. J Vasc Surg 2012;55(05):1449–1462
13 Dexter D, Kado H, Shaikh A, et al. Safety and effectiveness of mechanical thrombectomy from the fully enrolled multicenter, prospective CLOUT registry. J Soc Cardiovasc Angiogr Interv 2023; 2(02):100585
14 Ramaswamy RS, Akinwande O, Giardina JD, Kavali PK, Marks CG. Acute lower extremity deep venous thrombosis: the data, where we are, and how it is done. Tech Vasc Interv Radiol 2018;21(02): 105–112
15 Lei J, Pu H, Zhang L, et al. Drug-coated balloon therapy for in-stent restenosis in patients with iliofemoral deep vein thrombosis: a single-arm observational study. Catheter Cardiovasc Interv 2024; 103(05):752–757
16 Shaikh A. Mechanical thrombectomy of venous in-stent thrombosis with the novel RevCore thrombectomy system: a report of 2 cases. Radiol Case Rep 2023;19(02):576–580
17 Saleem T, Luke C, Raju S. Percutaneous laser recanalization in chronically occluded iliofemoral venous stents. J Vasc Surg Cases Innov Tech 2022;8(03):399–403
18 Zhou Y, Guan Y, Xue M, Zheng X, Chen X. Clinical outcomes of stenting extending below the inguinal ligament for treatment of chronic iliofemoral venous obstruction. Ann Vasc Surg 2021; 75:259–266
19 Machado H, Sousa J, Mansilha A. The impact of venous stenting across the inguinal ligament on primary patency: a systematic review. Int Angiol 2021;40(04):270–276
20 de Wolf MA, Jalaie H, van Laanen JH, et al. Endophlebectomy of the common femoral vein and arteriovenous fistula creation as adjuncts to venous stenting for post-thrombotic syndrome. Br J Surg 2017;104(06):718–725
21 Vedantham S, Weinberg I, Desai KR, et al. Society of Interventional Radiology Position Statement on the management of chronic iliofemoral venous obstruction with endovascular placement of metallic stents. J Vasc Interv Radiol 2023;34(10):1643–1657.e6

This document was downloaded for personal use only. Unauthorized distribution is strictly prohibited.