Interdisciplinary CardioVascular and Thoracic Surgery 2024, 39(1), ivae131
https://doi.org/10.1093/icvts/ivae131 Advance Access publication 12 July 2024

ORIGINAL ARTICLE

Cite this article as: Lee H, Kim J, Jung J-H, Yoo JS. Mid-term outcomes of tricuspid annuloplasty using the Tri-Ad Adams tricuspid annuloplasty ring. Interdiscip CardioVasc Thorac Surg 2024; doi:10.1093/icvts/ivae131.

VALVULAR HEART DISEASE

# Mid-term outcomes of tricuspid annuloplasty using the Tri-Ad Adams tricuspid annuloplasty ring

Heemoon Lee [a,†], Jihoon Kim [b,†], Ji-Hyun Jung [c] and Jae Suk Yoo [a,d,*]

[a]Department of Thoracic and Cardiovascular Surgery, Bucheon Sejong Hospital, Bucheon, Gyeonggi-do, Republic of Korea
[b]Department of Thoracic and Cardiovascular Surgery, Kangnam Sacred Heart Hospital, Hallym University Medical Center, Hallym University College of Medicine, Seoul, Republic of Korea
[c]Division of Cardiology, Department of Internal Medicine, Bucheon Sejong Hospital, Bucheon, Gyeonggi-do, Republic of Korea
[d]Present address: Department of Thoracic and Cardiovascular Surgery, Asan Medical Center, University of Ulsan College of Medicine, Seoul, Republic of Korea

* Corresponding author. Department of Thoracic and Cardiovascular Surgery, Bucheon Sejong Hospital, 28, 489 gil Hohyen-ro, Bucheon-si, Gyeonggi-do 14754, Republic of Korea. Tel: +82-32-340-1425; fax: +82-32-340-1236; e-mail: mdyoo77@gmail.com (J.S. Yoo).

Received 11 April 2024; received in revised form 19 June 2024; accepted 10 July 2024

Downloaded from academic.oup.com/icvts/article/39/1/ivae131/7712946 by guest on 18 November 2026

**Mid-term outcomes of tricuspid annuloplasty using the Tri-Ad Adams tricuspid annuloplasty ring**

## Summary

From August 2016 to October 2021, 248 patients who underwent tricuspid annuloplasty with the Tri-Ad Adams ring showed favorable early and mid-term outcomes. The 4-year freedoms from overall mortality and TR ≥moderate were 96.9% and 91.6%, respectively. No tricuspid valve reoperation, ring dehiscence, or significant tricuspid stenosis occurred.

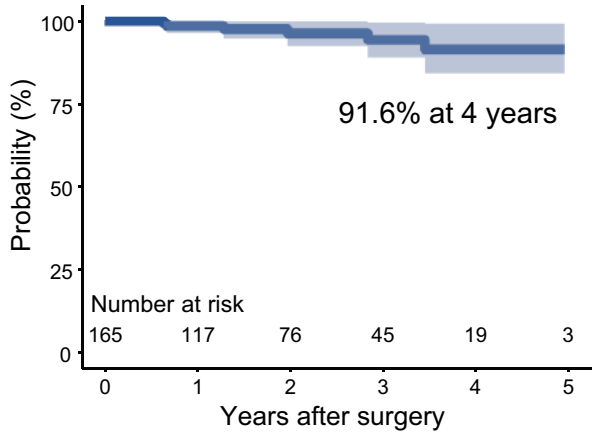


Legend: TR, tricuspid regurgitation.

## Abstract

**OBJECTIVES:** The Tri-Ad Adams tricuspid annuloplasty ring is a recent innovative prosthesis characterized by a semi-rigid central component and fully flexible extremities. The goal of this study was to assess the short-term and mid-term results following implantation of the Tri-Ad Adams ring.

†The first 2 authors contributed equally to this work.

© The Author(s) 2024. Published by Oxford University Press on behalf of the European Association for Cardio-Thoracic Surgery.
This is an Open Access article distributed under the terms of the Creative Commons Attribution-NonCommercial License (https://creativecommons.org/licenses/by-nc/4.0/), which permits non-commercial re-use, distribution, and reproduction in any medium, provided the original work is properly cited. For commercial re-use, please contact journals.permissions@oup.com

**METHODS:** A retrospective analysis was conducted on patients who underwent tricuspid annuloplasty using the Tri-Ad Adams ring between August 2016 and October 2021.

**RESULTS:** Our study enrolled a total of 248 participants. The median age was 64.0 (interquartile range: 56.0–71.5) years. The median EuroSCORE II was 4.3% (2.7–7.5%), with 37 patients (14.9%) having a history of cardiac operations. Tricuspid regurgitation of grade 2–3 was observed in 63.7% of cases, and the median tricuspid annular diameter was 3.3 (2.8–3.6) cm. Concurrent procedures included mitral valve replacement ($n = 160$, 64.5%), mitral valve repair ($n = 75$, 30.2%), aortic valve replacement ($n = 72$, 29.0%) and the maze procedure ($n = 170$, 68.5%). Immediate postoperative tricuspid regurgitation≥moderate was present in 1 patient (0.4%). Early death occurred in 14 patients (5.6%). Major complications included low cardiac output syndrome ($n = 18$, 0.3%), acute kidney injury ($n = 14$, 5.6%) and permanent pacemaker placement ($n = 15$, 6.0%). According to the Kaplan–Meier analysis, the 4-year rates of freedom from overall mortality and moderate-to-severe tricuspid regurgitation were 96.9% and 91.6%, respectively. There were no incidents of tricuspid valve reoperations, ring detachment or significant tricuspid stenosis (trans-tricuspid valve gradient ≥ 5 mmHg).

**CONCLUSIONS:** Tricuspid annuloplasty utilizing the Tri-Ad Adams ring demonstrated favourable outcomes in both the early and mid-term periods. Further studies are warranted to confirm the long-term results.

**Keywords:** Tricuspid valve • Tricuspid valve insufficiency • Cardiac valve annuloplasty

**ABBREVIATIONS**

| | |
|---|---|
| AV | Atrioventricular |
| CI | Confidence interval |
| PPM | Permanent pacemaker |
| TAP | Tricuspid annuloplasty |
| TR | Tricuspid regurgitation |
| TS | Tricuspid stenosis |
| TTPG | Trans-tricuspid pressure gradient |
| TV | Tricuspid valve |

## INTRODUCTION

The major pathophysiology of functional tricuspid regurgitation (TR) is annular dilatation; thus, reduction of the dilated annulus is the mainstay of surgical treatment of TR. A classic example of tricuspid annuloplasty (TAP) is the De Vega technique, which has been widely used [1]. However, since the introduction of prosthetic annuloplasty rings, TAP with an annuloplasty ring has become the standard technique for TR correction [2]. The flexible and rigid rings are the most widely used prostheses among the various TAP rings. Flexible rings (bands) can reduce the dilated annulus (reduction annuloplasty), simultaneously allowing the natural physiologic motion of the tricuspid annulus [3]. However, it neither restores nor maintains the optimal saddle shape of the annulus. Meanwhile, recent rigid rings have been devised to restore the normal annulus shape and size (remodelling annuloplasty) by designing the ring shape 3-dimensionally based on the normal geometry of the tricuspid annulus. Nevertheless, rigid rings reportedly carry more significant risks of ring dehiscence [4, 5]. In terms of preventing TR recurrence, the superiority of one specific prosthesis over the other remains controversial [6–8].

The Tri-Ad Adams TAP ring (Medtronic, Minneapolis, MN, USA) was developed, accepting the advantages of the 2 types of rings. The Tri-Ad Adams ring combines semi-rigid and flexible bands, allowing for annular remodelling in the right ventricular free wall region and maintaining the physiologic motion of the annulus. It potentially reduces injury to the conduction system with its flexible and wide-open ends [9].

There have been few investigations on the outcomes of TAP with the Tri-Ad Adams rings. Previous studies [9, 10] demonstrated favourable early outcomes, and our goal in the present study was to evaluate the mid-term outcomes.

## PATIENTS AND METHODS

### Ethical statement

The study protocol was approved by the Bucheon Sejong Hospital Institutional Review Board, which waived the requirement for patient consent (IRB no. 2022-11-003, approval date 30 November 2022).

### Study population

We retrospectively reviewed consecutive patients who underwent TAP with the Tri-Ad Adams ring at our institution between August 2016 and October 2021. All the patients were enrolled regardless of surgical approach (sternotomy and minimally invasive surgery), repeat cardiac surgery and concomitant procedures. Their medical records and laboratory, echocardiographic and other relevant data were reviewed.

### Operative techniques

The operation was performed with a median sternotomy or via a minimally invasive approach [11] under cardiopulmonary bypass and mild hypothermia. A cardioplegic arrest or beating-heart strategy was utilized as appropriate. Concomitant procedures were completed in a customary manner before or after the tricuspid valve (TV) operation. The TV was exposed through an oblique right atriotomy after caval snares were used, and the anatomy and mechanism of regurgitation of the valve were analysed. The size of the annuloplasty ring was determined by measuring the length of the septal leaflet attachment (intercommissural distance) and the anterior leaflet surface area with the dedicated Tri-Ad Adams ring sizers. Next, interrupted horizontal mattress sutures with 2–0 Ethibond (Ethicon, Inc., Somerville, NJ, USA) were placed along the septal-posterior-anterior annulus, starting from the level of the coronary sinus and finishing at the point 1 cm before the anteroseptal commissure (Fig. 1; Video 1). Subsequently, the sutures were passed through the selected ring and tied securely or fixed with titanium fasteners (Cor-Knot Device, LSI Solutions, Victor, NY, USA).

Downloaded from academic.oup.com/icvts/article/39/1/ivae131/7712946 by guest on 18 November 2026

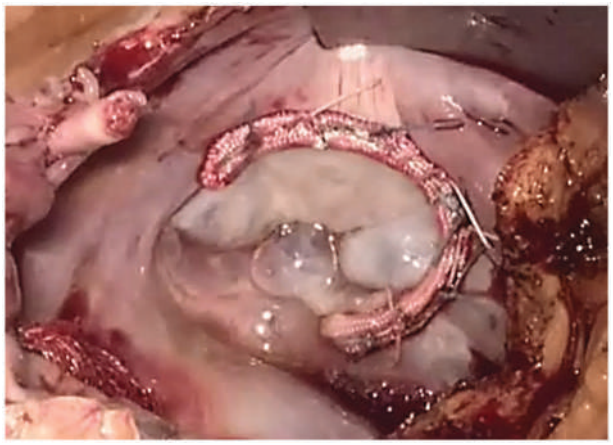

**Figure 1:** Tricuspid annuloplasty with the Tri-Ad Adams ring. The wide-open ends of the ring preserve the anteroseptal commissure area where the conduction system exists.

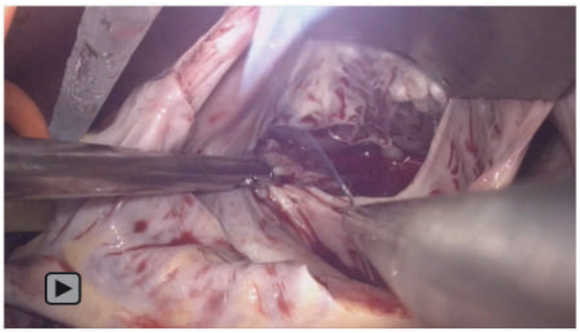

**Video 1:** Operative technique in minimally invasive tricuspid annuloplasty with Tri-Ad Adams ring.

According to the TR mechanism and the quality of the leaflets, concomitant tricuspid valvuloplasty was performed if needed. After the patient was weaned from cardiopulmonary bypass, the repaired valve was evaluated with transoesophageal echocardiography.

## Data collection and definitions

Perioperative and follow-up patient data were obtained by reviewing medical records. The primary end point of the study was all-cause mortality. Early mortality was defined as postoperative death occurring within 30 days of the operation. The secondary end point was late TR ≥moderate evident in follow-up echocardiographic scans.

## Echocardiographic assessment and follow-up

According to the guidelines, TR was assessed using qualitative and semi-quantitative methods. The severity of the TR was graded on a scale from 0 to 3 (0, no or minimal; 1, mild; 2, moderate; 3, severe) [12]. The tricuspid annular diameter was measured in the apical 4-chamber view in late diastole at the maximal TV opening [13]. The modified Bernoulli equation was used to calculate the trans-tricuspid pressure gradient (TTPG) from the maximal TR velocity measured by continuous-wave Doppler [14]. All patients underwent transthoracic echocardiography at discharge. Follow-up echocardiography was performed as appropriate. The last echocardiogram performed before death was considered the last follow-up test for those who died in the hospital.

## Statistical analysis

Descriptive statistics of the total study population were obtained. Continuous variables were tested for a normal distribution using the Shapiro-Wilks test and are presented as median (interquartile range). Categorical variables are presented as *n* (%). Kaplan–Meier curves were used to estimate the distributions of time-to-event outcomes. The Cox regression analysis was employed to identify the clinical and echocardiographic parameters significantly related to the time-to-event outcomes, and the hazard ratio and its confidence interval (CI) were calculated. The variables considered are as follows: age, sex, New York Heart Association functional class 3–4, hypertension, diabetes, atrial fibrillation, chronic obstructive pulmonary disease, chronic kidney disease, EuroSCORE II, previous heart surgery, left ventricular ejection fraction ≤40%, preoperative TR grade, tricuspid annular diameter, operative data and postoperative TR grade. The multivariable Cox regression model included variables with a $P < 0.2$ in the univariable analysis. The Fine and Gray competing risk regression method [15] was applied to account for death as a competing risk when adjusting the cumulative incidence of TR ≥moderate. Statistical significance was set at $P < 0.05$. Rates of missingness for data in our models were <1%, and no imputation was performed for missing data. All statistical analyses were done using R 3.6.3 (R Foundation for Statistical Computing, Vienna, Austria) and SPSS version 25.0 (SPSS, Chicago, IL, USA).

# RESULTS

## Demographics and characteristics

A total of 248 patients were enrolled in our study. The median age was 64.0 (56.0–71.5) years, and the median EuroSCORE II was 4.3% (2.7–7.5%). Of these, 37 patients (14.9%) had previous heart operations, and 20 (8.1%) had left ventricular ejection fractions ≤40%. Other baseline characteristics are described in Table 1.

## Operative data

Patients underwent operations with a conventional median sternotomy ($n = 204$) or a minimally invasive approach ($n = 44$). Operations with cardioplegic arrest were performed in 236 patients, and the beating-heart strategy was used in 12 patients. Frequently performed concomitant procedures are mitral valve replacement ($n = 160$, 64.5%), mitral valve repair ($n = 75$, 30.2%), aortic valve replacement ($n = 72$, 29.0%), the maze procedure ($n = 170$, 68.5%) and coronary artery bypass grafting ($n = 19$, 7.7%). Other operative data are summarized in Table 2.

## Clinical and echocardiographic outcomes

Early death occurred in 14 patients (5.6%) in the cohort ($n = 248$). On the immediate postoperative echocardiograms, 1 patient (0.4%) had TR ≥moderate. Reoperations for bleeding were performed on 9 patients (3.6%), and low cardiac output

Downloaded from academic.oup.com/icvts/article/39/1/ivae131/7712946 by guest on 18 November 2026

**Table 1:** Baseline characteristics

| Variable | Value |
|---|---|
| Age, years | 64.0 (56.0–71.5) |
| Female | 133 (53.6) |
| NYHA functional class 3–4 | 130 (52.4) |
| Hypertension | 88 (35.5) |
| Diabetes mellitus | 44 (17.7) |
| Atrial fibrillation | 194 (78.2) |
| COPD | 13 (5.2) |
| CKD | 19 (7.7) |
| EuroSCORE II, % | 4.3 (2.7–7.5) |
| Previous heart surgery | 37 (14.9) |
| LVEF ≤40% | 20 (8.1) |
| TR grade | |
| 1 | 90 (36.3) |
| 2 | 136 (54.8) |
| 3 | 22 (8.9) |
| Tricuspid annular diameter, cm | 3.3 (2.8–3.6) |

Continuous variables are presented as median (interquartile range), and categorical variables are presented as *n* (%).

CKD: chronic kidney disease; COPD: chronic obstructive pulmonary disease; LVEF: left ventricular ejection fraction; NYHA: New York Heart Association; TR: tricuspid regurgitation.

**Table 2:** Operating data

| Variable | Value |
|---|---|
| CPB time, min | 153.0 (120.0–191.0) |
| ACC time, min | 113.0 (90.0–140.0) |
| Tri-Ad Adams ring size | |
| 26 mm | 110 (44.4) |
| 28 mm | 117 (47.2) |
| 30 mm | 20 (8.1) |
| 32 mm | 1 (0.4) |
| Concomitant procedures | |
| Mitral valve replacement | 160 (64.5) |
| Mitral valve repair | 75 (30.2) |
| Aortic valve replacement | 72 (29.0) |
| Maze procedure | 170 (68.5) |
| Coronary artery bypass | 19 (7.7) |
| Atrial septal defect closure | 12 (4.8) |
| Aortic surgery | 5 (2.0) |
| Septal myectomy | 5 (2.0) |

Continuous variables are presented as median (interquartile range), and categorical variables are presented as *n* (%).

ACC: aortic cross-clamp; CPB: cardiopulmonary bypass.

syndrome occurred in 18 patients (7.3%). Permanent pacemaker (PPM) insertion was required in 15 (6.0%) due to sick sinus syndrome ($n = 8$) and complete atrioventricular (AV) block ($n = 7$). Other early morbidities are described in Table 3.

Of 238 hospital survivors, echocardiographic assessments were available for 166 patients (69.7%) during the follow-up period in our outpatient clinic after surgery. The median follow-up time was 32.3 (16.3–46.7) months, and the median time of the last follow-up echocardiogram was 20.8 (10.5–37.6) months. The follow-up examinations concluded in September 2022. Freedom from overall mortality based on Kaplan–Meier estimates was 96.9% at 4 years (Fig. 2A). Figure 2B shows Kaplan–Meier survival curves for TR ≥moderate. Freedom from TR ≥moderate was

**Table 3:** Early outcomes

| Variable | Value |
|---|---|
| Reoperation for bleeding | 9 (3.6) |
| AKI needing dialysis | 14 (5.6) |
| LCOS | 18 (7.3) |
| Pneumonia | 17 (6.9) |
| PPM insertion | 15 (6.0) |
| Deaths | 14 (5.6) |
| Hospital stay, days | 9.0 (7.0–14.0) |
| Postoperative TR ≥moderate | 1 (0.4) |

Continuous variables are presented as median (interquartile range), and categorical variables are presented as *n* (%).

AKI: acute kidney injury; LCOS: low cardiac output syndrome; PPM: permanent pacemaker; TR: tricuspid regurgitation.

91.6% at 4 years. Additionally, Supplementary Material, Fig. S1 shows the cumulative incidence of TR ≥moderate after accounting for death as a competing risk. The median TTPGs measured by transthoracic echocardiography were 1.3 (1.0–2.0) mmHg at discharge and 1.1 (0.9–1.8) mmHg at the last follow-up (Fig. 3). The mixed effect linear regression model for variable follow-up length was conducted to assess the changes of TTPG, which demonstrated that the follow-up TTPG was slightly reduced (estimated coefficient = −0.22, 95% CI = -0.337, −0.104). There was no significant tricuspid stenosis (TS) (TTPG ≥5 mmHg), ring dehiscence or TV reoperation. A multivariable Cox proportional hazard model revealed preoperative TR grade (hazard ratio = 16.446, 95% CI = 1.775–152.393) as the predictor for late TR ≥moderate (Table 4).

## DISCUSSION

In the present study, TAP with the Tri-Ad Adams ring showed favourable early and mid-term outcomes. The main findings are (i) immediate postoperative TR ≥moderate was present in 1 patient (0.4%); (ii) freedom from 4-year overall mortality and TR ≥moderate were 96.9% and 91.6%, respectively; (iii) no significant TS, TV reoperation or ring dehiscence was observed; (iv) preoperative TR grade was the predictor for late TR ≥moderate.

The normal tricuspid annulus is a nonplanar saddle-shaped structure with dynamic motions during the cardiac cycle [16]. The tricuspid annular dilatation mainly involves the anterior and posterior annuli leading to the coaptation failure of the TV leaflets, which resulted in TR [17]. To address this feature, the De Vega technique has been proposed [1], and eventually, ring annuloplasty with a flexible band to reduce the dilated annulus [7]. Several potential advantages of the flexible band have been suggested; theoretically, it provides natural physiologic tricuspid annular motion throughout the cardiac cycle, potentially preserving the right ventricular function. In addition, the simple design and the easy implantation technique of the band contribute to lower risks of device breakages and TS after implantation. Furthermore, the flexible band is known to represent a negligible risk of injury to the cardiac tissue and the adjacent coronary vessels during implantation [8, 18, 19]. The risk of ring dehiscence was also significantly lower with the flexible band than with the rigid ring [5]. However, the flexible band may not restore the optimal saddle shape of the annulus, and some reports suggested

Downloaded from academic.oup.com/icvts/article/39/1/ivae131/7712946 by guest on 18 November 2026

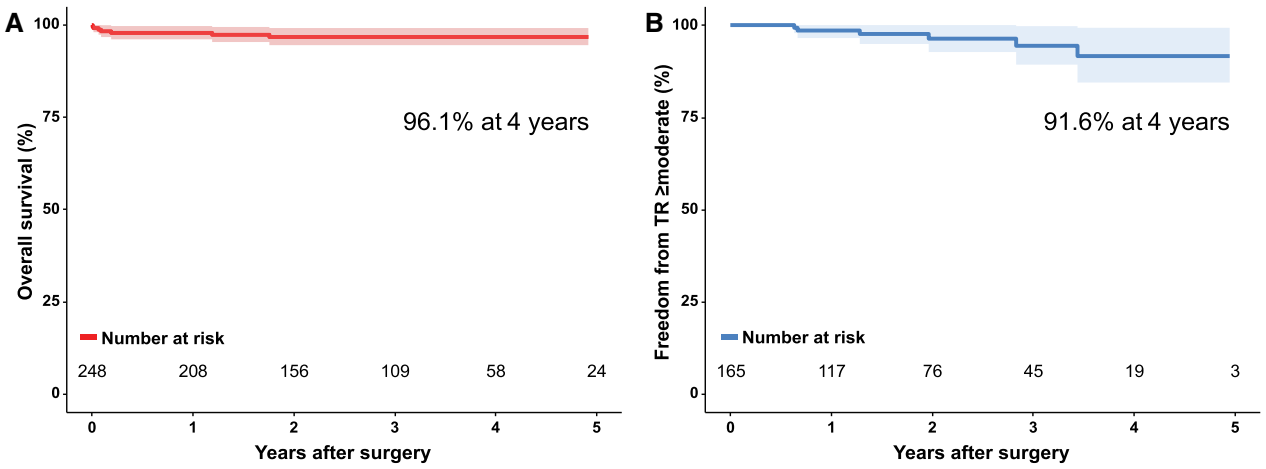


**Figure 2:** Kaplan–Meier survival curves for (**A**) overall survival and (**B**) freedom from tricuspid regurgitation ≥moderate. TR: tricuspid regurgitation.

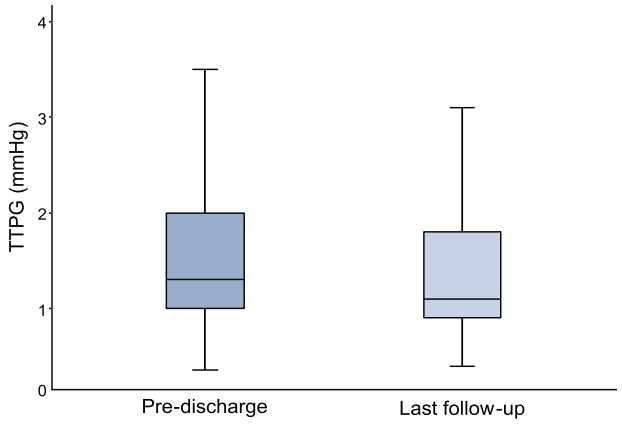


**Figure 3:** Box plot for trans-tricuspid pressure gradient at predischarge and last follow-up. TTPG: trans-tricuspid pressure gradient.

that the preventive effects of recurrent TR were less in flexible bands [20, 21].

On the contrary, recent rigid rings have a preconfigured 3-dimensional design to accommodate the normal native saddle shape of the TV annulus [7, 22]. Accordingly, the rigid ring is known to have superior results in geometrical annulus remodelling and durability [4, 6, 23]. However, which type of prosthesis is better for preventing TR recurrence is still controversial [6–8].

Meanwhile, theoretically, the Tri-Ad Adams ring design integrates the advantages of flexible and rigid rings by uniting a semi-rigid part at the middle portion of the ring and completely flexible ends. The middle semi-rigid part enables remodelling of the TV annulus corresponding to the right ventricular free wall. At the same time, the flexible ends allow the 3-dimensional natural annular motion during the cardiac cycle. In addition, the wide-open design, which needs no sutures around the conduction system, prevents iatrogenic conduction injury and subsequent PPM insertion [9]. Furthermore, results of a recent animal study also suggested that the hybrid design of the Tri-Ad Adams ring may prevent ring dehiscence [24].

On this basis, favourable early outcomes with the Tri-Ad Adams ring have been reported. Milla *et al.* [9] described 42 patients with degenerative mitral valve disease who underwent concomitant TAP with the Tri-Ad Adams ring. There were no ring-related operative complications or PPM implants. All patients had no or minimal TR at discharge. Jung *et al.* [10] reported on 36 patients who underwent TAP with the Tri-Ad Adams ring for functional TR. The TR grades were reduced significantly from 2.03 (SD: 1.06) to 1.18 (SD: 0.92) ($P < 0.01$), and there were no ring-related complications, including AV block or ring dehiscence.

In addition to these acceptable early outcomes, our study demonstrated favourable mid-term outcomes. During the follow-up period, which was a median of 32.3 (16.3–46.7) months, there were no significant TS, TV reoperation or ring dehiscence, and the study showed satisfactory probabilities of freedom from overall mortality (96.9%) and TR ≥moderate (91.6%) at 4 years. Nevertheless, our study showed a relatively higher PPM insertion rate ($n = 15$, 6.0%) than previous studies [9, 10]. Looking more closely, however, the reasons for inserting PPM were sick sinus syndrome in 8 patients and complete AV block in 7. Excluding patients with sick sinus syndrome in which the PPM insertion is not related to the TAP, concomitant procedures that can affect the conduction system–maze procedure ($n = 3$) and septal myectomy ($n = 1$)—should be considered in the patients with complete AV block. Accordingly, the remaining 3 PPM insertion cases (1.2%) are thought to be related to TV repair, which is an acceptable rate.

## Limitations

The present study has several limitations. First, this is a retrospective, non-randomized study in a single institution. Therefore, selection bias or unidentified confounding bias may have influenced the results. Second, our study included heterogeneous patients with diverse cardiac pathologies. However, the study showed consistent results in this group of patients, and thus, the results might imply that the Tri-Ad Adams ring could be used for various pathologies. Third, follow-up echocardiographic assessments were available in a limited number of patients (69.7%), which is a real-world situation. Last, our study is a single-arm study with no comparison groups. It warrants further investigations comprising various TV repair/annuloplasty techniques or other rings.

Downloaded from academic.oup.com/icvts/article/39/1/ivae131/7712946 by guest on 18 November 2026

**Table 4:** Predictors of late tricuspid regurgitation ≥moderate

| Variable | *P*-value (univariable) | *P*-value (multivariable) | HR | 95% CI |
|---|---|---|---|---|
| EuroSCORE II | 0.191 | | | |
| Female | 0.166 | | | |
| CKD | <0.001 | 0.036 | 7.242 | 1.138–46.082 |
| CVA | 0.033 | | | |
| Previous heart surgery | 0.050 | | | |
| Tricuspid annular diameter | 0.031 | | | |
| Preoperative TR grade | 0.001 | 0.014 | 16.446 | 1.775–152.393 |

CI: confidence interval; CKD: chronic kidney disease; CVA: cerebrovascular accident; HR: hazard ratio; TR: tricuspid regurgitation.

## CONCLUSIONS

TAP performed with the Tri-Ad Adams ring showed favourable early and mid-term outcomes with low complication rates. Further research is necessary to validate the efficacy, safety and long-term outcomes of TAP using this prosthesis.

## SUPPLEMENTARY MATERIAL

Supplementary material is available at *ICVTS* online.

## ACKNOWLEDGEMENTS

None declared.

## FUNDING

No funding was provided for this study.

**Conflict of interest:** none declared.

## DATA AVAILABILITY

The data that support the findings of this study are available from the corresponding author upon reasonable request.

## Author contributions

**Heemoon Lee:** Data curation; Formal analysis; Methodology; Resources; Validation; Visualization; Writing—original draft; Writing—review & editing. **Jihoon Kim:** Investigation; Validation; Visualization; Writing—original draft; Writing—review & editing. **Ji-Hyun Jung:** Conceptualization; Investigation; Methodology; Project administration; Resources; Supervision; Validation; Writing—original draft. **Jae Suk Yoo:** Conceptualization; Investigation; Methodology; Project administration; Resources; Supervision; Validation; Writing—original draft; Writing—review & editing.

## Reviewer information

*Interactive CardioVascular and Thoracic Surgery* thanks Youssef Fady Abouelela, Sinan Arsan, Mohamed Abdel Bary and the other anonymous reviewers for their contributions to the peer review process of this article.

## REFERENCES

[1] De Vega NG. [Selective, adjustable and permanent annuloplasty. An original technic for the treatment of tricuspid insufficiency]. Rev Esp Cardiol 1972;25:555–6.
[2] Tang GH, David TE, Singh SK, Maganti MD, Armstrong S, Borger MA. Tricuspid valve repair with an annuloplasty ring results in improved long-term outcomes. Circulation 2006;114:I577–81.
[3] Malinowski M, Jazwiec T, Quay N, Goehler M, Rausch MK, Timek TA. The influence of tricuspid annuloplasty prostheses on ovine annular geometry and kinematics. J Thorac Cardiovasc Surg 2021;161:e191–207.
[4] Wang H, Liu X, Wang X, Lv Z, Liu X, Xu P. Comparison of outcomes of tricuspid annuloplasty with 3d-rigid versus flexible prosthetic ring for functional tricuspid regurgitation secondary to rheumatic mitral valve disease. J Thorac Dis 2016;8:3087–95.
[5] Pfannmuller B, Doenst T, Eberhardt K, Seeburger J, Borger MA, Mohr FW. Increased risk of dehiscence after tricuspid valve repair with rigid annuloplasty rings. J Thorac Cardiovasc Surg 2012;143:1050–5.
[6] Gatti G, Dell'Angela L, Morosin M, Maschietto L, Pinamonti B, Benussi B *et al.* Flexible band versus rigid ring annuloplasty for functional tricuspid regurgitation: two different patterns of right heart reverse remodelling. Interact CardioVasc Thorac Surg 2016;23:79–89.
[7] Izutani H, Nakamura T, Kawachi K. Flexible band versus rigid ring annuloplasty for functional tricuspid regurgitation. Heart Int 2010;5:e13.
[8] Zhu TY, Wang JG, Meng X. Is a rigid tricuspid annuloplasty ring superior to a flexible band when correcting secondary tricuspid regurgitation? Interact CardioVasc Thorac Surg 2013;17:1009–14.
[9] Milla F, Castillo JG, Varghese R, Chikwe J, Anyanwu AC, Adams DH. Rationale and initial experience with the tri-ad adams tricuspid annuloplasty ring. J Thorac Cardiovasc Surg 2012;143:S71–3.
[10] Jung W, Choi JW, Hwang HY, Kim KH. Early clinical outcomes of tricuspid valve repair with a tri-ad annuloplasty ring in comparison with the outcomes using an mc(3) ring. Korean J Thorac Cardiovasc Surg 2018;51:92–9.
[11] Shin C, Ju MH, Lee CH, Lim MH, Je HG. Surgical outcomes of cardiac myxoma resection through right mini-thoracotomy. J Chest Surg 2023;56:42–8.
[12] Zoghbi WA, Enriquez-Sarano M, Foster E, Grayburn PA, Kraft CD, Levine RA *et al.* Recommendations for evaluation of the severity of native valvular regurgitation with two-dimensional and doppler echocardiography. J Am Soc Echocardiogr 2003;16:777–802.
[13] Foale R, Nihoyannopoulos P, McKenna W, Kleinebenne A, Nadazdin A, Rowland E *et al.* Echocardiographic measurement of the normal adult right ventricle. Br Heart J 1986;56:33–44.
[14] Baumgartner H, Hung J, Bermejo J, Chambers JB, Evangelista A, Griffin BP *et al.* Echocardiographic assessment of valve stenosis: EAE/ASE recommendations for clinical practice. J Am Soc Echocardiogr 2009;22:1–23; quiz 101–2.
[15] Fine JP, Gray RJ. A proportional hazards model for the subdistribution of a competing risk. J Am Stat Assoc 1999;94:496–509.
[16] Ton-Nu TT, Levine RA, Handschumacher MD, Dorer DJ, Yosefy C, Fan D *et al.* Geometric determinants of functional tricuspid regurgitation: insights from 3-dimensional echocardiography. Circulation 2006;114:143–9.
[17] Seo HS, Ha JW, Moon JY, Choi EY, Rim SJ, Jang Y *et al.* Right ventricular remodeling and dysfunction with subsequent annular dilatation and tethering as a mechanism of isolated tricuspid regurgitation. Circ J 2008;72:1645–9.

Downloaded from academic.oup.com/icvts/article/39/1/ivae131/7712946 by guest on 18 November 2026

[18] Gatti G, Marciano F, Antonini-Canterin F, Pinamonti B, Benussi B, Pappalardo A *et al.* Tricuspid valve annuloplasty with a flexible prosthetic band. Interact CardioVasc Thorac Surg 2007;6:731–5.
[19] Jung SH, Je HG, Song JM, Choo SJ, Chung CH, Yun SC *et al.* Outcomes following use of a modified duran ring tricuspid valve reconstruction procedure for secondary tricuspid regurgitation. Circ J 2010;74:925–30.
[20] Algarni KD, Alfonso J, Pragliola C, Kheirallah H, Adam AI, Arafat AA. Long-term outcomes of tricuspid valve repair: the influence of the annuloplasty prosthesis. Ann Thorac Surg 2021;112:1493–500.
[21] Wang N, Phan S, Tian DH, Yan TD, Phan K. Flexible band versus rigid ring annuloplasty for tricuspid regurgitation: a systematic review and meta-analysis. Ann Cardiothorac Surg 2017;6:194–203.
[22] Jang DH, Yoo JS. Chordae tendineae approximation technique for severe tricuspid regurgitation with severe leaflet tethering using a totally endoscopic beating-heart strategy: a case report. J Chest Surg 2023; 56:56–8.
[23] Yokoyama Y, Takagi H, Kuno T. Impact of different annuloplasty methods for tricuspid regurgitation: a network meta-analysis. Ann Thorac Surg 2021;111:2004–10.
[24] Cho S, Park CH, Shin H, Lim JH, Sohn SH, Kim JS *et al.* Suture tie-down forces and cyclic contractile forces after undersized tricuspid annuloplasty using a Tri-Ad Adams tricuspid annuloplasty ring in an ovine model. Interdiscip Cardiovasc Thorac Surg 2023;37:ivad121.



Downloaded from academic.oup.com/icvts/article/39/1/ivae131/7712946 by guest on 18 November 2026

© The Author(s) 2024. Published by Oxford University Press on behalf of the European Association for Cardio-Thoracic Surgery.
This is an Open Access article distributed under the terms of the Creative Commons Attribution-NonCommercial License (https://creativecommons.org/licenses/by-nc/4.0/), which permits non-commercial re-use, distribution, and reproduction in any medium, provided the original work is properly cited. For commercial re-use, please contact journals.permissions@oup.com
Interdisciplinary CardioVascular and Thoracic Surgery, 2024, 39, 1–7
https://doi.org/10.1093/icvts/ivae131
Original article