Radiology Case Reports 19 (2024) 1965–1969

Available online at www.sciencedirect.com

ScienceDirect

journal homepage: www.elsevier.com/locate/radcr

Case Report

Successful retrieval of a foreign body in an infant's right pulmonary artery using the new boomerang loop–snare technique: A case report ☆,☆☆

Atsufumi Kamisako, MD, PhD[a,*], *Akira Ikoma, MD, PhD*[a], *Takayuki Suzuki, MD, PhD*[b], *Nobuyuki Kakimoto, MD*[b], *Tomohiro Suenaga, MD, PhD*[b], *Daisuke Tokuhara, MD, PhD*[b], *Tetsuo Sonomura, MD, PhD*[a]

[a] *Department of Radiology, Wakayama Medical University, 811-1 Kimiidera, Wakayama, Wakayama 641-8509, Japan*

[b] *Department of Pediatrics, Wakayama Medical University, 811-1 Kimiidera, Wakayama, Wakayama 641-8509, Japan*

ARTICLE INFO

Article history:
Received 2 February 2024
Accepted 5 February 2024
Available online 27 February 2024

Keywords:
Loop–snare technique
Foreign body retrieval
Infant pulmonary artery

ABSTRACT

We report successful percutaneous retrieval of a foreign body located in an infant's right pulmonary artery using the new boomerang loop–snare technique. The case was an 18-month-old girl. A central venous catheter for chemotherapy was inserted from the right subclavian vein during treatment for myelodysplastic syndrome at another hospital. A postprocedural chest X-ray showed a foreign body in her right lung, and contrast-enhanced computed tomography confirmed the linear foreign body was located in the right pulmonary artery. The patient was transferred to our hospital to retrieve the foreign body. Under cooperation with pediatric cardiologists, a 6 Fr sheath was inserted via the right femoral vein, and a guiding catheter was advanced into the right pulmonary artery. Owing to the risk of vascular injury when using endoscopic forceps, we decided to use the loop–snare technique. We successfully crossed over the foreign body using a steerable microcatheter and a long microguidewire. The microguidewire was reinserted into the guiding catheter, and a loop was created by grasping the end of the wire using a microsnare catheter, which was inserted coaxially within the guiding catheter. By pulling the microsnare catheter, we were able to pull the foreign body into the guiding catheter and successfully retrieved it. There were no complications, such as pulmonary artery injuries or thrombi. The recovered foreign body was a piece of a guidewire. The boomerang loop–snare technique using a small-diameter system is useful for the retrieval of a foreign body in infants.

© 2024 The Authors. Published by Elsevier Inc. on behalf of University of Washington. This is an open access article under the CC BY-NC-ND license (http://creativecommons.org/licenses/by-nc-nd/4.0/)

☆ Acknowledgments: None.

☆☆ Competing Interests: The authors declare that they have no known competing financial interests or personal relationships that could have appeared to influence the work reported in this paper.

* Corresponding author.
E-mail address: kamisako@wakayama-med.ac.jp (A. Kamisako).

https://doi.org/10.1016/j.radcr.2024.02.014

1930-0433/© 2024 The Authors. Published by Elsevier Inc. on behalf of University of Washington. This is an open access article under the CC BY-NC-ND license (http://creativecommons.org/licenses/by-nc-nd/4.0/)

Introduction

Intravascular remnants of foreign bodies, such as catheters and wires, are reported as complications in less than 1% of patients undergoing central venous catheter placement [1]. If left untreated, intravascular foreign bodies lead to arrhythmia or thrombosis in 60%-71% of cases [2] or death in 38% of cases [3]. Numerous reports have described percutaneous retrieval procedures in adults and children [4], with success rates of up to 94% [5]. These reports described the use of snare catheters alone or the conventional loop–snare technique. However, the latter requires the use of large-diameter systems exceeding 10 Fr, which are difficult to use in infants with small-diameter blood vessels. Therefore, we developed a new boomerang loop–snare technique with a small-diameter system. Using this technique, we successfully retrieved a foreign body located in the right pulmonary artery of an infant.

Case report

The patient was an 18-month-old girl with a height of 70 cm and a weight of 7.6 kg. She was being treated for myelodysplastic syndrome at another hospital. She also had Down syndrome without congenital heart disease. A central venous catheter was inserted via her right subclavian vein for chemotherapy. The procedure to puncture the subclavian vein was performed using an iron needle. A plain chest X-ray image obtained immediately after the procedure showed a linear foreign body located in the right middle and lower lung areas (Fig. 1). Contrast-enhanced computed tomography (CT) confirmed the presence of a curved, linear, high-density structure located in the right pulmonary artery (A8–A9) . The patient was therefore transferred to our hospital to retrieve the intravascular foreign body.

We decided to percutaneously retrieve the foreign body from the pulmonary artery in cooperation with pediatric cardiologists. Her vital signs during transportation were as follows: consciousness state (Glasgow coma scale) of E4V5M6, oxygen saturation 98% (without oxygen administration), heart rate 150 beats/minutes, breath sounds were clear, heart sounds indicated no murmur, and electrocardiogram indicated sinus rhythm without arrhythmia. Blood test showed a red blood cell count of 3.75 million cells/μL, hemoglobin level of 11.4 g/dL, platelet count of 253,000 cells/μL, and fibrin degradation product (FDP) level of <2.5 μg/dL. There were no signs of anemia, thrombocytopenia, or elevated FDP suggestive of thrombus formation. Chest radiography (Fig. 1) showed a folded linear foreign body in the right lung, and a contrast-enhanced CT showed a folded, high-density foreign body in the right pulmonary artery (A8–A9).

Percutaneous retrieval of the foreign body

The procedure was performed in a hybrid operating room under general anesthesia. A pediatrician punctured the right femoral vein under echo-guidance and inserted a 6 Fr sheath.

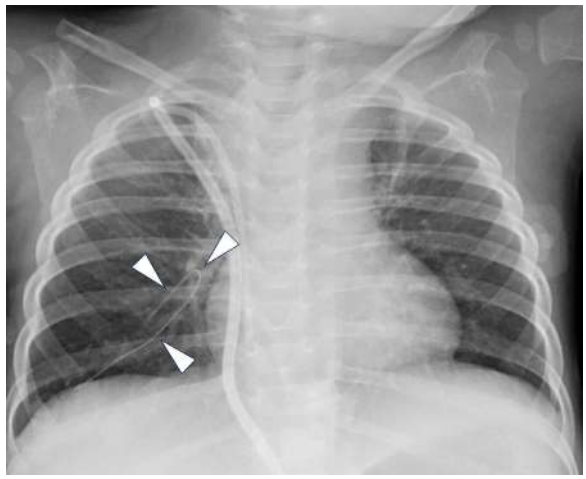

Fig. 1 – Chest radiography showing a folded linear foreign body in the right middle and lower lung areas (arrowheads).

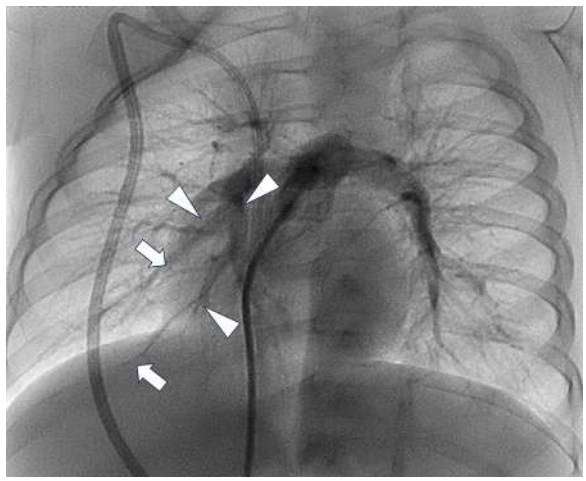

Fig. 2 – Pulmonary arteriography showing a foreign body (arrowheads) in the pulmonary artery (A8–A9). The free ends of the foreign body (arrows) are located in the peripheral regions of A8 and A9.

Pulmonary arteriography was performed using a catheter (Wedge pressure catheter; Harmac Medical Products, New York, USA). The free ends of the foreign body were located in the peripheral pulmonary artery on both sides, and the foreign body was bent over the bifurcation of the right pulmonary arteries at A8 and A9 (Fig. 2). Therefore, we decided to make a loop of the wire across its bent portion, and use the loop–snare technique to retrieve it. A 6 Fr guiding catheter (Mach1, ST 90cm; Boston Scientific, Marlborough, MA, USA) was inserted into the main trunk of the right pulmonary artery. A 4 Fr catheter with a bent tip (IMA Goodtec angiographic catheter; Nipro, Osaka, Japan) was advanced near the bent portion of the foreign body. A 2.4 Fr steerable microcatheter (Leonis Mova; SB Kawasumi, Kanagawa, Japan) was bent to its maximum acute angle, and a microguidewire (CHIKAI EXC 315cm; Asahi intecc, Aichi, Japan) was successfully crossed over the foreign

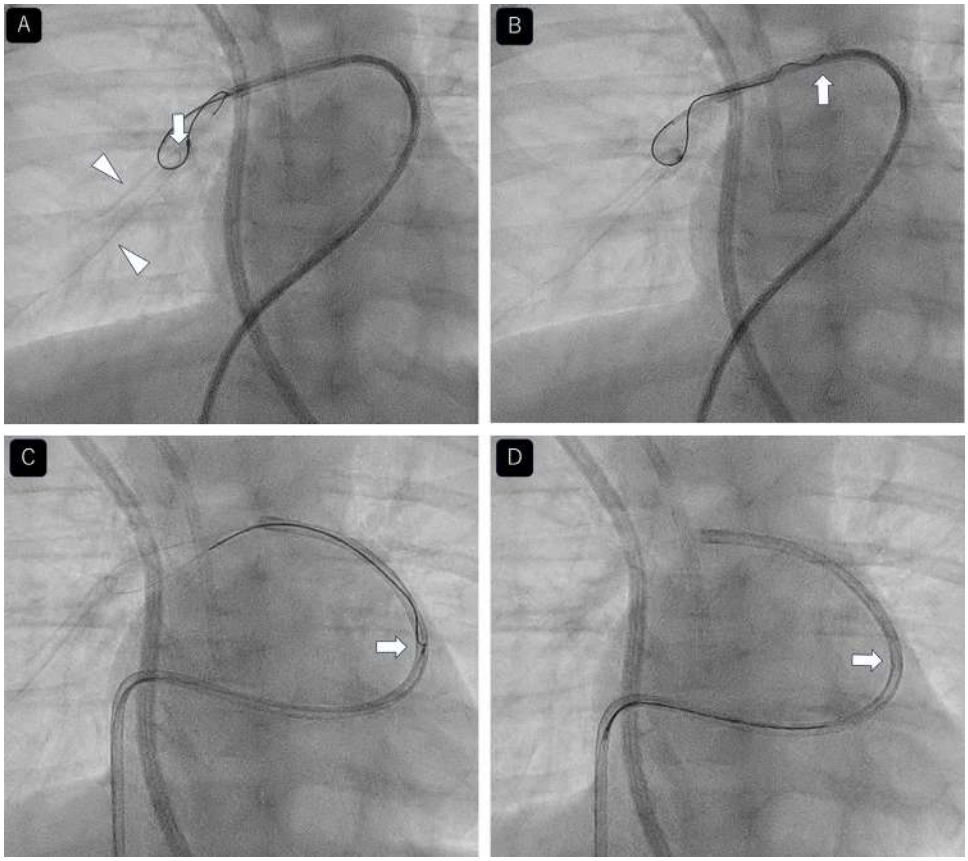

Fig. 3 – Overview of the boomerang loop–snare technique. (A) A loop of a microguidewire was created across the folded portion (arrow) of the foreign body (arrowheads) using a 6 Fr guiding catheter, a 4Fr IMA catheter, and a microcatheter with a steerable tip. (B) The U-turned microguidewire was advanced into the guiding catheter as far as possible (arrows). (C) The tip of the microguidewire was grasped using a microsnare catheter inserted through the guiding catheter (arrow). (D) The microsnare catheter and microguidewire were pulled back, and the foreign body was pulled into the guiding catheter (arrow).

body to create a loop (Fig. 3a). The U-turned microguidewire was reinserted into the 6 Fr guiding catheter and advanced as far as possible toward the operator side (Fig. 3b). After removing the microcatheter and the IMA catheter, a one-loop 3 Fr microsnare kit (AMPLATZ Goose neck Microsnare Kit, snare wire; 0.018inch; Medtronic, Minnesota, USA) was coaxially inserted. The pull-through method was achieved by grasping the free end of the microguidewire in the guiding catheter using the microsnare kit (Fig. 3c). The microguidewire was caught within the guiding catheter because it was unclear whether it could be caught by the snare within the pulmonary artery. By pulling the snare, we were able to pull the foreign body into the guiding catheter (Fig. 3d).

The retrieved foreign body was a piece of a guidewire (Fig. 4). The hydrophilic guidewire was manipulated via an iron needle at the previous hospital, and the tip of the guidewire may have been shaved off during manipulation. Postoperative pulmonary arteriography revealed no injuries or thrombi (Fig. 5). The patient had a good postoperative course. Three days after the procedure, she was transferred to the previous hospital without complications.

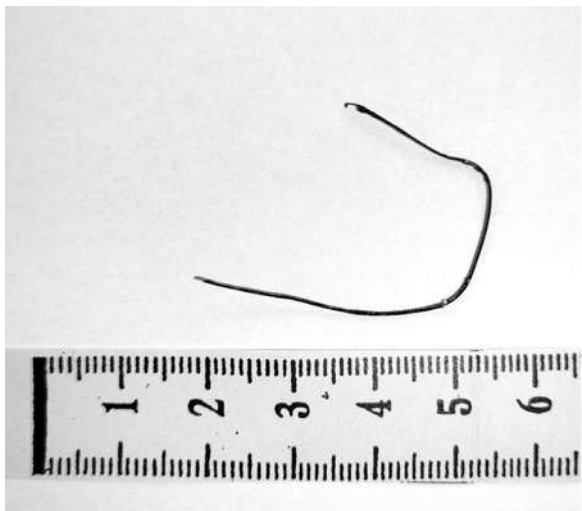

Fig. 4 – The retrieved foreign body was approximately 6 cm long.

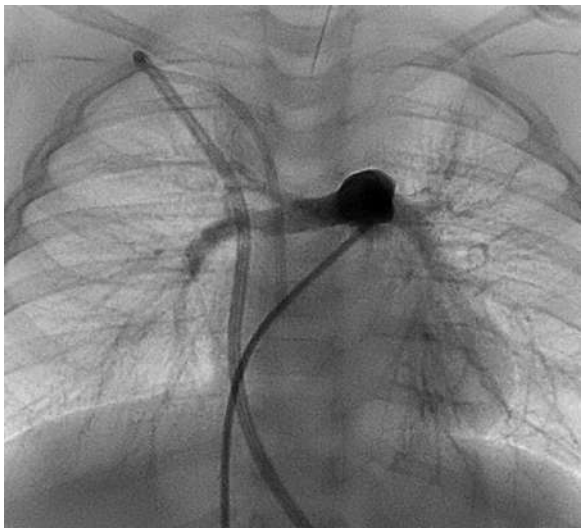

Fig. 5 – Postoperative pulmonary arteriography showing there were no pulmonary artery injuries or thrombi after the procedure.

Discussion

The conventional loop–snare technique is commonly used to retrieve inferior vena cava filters and detached central venous catheters, and is generally performed using large systems with a 10 Fr sheath or larger [6,7]. This is because 4 Fr or larger loop-type catheters and 6 Fr snare catheters are coaxially used to perform the procedure. In addition, because the retrieved objects, such as inferior vena cava filters, are usually large, a large sheath is necessary to house it during retrieval. Our case was an 18-month-old girl. The average diameter of the femoral vein in infants with a median age of 1.1 years was reported to be 3.6 mm (approximately 10 Fr) [8]. Owing to the patient's small blood vessels, it was considered too difficult to use the large conventional system and we needed to use a smaller system instead. Therefore, we used the boomerang loop–snare technique in this case. This technique involves the use of a steerable microcatheter to make a U-turn of the microguidewire in a small-diameter vessel. The U-turned micro guidewire was reinserted into the 6 Fr guiding catheter, and its end was grasped using a 3 Fr snare catheter inserted through the guiding catheter. Therefore, this technique requires a guiding catheter with a minimum size of 6 Fr to house a U-turned, 0.014 inch microguide wire (about 3 Fr) and a one-loop 3 Fr microsnare catheter.

We initially considered four other strategies. The first strategy involves grasping the free end of the foreign body using a thin snare catheter. However, this method was difficult because both free ends of the foreign body were located in the peripheral portions of the pulmonary artery. The second strategy involves the use of 2 catheters for retrieval [9]. In this method, a 3 Fr pigtail or hook-type catheter is used to hook the foreign body and move free end of the foreign body. Next, a 4 Fr snare catheter is used to grasp and retrieve the foreign body. However, this method requires 2 access sites and can cause unexpected migration of the foreign body. The third strategy involves the use of biopsy forceps to grasp the foreign body. However, this method was not considered because of the possible risk of vascular injury during the procedure. The final strategy involves the lateral grasp technique using a 7 Fr sheath [10], in which the wire end is grasped outside the guiding sheath using a snare catheter. We considered that it is easier to grasp the end of the microguidewire using a microsnare catheter within the thin guiding catheter than in the thick pulmonary artery.

There are 4 limitations of the boomerang loop–snare technique. First, the procedure is complicated because it requires extensive setup and the use of multiple devices. Second, several catheters and guidewires are required, resulting in high financial costs. Third, the foreign body must be thin and soft enough to fit inside the guiding catheter (in this case a 6 Fr catheter), and must be light enough to be towed by the microsystem. Finally, if the foreign body is linear and oriented parallel to the system, it cannot be hooked by the microguidewire.

Conclusion

Using our new boomerang loop–snare technique, we successfully retrieved a foreign body from an infant's right pulmonary artery. This new technique is effective if the foreign body located in a small vessel is flexible, thin, light, and in a folded state.

Patient consent

The parents of the patient provided informed consent for publication of this case report (November 20th, 2023).

AI declaration

The authors did not use any generative AI or AI-assisted technologies in the writing process.

REFERENCES

[1] Leite TFO, Pazinato LV, Bortolini E, Pereira OI, Nomura CH, da Motta Leal Filho JM. Endovascular removal of intravascular foreign bodies: a single-center experience and literature review. Ann Vasc Surg 2022;82:362–76. doi:10.1016/j.avsg.2021.12.003.

[2] Schechter MA, O'Brien PJ, Cox MW. Retrieval of iatrogenic intravascular foreign bodies. J Vasc Surg 2013;57(1):276–81. doi:10.1016/j.jvs.2012.09.002.

[3] Egglin TKP, Dickey KW, Rosenblatt M, Pollak JS. Retrieval of intravascular foreign bodies: experience in 32 cases. AJR Am J Roentgenol 1995;164(5):1259–64. doi:10.2214/ajr.164.5.7717243.

[4] Cahill AM, Ballah D, Hernandez P, Fontalvo L. Percutaneous retrieval of intravascular venous foreign bodies in children. Pediatr Radiol 2012;42(1):24–31. doi:10.1007/s00247-011-2150-z.
[5] Cheng CC, Tsai TN, Yang CC, Han CL. Percutaneous retrieval of dislodged totally implantable central venous access system in 92 cases: experience in a single hospital. Eur J Radiol 2009;69(2):346–50. doi:10.1016/j.ejrad.2007.09.034.
[6] Mori K, Somagawa C, Kagaya S, Sakai M, Homma S, Nakajima T. Pigtail through snare" technique: an easy and fast way to retrieve a catheter fragment with inaccessible ends. CVIR Endovasc 2021;4(1):24. doi:10.1186/s42155-021-00218-6.
[7] Su Q, Ding X, Dong Z, Liu Y, Li G, Jiang J. A modified loop snare technique for difficult retrievals of inferior vena cava filter and migrated coil. Int Heart J 2019;25(1):93–9 60. doi:10.1536/ihj.18-075.
[8] Good RJ, Levin M, Feder S, Loi MM, Kim JS, Branchford BR, et al. Accuracy of bedside ultrasound femoral vein diameter measurement by PICU providers. Pediatr Crit Care Med 2020;21(12):e1148–51. doi:10.1097/PCC.0000000000002439.
[9] Gabelmann A, Kramer S, Gorich J. Percutaneous retrieval of lost or misplaced intravascular objects. AJR Am J Roentgenol 2001;176(6):1509–13. doi:10.2214/ajr.176.6.1761509.
[10] Izumi Y, Ikeda S, Kitagawa A, Imaeda Y, Yamada T, Hagihara M, et al. Percutaneous retrieval of a misinserted pigtail catheter straightener during infra-renal abdominal aortic stenting: a case report. Interv Radiol (Higashimatsuyama) 2020;5(3):145–9. doi:10.22575/interventionalradiology.2020-0018.