Review Article

The Neuroradiology Journal
2026, Vol. 39(4) 428–437
© The Author(s) 2025
Article reuse guidelines:
sagepub.com/journals-permissions
DOI: 10.1177/19714009251393210
journals.sagepub.com/home/neu
Mary Ann Liebert
A Part of Sage

Systematic review of WEBectomy in intracranial aneurysms

João Paulo Liute Scarramal[1], Emmanuel Oberda Nominato[1], Leonardo Januário Campos Cardoso[2], Mariana Letícia de Bastos Maximiano[3], Leonardo BO Brenner[4], Luiz Felipe Simões Antunes Nery dos Santos[5], Vitoria Pinheiro[6], Felipe Dominici Castelo Branco[7], Raphael Bertani[8], Ahmet Günkan[9], Marcio Yuri Ferreira[10], David Gordon[10] and Christian Ferreira[10]

Abstract

Purpose: Endovascular removal of the Woven EndoBridge device (WEBectomy) is rarely reported but crucial for managing complications such as migration, compaction, and malposition, which may lead to recurrence and retreatment. This review aimed to assess treatment strategies, outcomes, and complications associated with WEBectomy.

Methods: We searched PubMed, Embase, and Web of Science databases from inception to January 14, 2025, following Preferred Reporting Items for Systematic Reviews and Meta-Analyses (PRISMA) guidelines for studies reporting on cases of WEBectomy.

Results: Eight studies with 16 patients (range age 30–89; 50% male) with 16 aneurysms were included. The basilar artery was the most common site in 25% (4/16) of the cases, and 50% (7/14) of the aneurysms were ruptured. Migration was the most frequent complication (11/16, 69%), followed by protrusion (4/16, 25%) and malposition (1/16, 6%) that required the removal of WEB. The Amplatz Goose Neck Microsnare was the most commonly used retrieval device (12/16, 75%), with no reported failures or major complications. Retreatment involved a new WEB in 50% (8/16) and coiling techniques in 31% (5/16). Among nine patients with follow-up imaging, most showed complete occlusion (67%, 6/9). Functional outcomes were favorable in 83% (4/6) (mRS 0–1).

Conclusion: Reported cases show that WEBectomy can be successfully performed in selected situations, allowing tailored retreatment planning. However, due to the small number of cases and limited follow-up, no definitive conclusions about safety or efficacy can be drawn. This review provides a concise synthesis of current management strategies for this rare complication.

Keywords

Woven EndoBridge, WEBectomy, endovascular, retreatment

Introduction

Endovascular treatment is considered by some specialists the first-line therapy for both ruptured and unruptured intracranial aneurysms due to advancements in devices and techniques in recent years.[1–3] The Woven EndoBridge (WEB) device, introduced in 2011, is an innovative intrasaccular flow-disruption device specifically designed for the treatment of wide-neck intracranial bifurcation aneurysms (WNBAs), which account for approximately one-third of all intracranial aneurysms.[3,4] Additionally, the WEB has also been used for the treatment of aneurysms beyond WNBAs.[5,6]

However, a subset of patients may experience aneurysm recurrence, requiring retreatment. Approximately 10% of WEB-treated WNBAs require additional intervention, highlighting the need for effective retreatment strategies[6]. Previous studies have identified potential causes of recurrence, including device migration, compaction, and malposition.[7,8] These events may result from incomplete detachment, incorrect device selection, or undersizing in large aneurysms.[7]

Management strategies for these complications include WEBectomy[9], repositioning of the WEB[10], microsurgical removal,[11] and conservative approaches.[12] WEBectomy has been described as the preferred approach in cases of WEB

[1]Department of Medical Sciences, Federal University of Ouro Preto, Ouro Preto, MG, Brazil
[2]Department of Medical Sciences, Federal University of Minas Gerais, Belo Horizonte, MG, Brazil
[3]Department of Medical Sciences, Federal Fluminense University, Niterói, RJ, Brazil
[4]Department of Medicine, State University of Ponta Grossa, Ponta Grossa, PR, Brazil
[5]University Institute of Health Sciences, Fundación H. A. Barceló, La Rioja, LR, Argentine
[6]Department of Medicine, Ninth of July University, São Paulo, SP, Brazil
[7]Department of Medicine, University Ceuma of Maranhão, São Luís, MA, Brazil
[8]Department of Neurosurgery, University of São Paulo, São Paulo, SP, Brazil
[9]Division of Vascular and Interventional Radiology, Department of Radiology and Imaging Sciences, University of Arizona, Tucson, AZ, USA
[10]Department of Neurosurgery, Northwell Health, New York, NY, USA

Corresponding author:
João Paulo Liute Scarramal, Department of Medical Sciences, Federal University of Ouro Preto, 74 Rua Helcio Fortes - Lagoa, Ouro Preto 35400347, Brazil.
Email: jpscarramal@gmail.com

migration, as it allows aneurysm retreatment either by re-implantation of a new WEB device or through the use of coils and stents. Although some reports suggest that WEBectomy may represent a feasible treatment option and emphasize the importance of neurointerventionists being aware of the available strategies for WEB-related complications, there is still no systematic synthesis of its technical challenges, periprocedural complications, or clinical outcomes.

Given these concerns, this systematic review aims to comprehensively assess the available literature on the endovascular removal of the WEB device, addressing existing gaps by analyzing treatment strategies, complications, and clinical outcomes.

Methods

This systematic review was conducted following the Preferred Reporting Items for Systematic Reviews and Meta-Analyses (PRISMA) guidelines.[13]

Eligibility criteria

Inclusion was restricted to studies reporting on cases of endovascular removal of the WEB device. Non-English papers, review articles, commentaries, conference abstracts, or editorials without original case descriptions were excluded from the initial review.

Search strategy and data extraction

A comprehensive literature search was performed in the PubMed, Embase, and Web of Science databases from inception to January 14, 2025, using the following search strategy: *(endobridge OR web) AND (aneurysm OR aneurism) AND (retrieval OR recover* OR removal OR extraction OR migrat* OR rescue OR redirection OR revascularization OR dislodg*)*. Additionally, manual screening of the reference lists of relevant articles was conducted to identify supplementary studies meeting the inclusion criteria. Two independent reviewers assessed the studies for data extraction, with any discrepancies resolved through consultation with the senior author. Extracted data included study design, country, patient age and sex, imaging modality used, aneurysm characteristics (rupture status, location, and dimensions), previous treatment, and details of the initial WEB procedure (device size, access route, and antiplatelet use).

Outcomes and definitions

Outcomes included (1) management strategies for WEB removal, (2) retreatment of the aneurysm, and (3) clinical and radiological follow-up, including aneurysm occlusion rates, procedure-related complications, and the progression of neurological symptoms.

Quality assessment

Most articles included in our analysis were case series or case reports; therefore, manuscripts were critically assessed according to the tool proposed by Murad et al. for this type of studies.[14] According to this tool, each manuscript is assessed in 4 domains: selection of study sample, ascertainment, causality of the outcome observed, and reporting of cases. Questions were adapted to our population and manuscripts were assessed by two authors. Based on this assessment, the risk of bias was considered based on the amount of negative questions. Studies with at least three negative questions were considered high risk of bias, two negative questions were considered as medium risk, whereas one negative or none was considered low risk.

Results

Study selection

A total of 683 articles were identified across PubMed (253), Embase (328), and Web of Science (102) databases. After excluding 320 duplicates, 363 studies remained for the title and abstract screening. Of these, 25 articles were selected for full-text review. Ultimately, 8 studies were included in the systematic review.[9,12,14–19] Figure 1 illustrates the study selection process.

Baseline characteristics

A total of 16 patients with 16 aneurysms were included, along with eight articles, comprising seven case reports and one retrospective study. The range age was 30 to 87, with 7/14 (50%) being male. Patients originated from various countries, with the United Kingdom and the United States being the most represented. The basilar artery was the most common aneurysm location (4/16, 25%). Seven patients presented with ruptured aneurysms, including one classified as Grade 5 on the World Federation of Neurological Surgeons (WFNS) scale and three reported as Grade 4–5 subarachnoid hemorrhages, although the grading scale was not specified. Aneurysm height was available for 14/16 patients, ranging from 3 mm to 8 mm. Dome size was reported for 13/16 patients, ranging from 2 mm to 9.1 mm, and neck size was available for 5/16 patients, ranging from 3.4 mm to 4.9 mm. Maximum size was available for 4/16 patients, ranging from 3.1 mm to 6.1 mm. Detailed study, patient, and aneurysm characteristics are summarized in Table 1.

Study design, country, age, sex, imaging modality usada, aneurysm characteristic for status ruptured and size, previous treatment, Web size and via, access route and antiplatelet use.

Initial WEB treatment and complications

In the initial treatment with the WEB device, the Single-Layer (SL) model was the most used (14/16, 87%). Types of microcatheters used were 0.017 inches (11/15, 73%) and 0.021 inches (4/15, 27%), and the most frequently employed vascular access was transfemoral (8/14, 57%). Antiplatelet therapy was reported in five patients across three studies, with dual antiplatelet therapy (DAPT) before the procedure (aspirin and clopidogrel) (3/5, 60%), clopidogrel alone before the procedure (1/5, 20%), and DAPT post-procedure (1/5, 20%).[14,18,19] Chew et al. reported pre-WEB embolization using balloon-assisted coiling.[12] Additional details regarding initial WEB treatment are provided in Table 1.

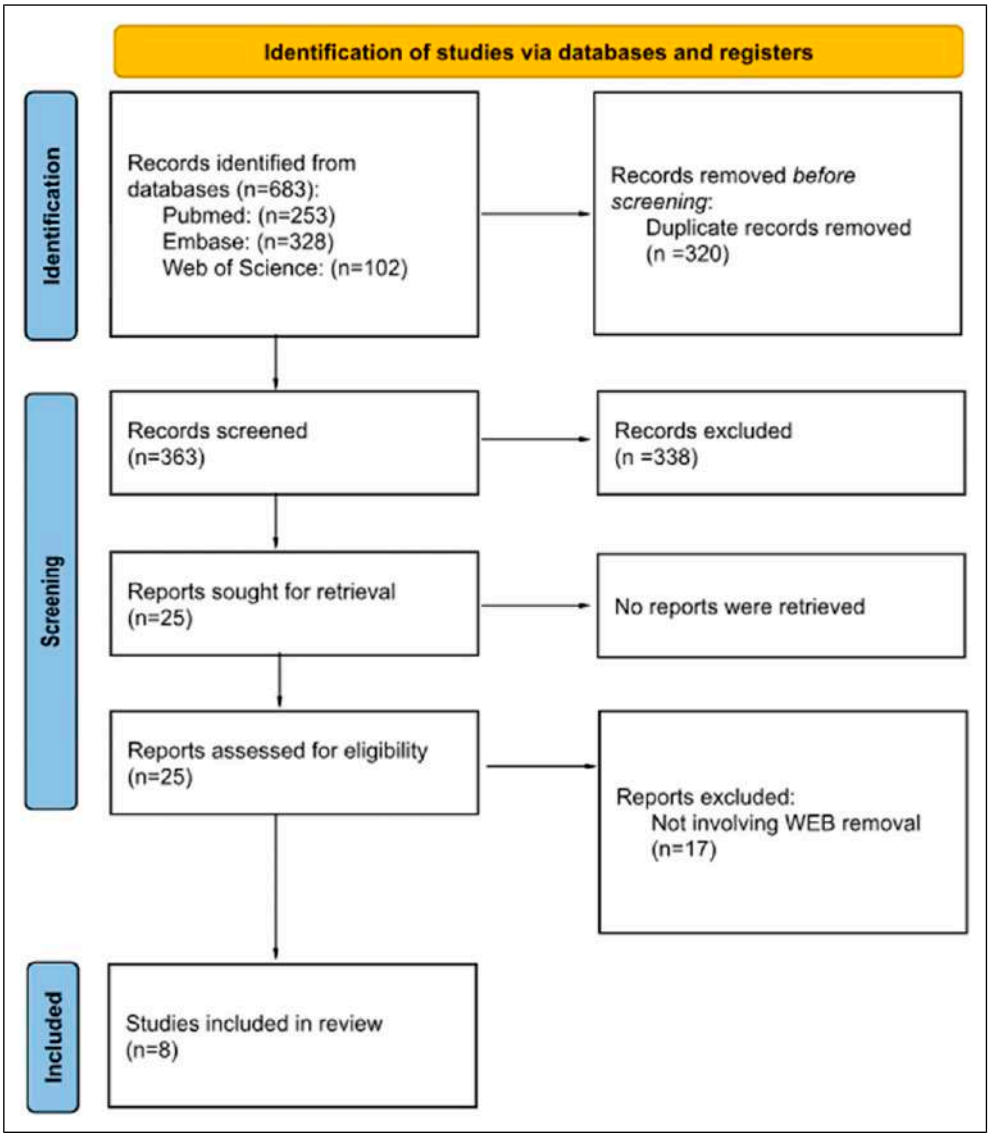

Figure 1. PRISMA Flow Diagram depicting the selection process.

Complications occurred intraoperatively in all cases, including migration (11/16, 69%), protrusion (4/16, 25%), and malposition (1/16, 6%). Among migration cases, the most frequent destinations were the basilar artery (3/11, 27%) and middle cerebral artery (3/11, 27%). In one patient, migration was detected 15 hours after WEB implantation, presenting with lower limb weakness. Detailed information on complications and WEBectomy is available in Table 2.

WEBectomy and retreatment

The Amplatz Goose Neck Microsnare (AGM) was the most common (12/16, 75%) retrieval device used, with the 4 mm variant employed in 9/12 cases (75%) and the 2 mm variant in 3/12 (25%). The Solitaire Platinum stent 4 × 20 mm was used in two patients (2/16, 12%), the Solitaire stent 4 × 40 mm in one patient (1/16, 6%), and the Alligator in one patient (1/16, 6%). Various adjunctive devices were used during WEB retrieval, with the Headway 21 microcatheter being employed most frequently (5/16, 31%). Intermediate catheters were utilized in 37% of cases (6/16), with the 6F Sophia and Vecta 46 being the most used, each applied to two patients.

Successful WEB removal was achieved on the first attempt in most cases, with only two patients (12%) requiring multiple retrieval attempts. In one case, both the Embotrap (5 × 3 mm) and the Solitaire (4 × 20 mm) stent failed before successful retrieval. Another patient initially attempted retrieval with an LVIS Jr retriever (2.5 mm) without success.

Retreatment involved a second WEB device in eight patients (50%), most commonly the Single-Layer model (5/8, 62%). Coil embolization was performed in five patients (31%), with two cases requiring balloon remodeling. Stent-assisted techniques were used in two patients (12%), one for coiling and one for WEB implantation. Additionally, one patient (6%) underwent balloon-assisted coiling. One procedure-related complication occurred during the retreatment phase, involving aneurysm rupture due to microcatheter injury. Detailed information on complications and WEBectomy is available in Table 2.

Clinical and radiological follow-up

Follow-up imaging was available for nine patients and ranged from 1 to 3 years. Complete occlusion was achieved

Table 1. Baseline characteristics and Initial WEB treatment.

Study characteristics				Aneurysm characteristics						Initial WEB treatment				
Study	Design (country)	Age/Sex	Imaging modality	Location (details)	Status	Dome size (mm)	Neck size (mm)	Height (mm)	Max size (mm)	Previous treatment	WEB size (mm)	WEB via	Access route	Antiplatelet use (timepoint)
Abdelrady 2021[14]	CR (Egypt)	71/F	3D, DSA	BA (distal)	UR	5	NA	3.6	NA	None	SL (5-4 × 3)	17	Transfemoral	Clopidogrel 75 mg (before WEB implantation)
Bañez 2022[15]	CR (Australia)	50/F	3D, MRA	BA (tip)	R (WFNS 5)	5	NA	3	NA	None	SL (5 × 2)	17	NA	NA
Chew 2024[9] (case 1)	CS (UK)	30–39/M	3D, CTA, DSA, MRA	ACOM	R (1 SAH)	3.5	NA	3.1	NA	NA	SL (4.5 × 2)	17	Transfemoral	NA
(Case 2)	CS (UK)	50–59/M	3D, DSA, MRA	PCOMA	R (4 SAH)	2	NA	3.1	NA	BAC	SL (3 × 2)	17	Transfemoral	NA
(Case 3)	CS (UK)	40–49/M	3D, DSA, MRA	ACOM	R (4 SAH)	4.8	NA	3.1	NA	NA	SL (5 × 3)	17	Transradial	NA
(Case 4)	CS (UK)	30–39/F	3D, DSA, MRA	PCA	R (5 SAH)	NA	NA	NA	NA	NA	SL (5 × 2)	17	Transfemoral	NA
(Case 5)	CS (UK)	40–49/M	3D, DSA, MRA	PCOMA	UR	9.1	NA	8	NA	NA	SLS (NA)	NA	Transfemoral	NA
(Case 6)	CS (UK)	50–59/F	3D, DSA, MRA	MCA	R (2 SAH)	NA	NA	NA	NA	NA	SL (4 × 3)	17	Transradial	NA
Gravino 2022[12]	CR (UK)	52/M	3D, CTA, DSA	ICA (distal)	R (WFNS 1)	NA	NA	6	NA	None	SL (6 × 4)	17	NA	NA
König 2019[16]	CR (Germany)	64/F	3D, DSA, MRA	ICA (bifurcation)	UR	2.9	NA	3.2	3.1	None	SLS	17	Cervical ICA	NA
Radu 2022[17]	CR (France)	52/M	3D, DSA	BA (top)	UR	3	NA	3	NA	None	SL (3 × 2)	17	Transradial	NA
Santhumayor 2023 (case 1)[18]	CR (USA)	70/NA	DSA, MRA	BA (tip)	UR	4.7	4.4	3.7	NA	None	SL (5 × 2)	17	Radial	NA
(Case 2)	CR (USA)	60/NA	DSA, MRA	ACOM	UR	5.1	4.8	4.6	NA	None	SL (4 × 3)	21	Transfemoral	DAPT (before WEB removal)
Suzuki 2024[19] (case 1)	CR (China)	58/M	DSA	MCA	UR	4.3	3.4	4.5	6.1	NA	SL (5 × 4)	21	Radial	Aspirin 100 mg, clopidogrel 75 mg (before WEB implantation)

(continued)

Table 1. (continued)

Study characteristics				Aneurysm characteristics						Initial WEB treatment				
Study	Design (country)	Age/Sex	Imaging modality	Location (details)	Status	Dome size (mm)	Neck size (mm)	Height (mm)	Max size (mm)	Previous treatment	WEB size (mm)	WEB via	Access route	Antiplatelet use (timepoint)
(Case 2)	CR (China)	51/F	DSA	MCA	UR	4.1	4.2	3.3	4.2	NA	SL (5 × 3)	21	Transfemoral	Aspirin 100 mg, clopidogrel 75 mg (before WEB implantation)
(Case 3)	CR (China)	87/F	DSA	PCOMA	UR	5	4.9	4.4	6	NA	SL (5 × 3)	21	Transfemoral	Aspirin 200 mg, clopidogrel 300 mg (before WEB implantation)

ACOM: Anterior Communicating Artery; APT: Antiplatelet Therapy; BA: Basilar Artery; BAC: Balloon-Assisted Coil; CR: Case Report; CS: Case series; CT: Computed Tomography; DCT: Dyna-CT; DSA: Digital Subtraction Angiography; F: Female; ICA: Internal Carotid Artery; M: Male; MCA: Middle Cerebral Artery; MRA: Magnetic Resonance Angiography; NA: Not Available; PCA: Posterior Cerebral Artery; PCOMA: Posterior Communicating Artery; R: Ruptured; SAH: Subarachnoid Hemorrhage; SAPT: Single Antiplatelet Therapy; SL: Single-Layer; SLS: Single-Layer Sphere; UR: Unruptured.

Table 2. Complications, WEBectomy, retreatment, and outcome.

	Complication of WEB			WEBectomy and Retreatment					Clinical and Radiological Follow-up	
Study	Lesion	Location	Time (details)	Retrieval device successful (mm)	Supporting Devices	Failed Attempts (mm)	Retreatment (mm)	Procedure Complications	Occlusion status (FU)	Final outcome
Abdelrady 2021[14]	M	PCA	IOP	Solitaire platinum (4)	Headway 21 microcatheter, 6F sophia intermediate catheter	None	WEB SL (5-4 × 2)	None	NA	Uneventful post-procedural recovery
Bañez 2022[15]	M	BA	IOP	Solitaire platinum (4 × 20)	Headway 21 microcatheter, 6F sophia intermediate catheter	None	WEB SL (4.5 × 2)	NA	Complete occlusion (3y)	NA
Chew 2024[9] (case 1)	M	iPCA	IOP	AGM (4)	Headway 27 microcatheter	None	Coils	None	Residual neck (2y)	mRS 1
(Case 2)	M	MCA (bifurcation)	IOP	AGM (4)	Prowler select plus microcatheter	None	Coils	None	Complete occlusion (2y)	mRS 0
(Case 3)	PR	NA	IOP	AGM (2)	Proximal marker microcatheter	None	WEB SL (6 × 3)	None	Complete occlusion (2y)	mRS 0
(Case 4)	MA	NA	IOP	AGM (2)	Headway 21 microcatheter	None	WEB SL (4 × 2)	None	Complete occlusion (2y)	mRS 0
(Case 5)	PR	NA	IOP	AGM (4)	Prowler select plus microcatheter	None	WEB SLS (8)	None	Complete occlusion (2y)	mRS 0
(Case 6)	PR	NA	IOP	AGM (2)	Headway 21 microcatheter	None	Coils	Aneurysm rupture is secondary to microcatheter injury	Complete occlusion (2y)	mRS 4
Gravino 2022[12]	M	ICA	IOP	Solitaire platinum (4 × 40)	Echelon microcatheter, 8Fr Flowgate-2	None	Coils BRT	None	NA	No neurological deficits
König 2019[16]	M	MCA	IOP	Alligator (NA)	Rapid transit microcatheter	None	Coils BRT	NA	NA	NA

(continued)

Table 2. (continued)

	Complication of WEB			WEBectomy and Retreatment					Clinical and Radiological Follow-up	
Study	Lesion	Location	Time (details)	Retrieval device successful (mm)	Supporting Devices	Failed Attempts (mm)	Retreatment (mm)	Procedure Complications	Occlusion status (FU)	Final outcome
Radu 2022[17]	M	BA	IOP	AGM (4)	Headway 21 microcatheter, 5-Fr sophia intermediate catheter	1. Embotrap stent (5 × 3) 2. Solitaire stent (4 × 20)	WEB device (3 × 2)	NA	NA	No neurological deficit
Santhumayor 2023[18] (case 1)	M	BA	IOP	AGM (4)	NA	None	Stent-assisted coil	None	Residual neck (1y)	Recovered well, discharged next day
(Case 2)	M	ACA	IOP	AGM (4)	Headway 21 microcatheter	LVIS jr retriever (2.5)	Stent-assisted WEB	None	Near-complete occlusion (1y)	NA
Suzuki 2024[19] (case 1)	M	MCA	IOP	AGM (4)	Vecta46 intermediate catheter	None	WEB device	None	NA	Uneventful post-procedural recovery
(Case 2)	PR	NA	IOP	AGM (4)	5F sophia intermediate catheter	None	WEB SL (4 × 3)	None	NA	No neurological deficits
(Case 3)	M	PCOMA	IOP	AGM (4)	Vecta46 intermediate catheter	None	Balloon-assisted coil	None	NA	No neurological deficits

ACA: Anterior Cerebral Artery; ACOM: Anterior Communicating Artery; AGM: Amplatz Goose Neck Microsnare; BA: Basilar Artery; DAPT: Dual Antiplatelet Therapy; GNS: Goose Neck Snare; ICA: Internal Carotid Artery; iPCA: Ipsilateral Pericallosal Artery; IOP: Intraoperative; M: Migration; MA: Malposition; MCA: Middle Cerebral Artery; mRS: Modified Rankin Scale; NA: Not Available; PCA: Posterior Cerebral Artery; PCOMA: Posterior Communicating Artery; PrOp: Pre-Operative; PstOp: Postoperative; RT: Rescue Technique; SBC: Scepter Balloon Catheter; SC: Sofia Catheter; SL: Single-Layer; SLS: Single-Layer Sphere; SSR: Solitaire Stent Retriever; y: Year.

Table 3. Risk of Bias assessment of included studies.

Study	Selection	Ascertainment		Causality	Reporting	
	Does the patient(s) represent(s) the whole experience of the investigator in the study?	Was the intervention adequately ascertained?	Was the outcome adequately ascertained?	Was the follow-up long enough for outcomes to occur?	Is the case(s) described with sufficient detail to allow replication or to inferences?	Overall risk of bias
Abdelrady, 2021[14]	No	Yes	Yes	Yes	Yes	Low
Bañez, 2022[15]	No	Yes	Yes	Yes	Yes	Low
Chew, 2024[9]	Yes	Yes	Yes	Yes	Yes	Low
Gravino, 2022[12]	Yes	Yes	Yes	Yes	Yes	Low
König, 2019[16]	No	Yes	Yes	Yes	Yes	Low
Radu, 2022[17]	No	Yes	Yes	Yes	Yes	Low
Santhumayor, 2023[18]	No	Yes	Yes	Yes	Yes	Low
Suzuki, 2024[19]	Yes	Yes	Yes	Yes	Yes	Low

in six cases (67%, 6/9) residual occlusion in two patients (22%), and near-complete occlusion in one patient (11%).

In the post-procedural outcomes, 4/7 patients (57%) had no neurological deficits, 2/7 patients (29%) had uneventful recoveries, and 1/7 (14%) recovered well and was discharged the next day. Functional outcomes showed mRS 0 in 4/6 patients (66%), mRS 1 in 1/6 patient (16%), and mRS 4 in patients with aneurysm rupture. Outcome details can be found in Table 2.

Quality assessment

All studies included in our analysis were classified as having a low risk of bias according to the adapted Murad et al. tool. Across all evaluated domains—selection, ascertainment, causality, and reporting—most studies received positive ("Yes") responses for all items. Only two studies had one negative response each in the selection domain 16,20. A detailed risk of bias assessment for each study is presented in Table 3.

Discussion

This systematic review evaluated the evidence on endovascular removal of the WEB device in intracranial aneurysms. A total of 16 patients were identified across eight published studies, with AGM used as the retrieval device in 75% of the cases, and no complications related to the retrieval procedures were reported. Reimplantation of a new WEB device emerged as the most adopted retreatment strategy, with follow-up imaging available for nine patients and residual neck observed in only one case. Given the increasing adoption of the WEB device, our review identified capture techniques that can guide future retrieval protocols.

The underlying mechanisms of WEB instability appear to be multifactorial, frequently involving device undersizing, incomplete expansion, or microcatheter instability during deployment.[12] In addition, anatomical factors such as vascular tortuosity and arterial bifurcations may also increase the risk of displacement.[21,22] In our review, all complications occurred intraoperatively. However, the literature reports a case of delayed migration, occurring 12 days after implantation, which was managed by repositioning the device within the aneurysm.[20]

Endovascular removal of the WEB device allows for the implementation of alternative treatment strategies in cases where complications arise intra- or post-procedurally.[9] If the device has migrated remotely, retrieval using an Alligator Retrieval Device (ARD) or a Solitaire stent may be attempted.[12] Stent retrievers or revascularization devices, such as the Solitaire Platinum, have demonstrated efficacy in the retrieval of migrated endovascular coils.[12] However, for larger WEB devices, these may be less suitable due to the device's porosity. In such cases, the use of microsnares and ARD is preferred.[12] Alligator retrieval devices were designed to retrieve coils placed in smaller aneurysms using jaws and a grasper feature that is no longer available to practitioners in the US.[18]

In our review, the microsnare was the most commonly employed retrieval device, with loop sizes ranging from 2 to 4 mm. Currently available microsnares offer loop diameters between 2 mm and 7 mm and are typically configured with a snare length of either 175 or 200 cm.[18] Mechanically, the device is particularly advantageous due to its 90-degree loop configuration and super-elastic construction, which together minimize shape deformation and ensure coaxial alignment with the vessel lumen, enhancing its ability to engage the WEB device within a dynamic intraluminal environment.[15] Nonetheless, its use may be limited in very small-caliber vessels, where complete loop expansion can be challenging.[18]

Selecting the appropriate retrieval device is essential to avoid failed attempts, as these have been associated with increased risk of complications.[9] In two cases, stent retriever–based removal attempts were unsuccessful, requiring conversion to micro snare retrieval, which subsequently led to successful device removal. Radu et al. reported unsuccessful attempts using two different stent retrievers and a 5Fr distal access catheter,[17] while Santhumayor described failure with an LVIS Jr retriever.[18]

Following successful WEB retrieval, the choice of retreatment must consider the challenges encountered in the initial intervention.[19] Reimplantation of a new, appropriately sized WEB was the preferred strategy in most cases. Post-

treatment complications were rare, although one case of aneurysm rupture was reported during microcatheter manipulation in the retreatment phase.[9] When available, follow-up imaging revealed favorable outcomes, with complete or near-complete aneurysm occlusion in the majority of patients and no reported delayed neurological deficits. These findings suggest that, despite the complexity of retrieval and retreatment procedures, long-term efficacy and safety can still be achieved with appropriate technique and case selection.

As an alternative to endovascular removal, options such as WEB repositioning,[10,23] microsurgical removal,[11] or conservative approaches[12] have been described. Repositioning can be performed to stabilize inadequately positioned devices or those projecting into the parent vessel and, in contrast to WEBectomy, it is a technically simpler procedure that does not require immediate retreatment.[23] In our review, eleven cases corresponded to device migration and five to protrusion or malposition. However, even in cases of malposition, repositioning presents potential drawbacks, such as the risk of rebleeding in acute subarachnoid hemorrhage, the need for antiplatelet therapy, and the possibility of aneurysm rupture during manipulation.[9,23] Technically, repositioning is less demanding and can be performed more rapidly, whereas removal provides broader retreatment options and greater flexibility in the subsequent therapeutic approach. Nonetheless, direct comparative data between repositioning and removal are still lacking.

This is the first study to systematically synthesize case reports on the endovascular removal of the WEB device. Our review describes the techniques used and clinical outcomes associated with device retrieval in technically complicated scenarios, such as migration, protrusion, and malpositioning, suggesting that removal is a feasible, safe, and effective strategy. This technique is an important addition to the neurointerventionist's toolkit, as it enables new embolization strategies. Although safety and efficacy appear promising, prospective studies with larger samples are needed to support solid conclusions. Nonetheless, WEBectomy emerges as a promising option within the neurointerventionist's armamentarium.

Limitations

The findings of this study must be interpreted considering its limitations. First, the most included studies are case reports, which may introduce inherent biases. Furthermore, the studies were conducted in different countries, each with its own documentation protocols, treatment standards, and neurointerventional expertise. Another relevant limitation is the risk of publication bias—the tendency for studies with positive results to be more likely published than those with negative or inconclusive findings. We recognize the need for prospective studies with larger samples to externally validate the results, ensuring greater reproducibility and clinical utility.

Conclusion

This review systematized the available evidence on endovascular removal of the WEB device in the context of migration, protrusion, and malposition. Reported experiences indicate that WEB device removal can be successfully performed in selected situations and it enabled broader retreatment options by allowing greater flexibility in the subsequent therapeutic approach. However, the current evidence is limited by the small number of cases, retrospective nature, lack of standardized reporting, and a likely publication bias favoring successful cases. Therefore, apparent feasibility and safety should be interpreted with caution until confirmed by larger, systematically reported series. Still, this study provides the first structured synthesis of WEB removal strategies and highlights its relevance as a salvage option in selected device-related complications.

Author contributions

J.P.L.S.: conceptualization, leading and supervising every step of the study, methodology, data analysis and initial draft writing. E.O.*N*.: initial draft writing, prepared Table, data analysis, data extraction and preparation of files for submission. L.J.C.C.: data extraction and data analysis. M.L.B.M.: initial draft writing and investigation. L.O.B.: investigation and methodology. V.P, L.F.S.A.*N*.S.: study selection and investigation. F.D.C.B.: initial draft writing and investigation. R.B. A.G., M.Y.F., D.G.: manuscript analysis, critical review and editing. C.F.: supervision, project administration, critically revising the draft, and carrying out the final revision.
All authors contributed to data interpretation and reviewed and approved the final manuscript. MYF assumes full responsibility for the study, including its design, data access, and the decision to submit and publish. All authors could access the data and acknowledge their responsibility for submitting the manuscript.

Declaration of conflicting interests

The authors declared no potential conflicts of interest with respect to the research, authorship, and/or publication of this article.

Funding

The authors received no financial support for the research, authorship, and/or publication of this article.

ORCID iDs

João Paulo Liute Scarramal https://orcid.org/0009-0001-3149-1370
Leonardo Januário Campos Cardoso https://orcid.org/0000-0001-9130-3143
Leonardo BO Brenner https://orcid.org/0009-0009-5612-556X
Ahmet Günkan https://orcid.org/0000-0002-6236-5633

References

1. Pierot L and Wakhloo AK. Endovascular treatment of intracranial aneurysms: current status. *Stroke* 2013; 44: 2046–2054. https://doi.org/10.1161/STROKEAHA.113.000733
2. Lv X, Zhang Y and Jiang W. Systematic review of woven EndoBridge for wide-necked bifurcation aneurysms: complications, adequate occlusion rate, morbidity, and mortality. *World Neurosurg* 2018; 110: 20–25. https://doi.org/10.1016/j.wneu.2017.10.113
3. Mine B, Pierot L and Lubicz B. Intrasaccular flow-diversion for treatment of intracranial aneurysms: the woven EndoBridge. *Expet Rev Med Dev* 2014. https://doi.org/10.1016/j.wneu.2017.10.113

4. Pierot L, Klisch J, Liebig T, et al. WEB-DL endovascular treatment of wide-neck bifurcation aneurysms: long-term results in a European series. *AJNR Am J Neuroradiol* 2015; 36: 2314–2319. https://doi.org/10.3174/ajnr.A4445
5. Pierot L, Biondi A, Narata A-P, et al. Should indications for WEB aneurysm treatment be enlarged? Report of a series of 20 patients with aneurysms in "atypical" locations for WEB treatment. *J Neuroradiol* 2017. https://doi.org/10.1016/j.neurad.2016.12.01
6. Kobeissi H, Ghozy S, Pakkam M, et al. Aneurysmal recurrence and retreatment modalities after woven EndoBridge (WEB) device implantation: a systematic review and meta-analysis. *Intervent Neuroradiol* 2023: 15910199231206082. https://doi.org/10.1177/15910199231206082
7. Goyal N, Hoit D, DiNitto J, et al. How to WEB: a practical review of methodology for the use of the Woven EndoBridge. *J Neurointerventional Surg* 2020; 12: 512–520. https://doi.org/10.1136/neurintsurg-2019-015506
8. Armoiry X, Turjman F, Hartmann D, et al. Endovascular treatment of intracranial aneurysms with the WEB device: a systematic review of clinical outcomes. *AJNR Am J Neuroradiol* 2015; 37: 868–872. https://doi.org/10.3174/ajnr.A4611
9. Chew HS, Altibi M, Al-Ali S, et al. Microsnare retrieval as a bail-out technique of Detached woven EndoBridge device: illustrative series. *Intervent Neuroradiol* 2024: 15910199241242170. https://doi.org/10.1177/15910199241242170
10. Cagnazzo F, Ahmed R, Dargazanli C, et al. Treatment of wide-neck intracranial aneurysms with the woven EndoBridge device associated with stenting: a single-center experience. *AJNR Am J Neuroradiol* 2019; 40: 820–826. https://doi.org/10.3174/ajnr.a6032
11. Shurkhay V, King BL, Acuff NJ, et al. Microsurgical removal of migrated woven EndoBridge device. *World Neurosurg* 2024; 183: 1. https://doi.org/10.1016/j.wneu.2023.11.155
12. Gravino G, Masri S, Chandran A, et al. *Management of WEB device migration and mal-position in endovascular treatment of cerebral aneurysms*. Interventional Neuroradiology, 2022. https://doi.org/10.1177/15910199221122857
13. Page MJ, McKenzie JE, Bossuyt PM, et al. The PRISMA 2020 statement: an updated guideline for reporting systematic reviews. *Br Med J* 2021; 372: n71. https://doi.org/10.1136/bmj.n71
14. Abdelrady M, Dargazanli C, Imad D, et al. Successful WEBectomy during embolization of temporal arteriovenous malformation-associated flow-related basilar aneurysms. *Intervent Neuroradiol* 2021. https://doi.org/10.1177/15910199211057693
15. Bañez RMF and Chong W. Retrieval of displaced woven EndoBridge intrasaccular flow disruptor using solitaire platinum revascularization device. *Neurointervention* 2022; 17: 106–109. https://doi.org/10.5469/neuroint.2022.00059
16. König I, Weber A, Weber W, et al. Dislocation of a WEB Device intd the Middle Cermbral Artcry: Remaval witr the Alligator Retaieval Devrce. *Clin Neuroradiol* 2018; 29: 361–364. https://doi.org/10.1007/s00062-018-0685-1
17. Radu RA, Gascou G, Derraz I, et al. Micro-snare retrieval as bail-out technique for a distally migrated WEB-device: A case report. *Intervent Neuroradiol* 2022; 30: 592–596. https://doi.org/10.1177/15910199221118709
18. Santhumayor BA, White TG, Werner C, et al. Woven EndoBridge Device Migration and Microsnare Retrieval Strategy: Single Institutional Case Reports with Technical Video Demonstration. *Neurointervention* 2023; 18: 129–134. https://doi.org/10.5469/neuroint.2023.00136
19. Suzuki T, Nakahara I, Matsumoto S, et al. Bailout Technique for Protrusion and Migration of Detached Woven EndoBridge Devices with Amplatz Goose Neck Microsnare. *J Neuroendovasc Ther* 2025; 19: 2024-0063. https://doi.org/10.5797/jnet.tn.2024-0063
20. Kanazawa R, Uchida T, Tetsuhiro H, et al. A Woven EndoBridge dislodging from an aneurysm 12 days after the implantation procedure: illustrative case. *J Neurosurg Case Lessons* 2024. https://doi.org/10.3171/CASE24278
21. Caroff J, Mihalea C, Neki H, et al. Role of C-Arm VasoCT in the Use of Endovascular WEB Flow Disruption in Intracranial Aneurysm Treatment. *AJNR Am J Neuroradiol* 2014; 35: 1353–1357. https://doi.org/10.3174/ajnr.a3860
22. van Rooij S, van Rooij W, Sluzewski M, et al. The Woven EndoBridge (WEB) for recurrent aneurysms: Clinical and imaging results. *Intervent Neuroradiol* 2018; 25: 21–26. https://doi.org/10.1177/1591019918798806
23. John S, Navarro R, Hussain SI, et al. Rescue Maneuver for Dislocated Woven EndoBridge Device in Middle Cerebral Artery. *World Neurosurg* 2019; 130: 467–469. https://doi.org/10.1016/j.wneu.2019.06.160